

# Traumatic aortic injury: a case report

## Travmatik aortik yaralanma: Olgu sunumu

Asif Huda ANSARI, Ahmed S. AHMED, Navin P. LAL

Trauma is the leading cause of death under the age of 35 years worldwide. Traumatic aortic rupture is responsible for 18% of all road accident mortality. Eighty percent of these patients die at the scene of the accident. Of the survivors, 50% die within 24 hours if left untreated. Rapid transport and resuscitation, awareness of the injury, availability of multi-slice computed tomography (MSCT), and timely intervention can significantly improve survival in aortic injury.

**Key Words:** Endoluminal stenting; traumatic aortic injury.

Travma, dünya genelinde 35 yaş altındaki ölümlerin en büyük nedenidir. Travmatik aortik yırtık, bütün karayolu kaza mortalitesinin %18'inden sorumludur. Bu hastaların %80'i, kaza bölgesinde ölür. Sağkalanların %50'si, tedavi edilmeden bırakılmaları durumunda 24 saat içinde ölür. Hızlı transport ve resüsitasyon, travma konusunda uyanıklık, çok kesitli bilgisayarlı tomografi varlığı ve zamanında girişim, aortik yaralanmadaki sağkalımı anlamlı şekilde düzeltebilmektedir.

**Anahtar Sözcükler:** Endoluminal stent yerleştirme; travmatik aortik yaralanma.

Trauma is the leading cause of death under the age of 35 years worldwide.<sup>[1]</sup> Traumatic aortic rupture is responsible for 18% of all road accident mortality.<sup>[2]</sup> Eighty percent of these patients die at the scene of the accident. Of the survivors, 50% die within 24 hours if left untreated.<sup>[3,4]</sup>

Rapid transport and resuscitation, awareness of the injury, availability of multi-slice computed tomography (MSCT), and timely intervention can significantly improve survival in aortic injury.

### CASE REPORT

A 19-year-old Saudi male was hospitalized on an emergency basis following an automobile accident. On admission, he was conscious and hemodynamically stable following resuscitation and was found to have multiple long bone injuries and facial cuts and abrasions. His chest X-ray was unremarkable.

He continued to complain of intermittent chest pain and a repeat chest X-ray on day 2 revealed mild haziness in the left hemithorax. MSCT with contrast dye was done and revealed a leak in the descending

thoracic aorta and significant left hemothorax (Figs. 1,2).

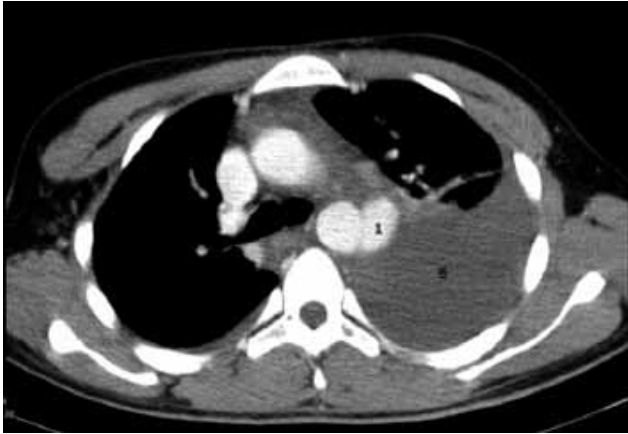
The patient continued to be hemodynamically stable with satisfactory arterial blood gas values. It was decided to transfer him to a specialized cardiovascular center without insertion of a chest tube or intubation. He was successfully treated with endoluminal stenting (ELS) the next day.

### DISCUSSION

In the Kingdom of Saudi Arabia (KSA), trauma is the second cause of death in all age groups, and it is the first cause of death in the first four decades of life.<sup>[5]</sup> The incidence of mortality following road traffic accidents is increasing in the KSA.<sup>[6]</sup>

The descending thoracic aorta is fixed to the spine by the preaortic fascia. The proximal aorta and arch are relatively mobile. This differential fixity results in shear stress in the region of the aortic isthmus during rapid deceleration (Fig. 3).

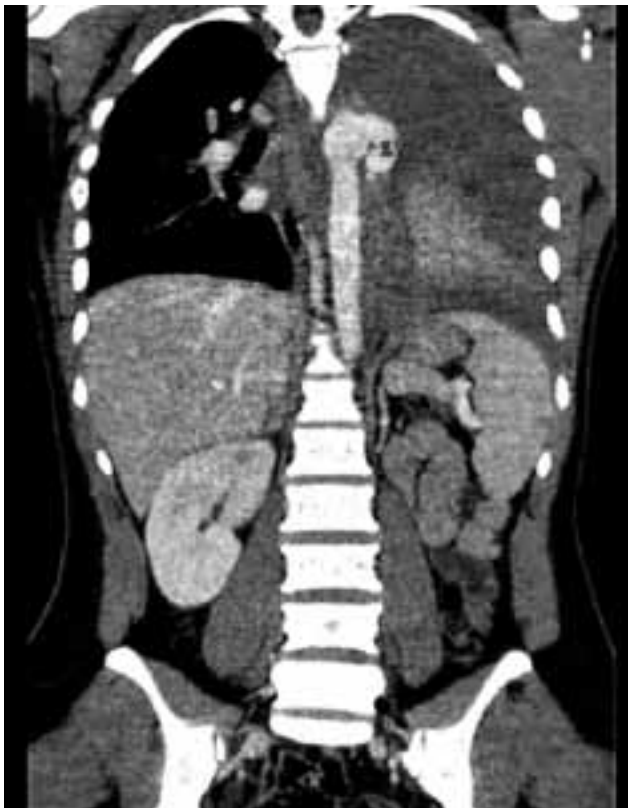
Eighty percent of these injuries occur at the isthmus of the aorta, the portion between the left sub-



**Fig. 1.** Leak in descending thoracic aorta (1) and left hemothorax (2).

clavian artery and the ligamentum arteriosum. The injury and its extent can be outlined satisfactorily by transesophageal echo (TEE) and MSCT.<sup>[7,8]</sup> The spectrum of damage inflicted to the aorta varies from a small endoluminal flap to total transection of the aorta.<sup>[7]</sup>

Depending on the severity of the damage, a grading system has been proposed that can help the clinician in deciding how best to treat the patient (Table



**Fig. 2.** Reconstructed view of the thoracic aortic injury.

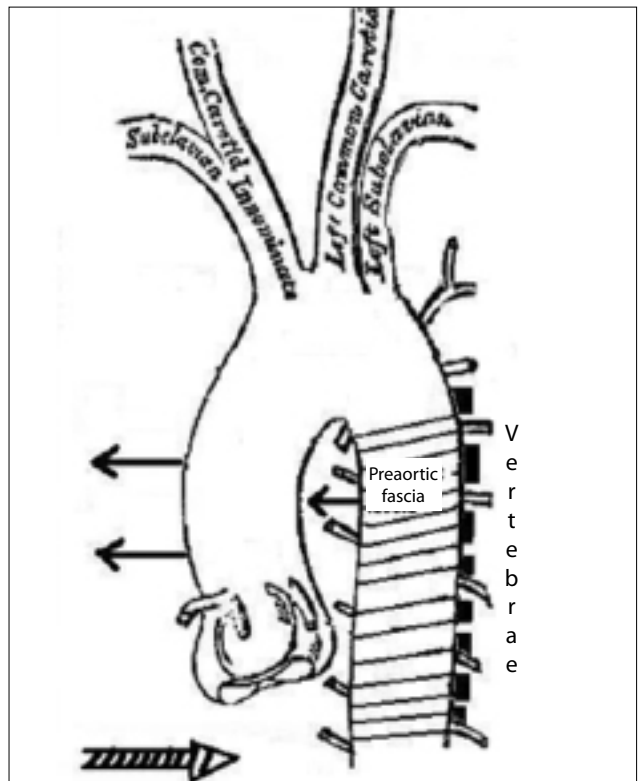
**Table 1.** Grading of severity of aortic injury based on imaging of the lesion

Grade I	Superficial injury to the aortic isthmus. Mural thrombus, intimal tear and intramural hematoma. No alteration in size of aorta.
Grade II	Subadventitial disruption of aortic isthmus and limited traumatic false aneurysm.
Grade III	Transection of the thoracic aorta with massive blood extravasation.

1).<sup>[9]</sup> Grade III injuries require urgent intervention, while patients with Grade I can be managed conservatively.<sup>[7]</sup>

Some Grade II patients remain stable enough for other serious injuries to be managed first or for transfer to a specialized center. Medical management is targeted at maintaining a mean arterial blood pressure below 60 mmHg.<sup>[7,10]</sup>

Before the development of endoluminal interventions, surgery was the treatment of choice for this group of desperately ill patients.<sup>[11-15]</sup> The mortality of surgery is quoted as 24%. Paraplegia following surgery occurs in up to 19.2% of survivors.<sup>[16]</sup>



**Fig. 3.** Rapid deceleration fixes the descending aorta to the spine.

Endoluminal stenting (ELS) has made rapid advances and the mortality in a recent review of 284 patients reported in 61 publications was found to be 5.6%.<sup>[17]</sup> No incidence of paraplegia was reported since cross-clamping the aorta and interruption of the circulation are not required.

The introduction of airbags has added a new dimension to this grave injury. Air bag deployment can result in serious thoracic injury, including traumatic aortic injury, and has been implicated in at least three reports.<sup>[10,18,19]</sup> An inflation rate of 6 L/ms can generate a velocity between 98 and 211 mph.<sup>[20]</sup>

In one of the reports, a car crashed into the concrete wall of a parking lot at approximately 10 mph, resulting in airbag deployment. The patient suffered thoracic aortic injury, which was subsequently managed with ELS. It was significant that the patient was managed conservatively for five days before definitive treatment.<sup>[10]</sup>

In the KSA, with the availability of MSCT and of ELS in many hospitals and all facilities for repair, greater awareness of this potentially fatal condition and rapid diagnosis and transportation of patients will help to improve survival.

#### REFERENCES

1. Al-Salem AH, Qaisaruddin S. Trauma in a district general hospital. *Saudi Medical Journal* 1997;18:49-3.
2. Greendyke RM. Traumatic rupture of aorta; special reference to automobile accidents. *JAMA* 1966;195:527-30.
3. Fabian TC, Richardson JD, Croce MA, Smith JS Jr, Rodman G Jr, Kearney PA, et al. Prospective study of blunt aortic injury: Multicenter Trial of the American Association for the Surgery of Trauma. *J Trauma* 1997;42:374-80; discussion 380-3.
4. Parmley LF, Mattingly TW, Manion WC, Jahnke EJ Jr. Nonpenetrating traumatic injury of the aorta. *Circulation* 1958;17:1086-101.
5. Al Turki S. Trauma and ATLS Training in Saudi Arabia. *The Middle East Journal of Emergency Medicine* 2001;1:
6. Al Rodhan N, Lifeso RM. Traffic accidents in Saudi Arabia: an epidemic. *Ann Saudi Med* 1986;6:69-70.
7. Vignon P, Martailé JF, François B, Rambaud G, Gastinne H. Transesophageal echocardiography and therapeutic management of patients sustaining blunt aortic injuries. *J Trauma* 2005;58:1150-8.
8. Gavant ML, Menke PG, Fabian T, Flick PA, Graney MJ, Gold RE. Blunt traumatic aortic rupture: detection with helical CT of the chest. *Radiology* 1995;197:125-33.
9. Goarin JP, Cluzel P, Gosgnach M, Lamine K, Coriat P, Riou B. Evaluation of transesophageal echocardiography for diagnosis of traumatic aortic injury. *Anesthesiology* 2000;93:1373-7.
10. Lin PH, Bush RL, Lumsden AB. Traumatic aortic pseudoaneurysm after airbag deployment: successful treatment with endoluminal stent-graft placement and subclavian-to-carotid transposition. *J Trauma* 2005;58:1282-4.
11. Ott MC, Stewart TC, Lawlor DK, Gray DK, Forbes TL. Management of blunt thoracic aortic injuries: endovascular stents versus open repair. *J Trauma* 2004;56:565-70.
12. Scheinert D, Krankenberg H, Schmidt A, Gummert JF, Nitzsche S, Scheinert S, et al. Endoluminal stent-graft placement for acute rupture of the descending thoracic aorta. *Eur Heart J* 2004;25:694-700.
13. Dunham MB, Zygun D, Petrsek P, Kortbeek JB, Karmy-Jones R, Moore RD. Endovascular stent grafts for acute blunt aortic injury. *J Trauma* 2004;56:1173-8.
14. Karmy-Jones R, Hoffer E, Meissner MH, Nicholls S, Mattos M. Endovascular stent grafts and aortic rupture: a case series. *J Trauma* 200;55:805-10.
15. Amabile P, Collart F, Gariboldi V, Rollet G, Bartoli JM, Piquet P. Surgical versus endovascular treatment of traumatic thoracic aortic rupture. *J Vasc Surg* 2004;40:873-9.
16. Jahromi AS, Kazemi K, Safar HA, Doobay B, Cinà CS. Traumatic rupture of the thoracic aorta: cohort study and systematic review. *J Vasc Surg* 2001;34:1029-34.
17. Lettinga-van de Poll T, Schurink GW, De Haan MW, Verbruggen JP, Jacobs MJ. Endovascular treatment of traumatic rupture of the thoracic aorta. *Br J Surg* 2007;94:525-33.
18. Brown DK, Roe EJ, Henry TE. A fatality associated with the deployment of an automobile airbag. *J Trauma* 1995;39:1204-6.
19. deGuzman BJ, Morgan AS, Pharr WF. Aortic transection following air-bag deployment. *N Engl J Med* 1997;337:573-4.
20. National Highway Traffic Safety Administration. *Airbag Deployment Characteristics*. Springfield, VA: National Technical Information Service; 1992.