

# Prevention of adhesion to prosthetic mesh: comparison of oxidized generated cellulose, polyethylene glycol and hylan G-F 20

Prostetik yamaya karşı adezyonun önlenmesi: Okside rejenere selüloz,  
polietilen glikol ve hylan G-F 20'nin karşılaştırılması

Ediz ALTINLI,<sup>1</sup> Aziz SÜMER,<sup>2</sup> Neşet KÖKSAL,<sup>1</sup> Ender ONUR,<sup>3</sup> Serkan SENGER,<sup>1</sup>  
Ersan EROĞLU,<sup>1</sup> Atilla ÇELİK,<sup>1</sup> Gülistan GÜMRÜKÇÜ<sup>4</sup>

## BACKGROUND

The aim of this study was to investigate the impact of oxidized generated cellulose, polyethylene glycol and hylan G-F 20 on adhesion formation, fibrosis and inflammation after repair of abdominal wall defect with polypropylene mesh in an animal model.

## METHODS

Forty rats were divided into four groups and abdominal wall defect was established. The defect was repaired with polypropylene mesh alone (control group), polypropylene mesh and hylan G-F 20 as adhesion barrier, polypropylene mesh and oxidized generated cellulose as adhesion barrier, or polypropylene mesh and polyethylene glycol as adhesion barrier in Groups I, II, III, and IV, respectively. Rats were sacrificed on the 14th day in all groups.

## RESULTS

A comparison of the groups in terms of macroscopic adhesion scores revealed statistically significant differences between the groups using an adhesion barrier and the control group. Severe fibroblast proliferation was seen in the control group and mild fibroblast proliferation was seen in polyethylene glycol group.

## CONCLUSION

Polyethylene glycol is an effective adhesion prevention barrier. Laparoscopic surgery has become the standard method in most of the surgical field. With its laparoscopic apparatus, polyethylene glycol allows easy application on the damaged surface.

**Key Words:** Abdominal surgery; adhesion barrier; prevention.

## AMAÇ

Bu çalışmanın amacı, hayvan modelinde karın duvarı defektlerinin polipropilen yama ile tamirinden sonra oluşan adezyon formasyonu, fibrozis ve enflamasyon üzerine okside rejenere selüloz, polietilen glikol ve hylan G-F 20'nin etkilerini araştırmaktır.

## GEREÇ VE YÖNTEM

Kırk sıçan dört gruba ayrıldı ve karın duvarı defekti oluşturuldu. Defektler sırası ile grup I, II, III ve IV olacak şekilde; sadece polipropilen yama (kontrol grubu), polipropilen yama ve adezyon bariyeri olarak hylan G-F 20, polipropilen yama ve adezyon bariyeri olarak okside rejenere selüloz, polipropilen yama ve adezyon bariyeri olarak polietilen glikol kullanılarak onarıldı. Sıçanlar 14. günde öldürüldü.

## BULGULAR

Makroskopik adezyon açısından karşılaştırıldıklarında kontrol grubu ile adezyon bariyeri kullanan gruplar arasında istatistiksel olarak anlamlı fark bulundu. Kontrol grubunda ileri derecede fibroblast proliferasyonu ve polietilen glikol grubunda hafif fibroblast proliferasyonu görüldü.

## SONUÇ

Polietilen glikol etkili bir adezyon bariyeridir. Son dönemde laparoskopik cerrahi birçok alanda standart metot haline gelmiştir. Polietilen glikol laparoskopik düzeneği sayesinde hasarlı yüzey üzerine uygulama kolaylığı sağlamaktadır.

**Anahtar Sözcükler:** Karın cerrahisi; adezyon bariyeri; koruma.

Departments of <sup>1</sup>General Surgery, <sup>2</sup>Pathology, Haydarpaşa Numune Training and Research Hospital, Istanbul; <sup>3</sup>Department of General Surgery, Yüzüncü Yıl University, Faculty of Medicine, Van; Department of General Surgery, Fatih Sultan Mehmet Training and Research Hospital, Istanbul, Turkey.

Haydarpaşa Numune Eğitim ve Araştırma Hastanesi, <sup>1</sup>Genel Cerrahi Kliniği, <sup>2</sup>Patoloji Bölümü, İstanbul; <sup>3</sup>Yüzüncü Yıl Üniversitesi, Tıp Fakültesi, Genel Cerrahi Kliniği, Van; <sup>4</sup>Fatih Sultan Mehmet Eğitim ve Araştırma Hastanesi, Genel Cerrahi Kliniği, İstanbul.

Adhesions are the fibrous bands formed between the body structures and neighboring organs. They typically form from inflammation and after surgical traumas. The adhesions arising after abdominal operations rank first among the problems with which modern surgery has to cope. Independent of the methods used, after each abdominal operation, intraabdominal adhesion formations emerge. The postoperative intraabdominal adhesion rates range between 64-97%. Following open gynecological interventions, this ratio may increase up to 97%.<sup>[1-7]</sup> The postoperative adhesions are an important problem for surgeons at reoperation owing to the increased access time into the abdominal cavity, difficulties during exploration and injuries to the adjacent organs. In 1998 in the United States, the cost of treatment for preventing formation of adhesions and complications was 1.6 billion dollars. In the U.S. alone, 400,000 adhesion-related operations per year are applied, oriented to complications formed due to adhesion. The defects constituted on the abdominal wall cannot be closed primarily. Under these conditions, the usage of prosthetic material is essential. To date, many prosthetic materials have been developed and used in the repair of incisional hernia. Multifilament polyester mesh, double filament polypropylene mesh and polytetrafluoroethylene mesh are some of these.<sup>[8-10]</sup> For preventing the formation of postoperative adhesions, the benefits of physical membranes have been shown in many experimental studies.<sup>[11-13]</sup> It is difficult to apply adhesion barriers directly on a damaged surface. The physical barriers suitable for usage especially during laparoscopic operation are limited.<sup>[14]</sup>

Oxidized regenerated cellulose (Interceed®) has a beneficial effect on adhesions by forming a physical separation of adjacent peritoneal surfaces.<sup>[15]</sup> Polyethylene glycol (SprayGel®) consists of two synthetic liquid precursors that, when mixed, rapidly cross-link to form a solid, flexible, absorbable hydrogel.<sup>[16]</sup> hylan G-F 20 (Synvise®) is a high-molecular-weight, reticulated hyaluronic acid.<sup>[17]</sup>

The aim of the present study was to evaluate whether adhesions due to intraperitoneal mesh can be prevented with the use of physical barriers such as oxidized generated cellulose, polyethylene glycol and hylan G-F 20.

## MATERIALS AND METHODS

This study was performed in the Haydarpaşa Numune Training and Research Hospital Animal Research Laboratory and was approved by Ethical Committee of Haydarpaşa Numune Training And Research Hospital (4/15/2004, no. 10).

In the study, 40 male Wistar Albino rats weighing approximately 250-300 g were used. The animals

were cared for according to the principles of the National Institutes of Health publication "Guide for Care and Use of Laboratory Animals," revised 1996.

### Surgical Procedure

Following anesthesia application of intramuscular ketamine (50 mg/kg) injection to the rats, a 2 cm midline skin incision was done. After the skin incision, a 2x2 cm full layer defect was performed on the abdominal wall of the rats, and the defect was repaired by mesh materials 2.5 by 2.5 cm in diameter. After polypropylene mesh was fixed to the abdominal wall with 4/0 polypropylene suture unilaterally, anti-adhesive materials were placed under the mesh, respectively, and the free polypropylene mesh edges were fixed to abdominal wall with 4/0 polypropylene suture. Rats were divided into four groups of 10 rats each as follows:

Group I: Polypropylene mesh only (control group)

Group II: Polypropylene mesh and hylan G-F 20 as adhesion barrier

Group III: Polypropylene mesh and oxidized regenerated cellulose as adhesion barrier

Group IV: Polypropylene mesh and polyethylene glycol as adhesion barrier

The surgical procedure was done under a semi-sterile condition. Different surgeons performed the first and second laparotomies. En bloc removal of mesh and adhesions with any visceral organ was done for all groups, and the samples were preserved in 10% formol solution for histopathological assessment.

### Evaluation of Adhesion Formation

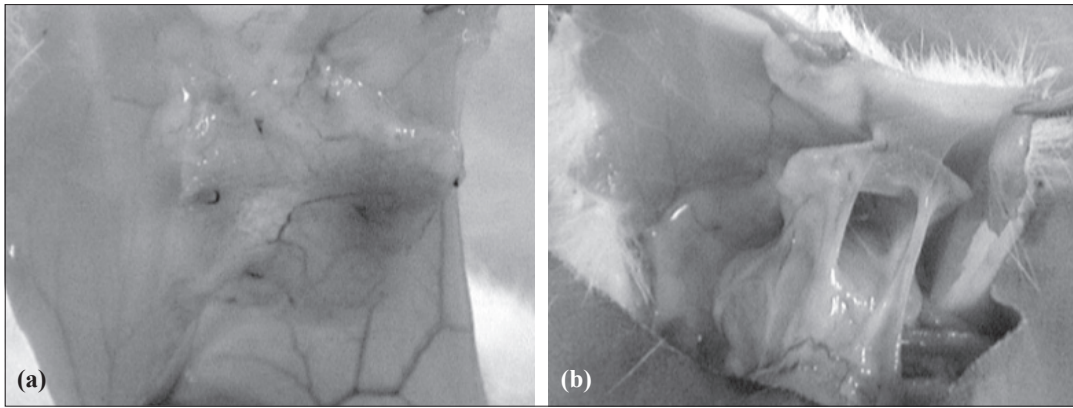
Adhesion formation was evaluated macroscopically and microscopically. Macroscopic evaluation was performed according to the scoring system suggested by Mazuji et al.<sup>[18]</sup> (Table 1) (Fig. 1).

### Histopathologic Evaluation

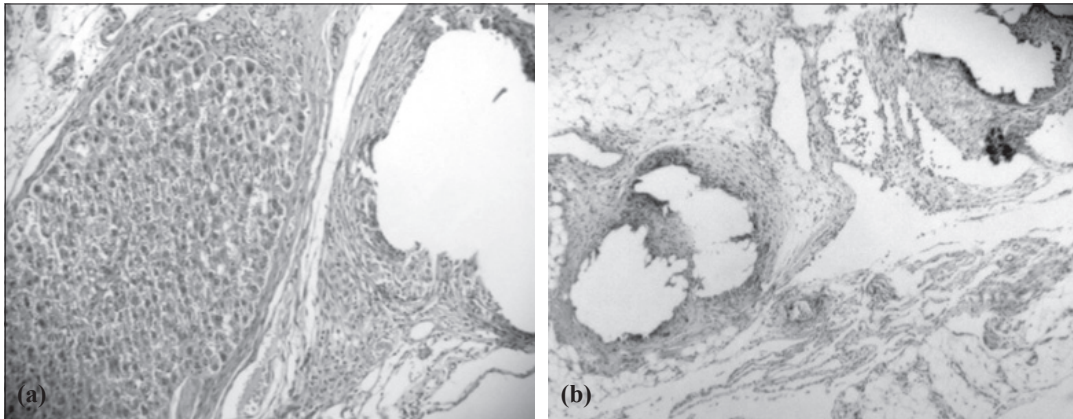
An independent pathologist performed the histopathologic evaluation. Five-micron thick sections from the tissues embedded into paraffin were obtained. Sections were stained with hematoxylin-eosin (H&E) and evaluated under light microscope with respect to fibrosis and inflammation (Table 2 and Fig. 2).<sup>[19]</sup>

**Table 1.** Adhesion severity scoring scale (Majuzi et al.)

Score	Evaluation
0	No adhesion
1	Filmy adhesions easily separable with blunt dissection
2	Mild to moderate adhesions with freely dissectible plane
3	Moderate to dense adhesion with difficult dissection
4	Non-dissectible plane



**Fig. 1.** (a) Macroscopic view of adhesions with score 0. (b) Macroscopic view of adhesions with score 4.



**Fig. 2.** (a) Histopathologic view in the control group: Adhesions between liver and polypropylene mesh pore due to fibrosis (H-E x 400). (b) Histopathologic view in polyethylene glycol group: Mild inflammation is seen around the mesh pore (H-E x 40).

### Statistical Analysis

SPSS (Statistical Package for the Social Sciences) for Windows 11.0 program was used for statistical analysis. The difference between the groups for each type was reviewed by chi-square test. The relation between groups was investigated by employing the Spearman correlation analysis.

### RESULTS

The standardized surgical procedures and the administration of the protocols were well tolerated by the animals. None of the animals died postoperatively. Rats were sacrificed on the 14th day in all groups with high-dose ether anesthesia.

Bilateral comparison of the groups in terms of macroscopic adhesion scores demonstrated statistically significant differences between the groups with an adhesion barrier and the control group ( $p < 0.004$ ,  $p < 0.01$ ,  $p < 0.0001$ ), respectively. It was found that the polyethylene glycol group was the most distinct group from the other groups in terms of macroscopic adhesion. The distribution of the groups with respect to adhesion scores is shown in Table 3.

Bilateral comparison of the groups in terms of the inflammation scores revealed statistically significant differences between the group using polyethylene glycol and the control group ( $p < 0.0001$ ). No statisti-

**Table 2.** Histopathologic evaluation performed according to fibrosis grading scale and inflammation grading scale (Hooker et al.)

Score	Fibrosis grading scale	Inflammation grading scale
0	None	None
1	Minimal, loose	Giant cells, occasional lymphocytes, and plasma cells
2	Moderate	Giant cells, plasma cells, eosinophils, neutrophils
3	Florid, dense	Many inflammatory cells, microabscesses

**Table 3.** Comparison of the groups in terms of macroscopic adhesion severity score

Adhesion severity score	Groups			
	Control (n=10)	Hylan G-F 20 (n=10)	Oxidized Regenerated Cellulose (n=10)	Polyethylene glycol (n=10)
0	–	–	–	3 (30%)
1	–	1 (10%)	–	5 (50%)
2	–	5 (50%)	4 (40%)	2 (20%)
3	3 (30%)	4 (40%)	5 (50%)	–
4	7 (70%)	–	1 (10%)	–
Total	10	10	10	10

**Table 4.** Comparison of the groups in terms of inflammation score

Inflammation score	Groups			
	Control (n=10)	Hylan G-F 20 (n=10)	Oxidized Regenerated Cellulose (n=10)	Polyethylene glycol (n=10)
0	–	–	–	–
1	–	3 (30%)	3 (30%)	8 (80%)
2	6 (60%)	6 (60%)	6 (60%)	2 (20%)
3	4 (40%)	1 (10%)	1 (10%)	–
Total	10	10	10	10

**Table 5.** Comparison of the groups in terms of fibrosis score

Fibrosis score	Groups			
	Control (n=10)	Hylan G-F 20 (n=10)	Oxidized Regenerated Cellulose (n=10)	Polyethylene glycol (n=10)
0	–	–	–	–
1	–	3 (30%)	2 (20%)	8 (80%)
2	5 (50%)	5 (50%)	7 (70%)	2 (20%)
3	5 (50%)	2 (20%)	1 (10%)	–
Total	10	10	10	10

cal difference was found between the other adhesion barriers and the control group. The distribution of the groups as per the inflammation scores is shown in Table 4.

Bilateral comparison of the groups in terms of the fibrosis score showed a statistically significant difference between the polyethylene glycol group and control group ( $p < 0.001$ ). No statistical difference was found between the other adhesion barriers and the control group. The distribution between groups is shown in Table 5.

## DISCUSSION

Adhesion formation after abdominopelvic procedures has an impact upon patient morbidity, success of subsequent surgical procedures and costs to the health care system in general. In the current approach,

in order to prevent adhesions, peritoneal damage should be reduced during the operation, inflammatory response should be reduced, coagulation formation should be prevented, and fibrinolysis has to be stimulated. An ideal physical membrane barrier should not affect wound healing or stimulate fibrosis formation and should be effective in the presence of blood and foreign material.<sup>[14]</sup> Despite the development of minimally invasive techniques in many procedures and the ultimate decrease in trauma during operations, the technique alone does not effectively eliminate adhesion formation.<sup>[16]</sup>

While using Prolene mesh, contact between the mesh and the visceral organs leads to a severe adhesion formation. In the study of Felemovicus et al.,<sup>[20]</sup> an abdominal defect of 2.5 cm was made in three groups comprised of 20 rats each, and those defects

were repaired by Prolene, Sepramesh, and Sepramesh + Seprafilm, respectively. Adhesion signs were observed by electron microscopy in all 20 rats who received Prolene mesh. Similarly, we determined Grade 3 and 4 adhesions in 10 out of 10 rats in our control group. There was a statistically significant difference between the Prolene group and polyethylene glycol and hylan G-F 20 groups with regard to macroscopic adhesion grades.

To our knowledge, there is no study focusing on the usage of hylan G-F 20 as an adhesion barrier in intraabdominal adhesions in the current literature. In our study, hylan G-F 20 was used as an adhesion barrier by laying it underneath the polypropylene mesh. According to the statistical analysis, adhesion grade was 2 in one (10%), 3 in five (50%) and 4 in four (40%) subjects in the hylan G-F 20 group. In terms of macroscopic adhesion grade, there was a statistically significant difference between the hylan G-F 20 and Prolene groups.

The TC-7 (oxidized regenerated cellulose) barrier has been shown to provide significant reductions in the severity, incidence and width of postoperative adhesion formation.<sup>[21,22]</sup> Reid et al.<sup>[15]</sup> conducted a prospective clinical study in which they evaluated 40 female patients with a history of adhesiolysis because of ovarian adhesions or cystectomy due to ovarian cyst. They covered both of the ovaries with TC-7, but sprayed heparin solution over one of them. The second-look laparoscopy demonstrated adhesion in 21 (52.5%) of 40 patients in the TC-7 + heparin spray group and in 26 (65%) of 40 patients in the TC-7 group, and use of heparin in conjunction with TC-7 was shown to exhibit no statistically significant difference. In our study, based on the macroscopic scores, we determined a statistically significant difference between the TC-7 and polypropylene groups. We also determined a statistically significant difference between the polyethylene glycol and TC-7 groups; the difference between TC-7 and hylan G-F 20 was not statistically significant.

Polyethylene glycol is a nontoxic and non-migrating adhesion barrier, which is used during laparoscopic and open surgical procedures due to its strong adhesive properties and easy-to-apply nature. It has an air pump and an apparatus that are particularly convenient for laparoscopic surgery. There is no risk of viral transmission via synthetic pieces and the polyethylene-based hydrogel does not carry any infection potential. Moreover, owing to its methylene blue kit, it contributes to the visualization of the damaged surface by staining it blue.<sup>[23-25]</sup>

Dunn et al.<sup>[23]</sup> divided 16 rats with cecum abrasion into control and polyethylene glycol groups, while splitting 20 New Zealand rabbits with induced uterine

horn abrasion again into control and polyethylene glycol groups. They treated the abrasion site with polyethylene glycol in the treatment groups. An abrasion between the cecum and lateral wall was determined in 7 of 8 rats in the control group and in 1 of 8 rats in the polyethylene group with cecum abrasion model. Adhesion was found to cover more than 50% of the uterine horn in 8 of 10 rabbits in the control group and in 2 of 10 rabbits in the polyethylene glycol group with uterine horn abrasion. Polyethylene glycol was observed to cause a significant reduction in the incidence of adhesion formation.

Metler et al.<sup>[25]</sup> conducted a study on 64 patients by dividing them into two groups and comparing the control group (n=30) treated solely with surgery and the study group treated with surgery + polyethylene glycol. Open and laparoscopic surgeries were performed for leiomyoma or leiomyomatous uterine lesions. Laparoscopic surgery was applied on 82.4% (n=28) of the study group and 76.7% (n=23) of the control group. Mean duration for application of polyethylene glycol barrier was 3.7 minutes, and the average amount of polyethylene glycol used for each patient was 1.9 kits. Adhesion formation in the secondary laparotomies was statistically significantly lower in the study group than in the control group.

In this study, polyethylene glycol, sprayed underneath the mesh during closure of the induced ventral defect with polypropylene mesh, was found to provide statistically significant reductions in macroscopic adhesion formation compared with the hylan G-F 20 and TC-7 applications. Based on the evaluations focused on macroscopic adhesions, the difference between the polyethylene glycol group and control group was found to be highly statistically significant. The highest difference was observed between the polyethylene glycol and control groups. The difference between the polyethylene glycol group and the TC-7 group in terms of macroscopic adhesion score was highly significant as well. Moreover, the difference between polyethylene glycol and hylan G-F 20 was statistically significant. Macroscopically, the polyethylene glycol group appeared to have the least amount of adhesion formation compared with the other groups, and this difference was evaluated to be statistically significant. Ozmen et al.<sup>[26]</sup> found that using sodium hyaluronate reduces the incidence and severity of abdominal adhesions following laparoscopic mesh insertion.

In conclusion, although hylan G-F 20 is used for cartilage repair of the joints, it can also be used as an antiadhesive barrier after abdominal operations. Polyethylene glycol was an effective adhesion prevention barrier, and results seem to be at least comparable with those of other products. Polyethylene glycol is a reliable and easily applied adhesion barrier, and reduces

adhesion formation after open and laparoscopic surgery.

## REFERENCES

1. Szabo A, Haj M, Waxsman I, Eitan A. Evaluation of seprafilm and amniotic membrane as adhesion prophylaxis in mesh repair of abdominal wall hernia in rats. *Eur Surg Res* 2000;32:125-8.
2. Moreira H Jr, Wexner SD, Yamaguchi T, Pikarsky AJ, Choi JS, Weiss EG, et al. Use of bioresorbable membrane (sodium hyaluronate + carboxymethylcellulose) after controlled bowel injuries in a rabbit model. *Dis Colon Rectum* 2000;43:182-7.
3. Risberg B. Adhesions: preventive strategies. *Eur J Surg Suppl* 1997;577:32-9.
4. Becker JM, Dayton MT, Fazio VW, Beck DE, Stryker SJ, Wexner SD, et al. Prevention of postoperative abdominal adhesions by a sodium hyaluronate-based bioresorbable membrane: a prospective, randomized, double-blind multicenter study. *J Am Coll Surg* 1996;183:297-306.
5. Menzies D, Ellis H. Intestinal obstruction from adhesions--how big is the problem? *Ann R Coll Surg Engl* 1990;72:60-3.
6. Ray NF, Larsen JW Jr, Stillman RJ, Jacobs RJ. Economic impact of hospitalizations for lower abdominal adhesiolysis in the United States in 1988. *Surg Gynecol Obstet* 1993;176:271-6.
7. Hershlag A, Diamond MP, DeCherney AH. Adhesiolysis. *Clin Obstet Gynecol* 1991;34:395-402.
8. Dinsmore RC, Calton WC Jr, Harvey SB, Blaney MW. Prevention of adhesions to polypropylene mesh in a traumatized bowel model. *J Am Coll Surg* 2000;191:131-6.
9. Oncel M, Remzi FH, Senagore AJ, Connor JT, Fazio VW. Application of Adcon-P or Seprafilm in consecutive laparotomies using a murine model. *Am J Surg* 2004;187:304-8.
10. Johns DA, Ferland R, Dunn R. Initial feasibility study of a sprayable hydrogel adhesion barrier system in patients undergoing laparoscopic ovarian surgery. *J Am Assoc Gynecol Laparosc* 2003;10:334-8.
11. Günerhan Y, Caglayan K, Sumer A, Koksall N, Altınlı E, Onur E, et al. The efficacy of carboxymethylcellulose for prevention adhesion formation after thyroid region surgery. *Kafkas Uni Vet Fak Der* 2009;5:785-9.
12. Rodgers KE, Johns DB, Girgis W, Campeau J, diZerega GS. Reduction of adhesion formation with hyaluronic acid after peritoneal surgery in rabbits. *Fertil Steril* 1997;67:553-8.
13. Wiseman DM, Gottlick-Iarkowski L, Kamp L. Effect of different barriers of oxidized regenerated cellulose (ORC) on cecal and sidewall adhesions in the presence and absence of bleeding. *J Invest Surg* 1999;12:141-6.
14. Zhou J, Elson C, Lee TD. Reduction in postoperative adhesion formation and re-formation after an abdominal operation with the use of N, O - carboxymethyl chitosan. *Surgery* 2004;135:307-12.
15. Reid RL, Hahn PM, Spence JE, Tulandi T, Yuzpe AA, Wiseman DM. A randomized clinical trial of oxidized regenerated cellulose adhesion barrier (Interceed, TC7) alone or in combination with heparin. *Fertil Steril* 1997;67:23-9.
16. Mettler L, Audebert A, Lehmann-Willenbrock E, Schive K, Jacobs VR. Prospective clinical trial of SprayGel as a barrier to adhesion formation: an interim analysis. *J Am Assoc Gynecol Laparosc* 2003;10:339-44.
17. Kahan A, Llew PL, Salin L. Prospective randomized study comparing the medicoeconomic benefits of Hylan GF-20 vs. conventional treatment in knee osteoarthritis. *Joint Bone Spine* 2003;70:276-81.
18. Mazuji MK, Kalambaheti K, Pawar B. Prevention of adhesions with polyvinylpyrrolidone. Preliminary report. *Arch Surg* 1964;89:1011-5.
19. Hooker GD, Taylor BM, Driman DK. Prevention of adhesion formation with use of sodium hyaluronate-based bioresorbable membrane in a rat model of ventral hernia repair with polypropylene mesh--a randomized, controlled study. *Surgery* 1999;125:211-6.
20. Felemovicus I, Bonsack ME, Hagerman G, Delaney JP. Prevention of adhesions to polypropylene mesh. *J Am Coll Surg* 2004;198:543-8.
21. Saravelos HG, Li TC. Physical barriers in adhesion prevention. *J Reprod Med* 1996;41:42-51.
22. Azziz R. Microsurgery alone or with INTERCEED Absorbable Adhesion Barrier for pelvic sidewall adhesion reformation. The INTERCEED (TC7) Adhesion Barrier Study Group II. *Surg Gynecol Obstet* 1993;177:135-9.
23. Dunn R, Lyman MD, Edelman PG, Campbell PK. Evaluation of the SprayGel adhesion barrier in the rat cecum abrasion and rabbit uterine horn adhesion models. *Fertil Steril* 2001;75:411-6.
24. Ferland R, Mulani D, Campbell PK. Evaluation of a sprayable polyethylene glycol adhesion barrier in a porcine efficacy model. *Hum Reprod* 2001;16:2718-23.
25. Mettler L, Audebert A, Lehmann-Willenbrock E, Schive-Peterhansl K, Jacobs VR. A randomized, prospective, controlled, multicenter clinical trial of a sprayable, site-specific adhesion barrier system in patients undergoing myomectomy. *Fertil Steril* 2004;82:398-404.
26. Ozmen MM, Aslar AK, Terzi MC, Albayrak L, Berberoğlu M. Prevention of adhesions by bioresorbable tissue barrier following laparoscopic intraabdominal mesh insertion. *Surg Laparosc Endosc Percutan Tech* 2002;12:342-6.