



Delayed presentation of post-traumatic diaphragmatic hernia with gastric volvulus: a case report

Gastrik volvulusla geç dönemde ortaya çıkan travma sonrası gelişmiş diyafragma hernisi: Olgu sunumu

Fahri YAKARYILMAZ,¹ Oktay BANLI,² Hasan ALTUN,² Sefa GULİTER¹

Post-traumatic diaphragmatic hernia complicated by gastric volvulus may manifest immediately or several years after the incident. Delayed presentation of traumatic diaphragmatic hernia with gastric volvulus is relatively unusual. We report a 28-year-old male patient who admitted with gastric volvulus due to traumatic diaphragmatic hernia after sustaining a knife wound to the left lower chest one year before presentation. The patient has been followed without any symptom for two years since the diaphragmatic hernia was repaired by primary suture plication.

Key Words: Diaphragmatic hernia; gastric volvulus; trauma.

Gastrik volvulus ile komplike olan post-travmatik diyafragma hernisi olaydan hemen ya da yıllar sonra bulgu verebilir. Travmatik diyafragma hernisinin gastrik volvulusla geç bulgu vermesi nispeten nadir bir durumdur. Burada, bir yıl önce sol alt göğüse aldığı penetran bıçak yaralanması sonrası diyafragmatik herni ve buna bağlı olarak gastrik volvulus gelişen 28 yaşındaki bir erkek hasta sunuldu. Diyafragmatik herninin primer dikişle onarılmasının ardından hasta, son iki yıldır semptomsuz izlenmektedir.

Anahtar Sözcükler: Diyafragma hernisi; gastrik volvulus; travma.

Diaphragmatic hernia may be congenital or traumatic in origin. Traumatic diaphragmatic hernia may manifest immediately or several months/years after the incident. Diaphragmatic hernias resulting from penetrating injuries are more common than from blunt injuries.^[1,2] Diaphragmatic hernia may be complicated by gastric volvulus. Gastric volvulus is an uncommon condition resulting from the twisting of all or a part of the stomach. Most commonly, the greater curvature moves upwards to lie under the cupola of the left diaphragm.^[3] Gastric volvulus cases are usually associated with congenital diaphragmatic hernia.^[4,5] Acute gastric volvulus is a surgical emergency whereas chronic gastric volvulus presents with nonspecific abdominal symptoms. Diagnosis of gastric volvulus is difficult and is based on imaging studies. Delayed presentation of traumatic diaphragmatic hernia with gastric volvulus is relatively unusual.^[3,6,7]

This case report discusses an adult patient who presented with gastric volvulus after sustaining a knife wound to the left lower chest about one year prior to presentation.

CASE REPORT

A 26-year-old male presented with a week of postprandial epigastric pain, nausea and vomiting. His detailed history revealed that he had experienced progressive symptoms of epigastric pain, dyspepsia, vomiting, and weight loss of about 20 kg over a one-year period following a stab wound to the left lower chest. At that time, pneumothorax had been treated by insertion of a left-sided chest tube, which had been removed in the first week of treatment, and the patient had been discharged from the hospital.

On his current admission, physical examination revealed that the patient was in pain, distressed and dehydrated. Chest roentgenography revealed an eventration of the left diaphragm and dilated gastric shadow with an air-fluid level (Fig. 1). On gastroscopic examination, the gastric lumen ahead of the fundus could not be viewed as it was not possible to pass that level and reach the pylorus. A second attempt at gastroscopic examination performed one day later also failed. A barium enema study revealed an organoaxial gastric

¹Department of Gastroenterology, Kırıkkale University Faculty of Medicine, Kırıkkale; ²Department of Surgery, Etlik Specialization Hospital, Ankara, Turkey.

¹Kırıkkale Üniversitesi Tıp Fakültesi, Gastroenteroloji Anabilim Dalı, Kırıkkale; ²Etlik İhtisas Hastanesi, Genel Cerrahi Kliniği, Ankara.

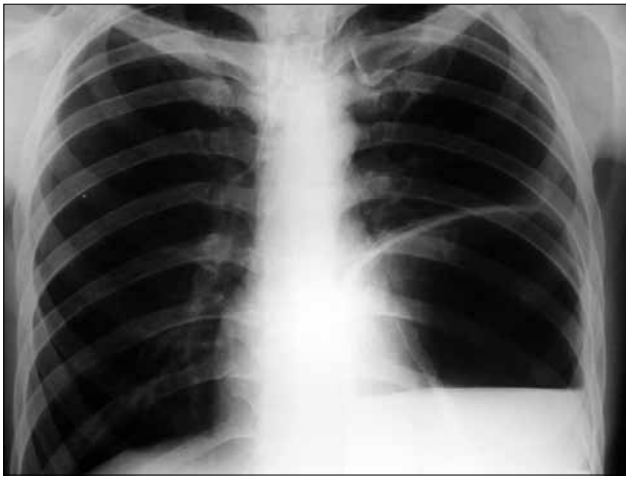

Fig. 1. Chest radiography showing a dilated gastric shadow with a fluid level.

volvulus with gastric outlet obstruction, and the greater curvature of the stomach was above the level of the lesser curvature, and the cardia and pylorus were positioned at about the same level (Fig. 2). The peritoneal cavity was explored through an upper midline abdominal incision. Exploration revealed the presence of a gastric volvulus herniating into the left chest cavity through an approximately 7x3 cm old diaphragmatic defect (Fig. 3). After meticulous dissection, the stomach was reduced into the abdominal cavity, and the diaphragmatic defect was repaired with 0 monofilament polypropylene sutures. The postoperative course was uneventful, and the patient was discharged from the hospital on the 5th postoperative day. In the follow-

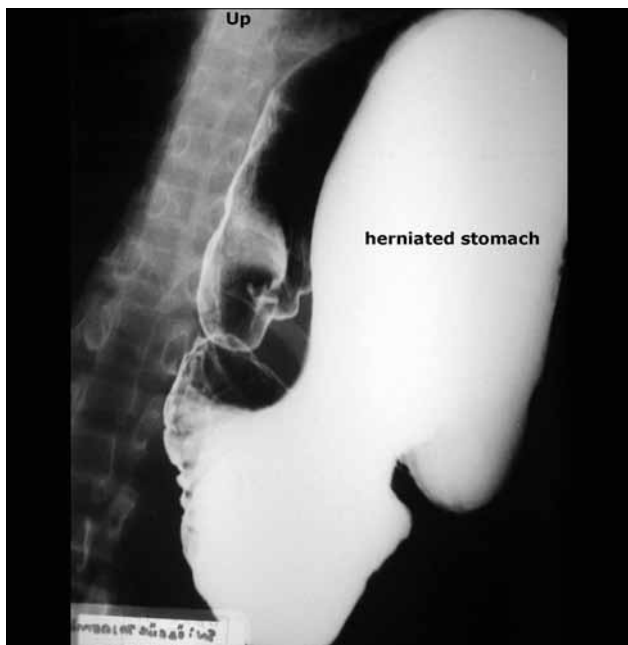

Fig. 2. A barium swallow demonstrating a large paraesophageal hernia with a gastric volvulus and gastric outlet obstruction.

up period of about two years since the surgery, he has remained asymptomatic.

DISCUSSION

Penetrating diaphragmatic injuries are frequently overlooked because initial presentation may reveal no pathologic finding. Chest roentgenography is interpreted as normal in approximately 50% of patients with penetrating diaphragmatic injuries.^[8] In such cases, presentation is usually delayed until the defect enlarges, with visceral herniation, as was most likely the case in this report. These patients will experience a progressive increase in the visceral herniation of all or a portion of a hollow viscus.^[2]

Gastric volvulus associated with traumatic diaphragmatic hernia is relatively rare.^[6,7] As gastric volvulus is itself rare, its coexistence with traumatic diaphragmatic hernia in this case made the diagnosis even more difficult.^[9] Gastric volvulus is frequently seen in association with congenital abnormalities, and congenital diaphragmatic hernia presenting in early childhood is the most common of these abnormalities.^[5] Gastric volvulus may present acutely with severe epigastric pain and distention, vomiting followed by retching without vomiting, and difficulty or inability to pass a nasogastric tube (Borchart's triad), or with chronic vague abdominal symptoms. This case is rather unusual because of the delayed presentation of a missed traumatic diaphragmatic hernia associated with gastric volvulus. This patient most likely developed chronic symptoms of gastric volvulus over a one-year period, superimposed by the acute symptoms at presentation.

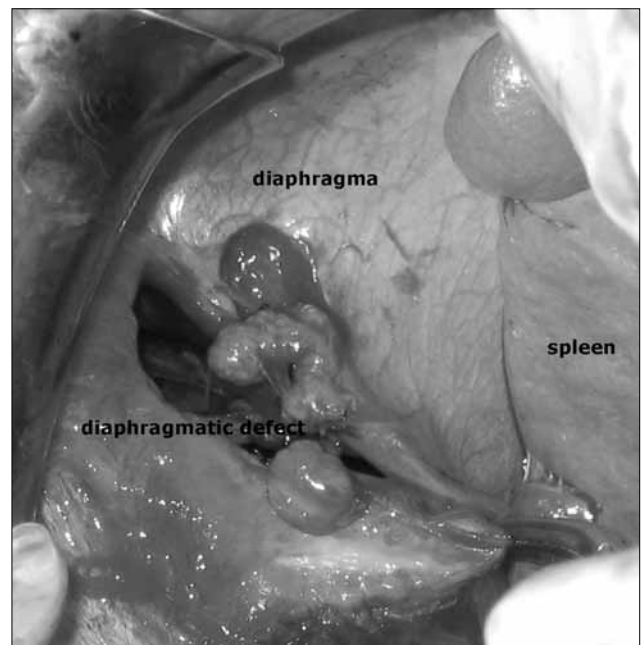


Fig. 3. The appearance of a gastric volvulus herniating into the left chest cavity through an approximately 7x3 cm old left diaphragmatic defect.

The diagnosis of gastric volvulus is usually made by barium enema studies. Radiological signs of gastric volvulus include a retrocardiac “double air-fluid level” on upright films.^[10] It designates abnormal rotation of the stomach along its longitudinal (organoaxial) or transverse (mesenteroaxial) axis. Gastric volvulus is treated by various surgical procedures, depending on the predisposing cause and the condition of the stomach at the time of operation.

The incidence of occult diaphragmatic injuries in penetrating trauma to the left lower chest is high, at 24%.^[11] These injuries are associated with a lack of clinical and radiographic findings, and would have been missed if laparoscopy had not been performed. Patients with penetrating trauma to the left lower chest who do not have any other indication for a laparotomy should undergo laparoscopic evaluation of the left hemidiaphragm to exclude an injury.^[11] Leppaniemi et al.^[12] reported that the incidence of diaphragmatic injury in stab wounds of the lower chest and upper abdomen is 7%, and they concluded that diagnostic laparoscopy should be performed in this group of patients at least in the left-sided stab wounds of the lower chest. In another prospective study, Friese et al.^[13] concluded that in asymptomatic hemodynamically normal patients with penetrating thoracoabdominal injury, laparoscopy alone is sufficient to exclude diaphragmatic injury.

In conclusion, this case demonstrates that traumatic penetrating diaphragmatic injury of the lower chest may easily be missed at initial presentation, and may present itself with a delayed manifestation of a complication. As its diagnosis requires a high index of suspicion and careful interpretation of the chest roentgenogram, all cases with stab wounds that penetrate

the left lower chest should be explored by laparoscopy without delay.

REFERENCES

1. Hedblom CA. Diaphragmatic hernia: A study of three hundred and seventy eight cases in which operation was performed. *JAMA* 1925;85:947.
2. Asensio JA, Demetriades D, Rodriguez A. Injury to the diaphragm. In: Mattox KL, Feliciano DV, Moore EE, editors. *Trauma*. 4th ed. New York: McGraw-Hill; 2000. p. 603-31.
3. Somers L, Szeki I, Hulbert D. Late presentation of diaphragmatic hernia and gastric volvulus. *J Accid Emerg Med* 2000;17:230.
4. McIntyre RC Jr, Bensard DD, Karrer FM, Hall RJ, Lilly JR. The pediatric diaphragm in acute gastric volvulus. *J Am Coll Surg* 1994;178:234-8.
5. Miller DL, Pasquale MD, Seneca RP, Hodin E. Gastric volvulus in the pediatric population. *Arch Surg* 1991;126:1146-9.
6. Bemelman WA, van Baal JG, Keeman JN. Volvulus of the stomach after traumatic hernia diaphragmatica. *Neth J Surg* 1989;41:8-10.
7. Borsari A, Villa EM, Caleffi A, Poletti G, Ambrosino A. Post-traumatic intrathoracic gastric volvulus. Presentation of a clinical case. *Minerva Chir* 1989;44:2275-9.
8. Beal SL. Diaphragm rupture. In: Blaisdell FW, Trunkey DD, editors. *Trauma management. I&II. Abdominal trauma*. New York: Thieme 1993: 83-93.
9. Wastell C, Ellis H. Volvulus of the stomach. A review with a report of 8 cases. *Br J Surg* 1971;58:557-62.
10. Scott RL, Felker R, Winer-Muram H, Pinstein ML. The differential retrocardiac air-fluid level: a sign of intrathoracic gastric volvulus. *Can Assoc Radiol J* 1986;37:119-21.
11. Murray JA, Demetriades D, Asensio JA, Cornwell EE 3rd, Velmahos GC, Belzberg H, et al. Occult injuries to the diaphragm: prospective evaluation of laparoscopy in penetrating injuries to the left lower chest. *J Am Coll Surg* 1998;187:626-30.
12. Leppäniemi A, Haapiainen R. Occult diaphragmatic injuries caused by stab wounds. *J Trauma* 2003;55:646-50.
13. Friese RS, Coln CE, Gentilello LM. Laparoscopy is sufficient to exclude occult diaphragm injury after penetrating abdominal trauma. *J Trauma* 2005;58:789-92.