

# Effect of chitosan coating on surgical sutures to strengthen the colonic anastomosis

Yüksel Altinel, M.D.,<sup>1</sup> Soon Soup Chung, M.D.,<sup>2</sup> Güven Okay, M.D.,<sup>3</sup> Nesrin Uğraş, M.D.,<sup>4</sup>  
Ahmet Fatih Işık, M.D.,<sup>5</sup> Ersin Öztürk,<sup>1</sup> Halil Özgüç, M.D.<sup>1</sup>

<sup>1</sup>Department of General Surgery, Uludağ University Faculty of Medicine, Bursa-Turkey

<sup>2</sup>Department of General Surgery, Ewha University Medical Faculty, Seoul-Korea

<sup>3</sup>Department of Biostatistics, Uludağ University Faculty of Medicine, Bursa-Turkey

<sup>4</sup>Department of Pathology, Uludağ University Hospital, Bursa-Turkey

<sup>5</sup>Department of Textile, Uludağ University Faculty of Textile Engineering, Bursa-Turkey

## ABSTRACT

**BACKGROUND:** We evaluated the feasibility of chitosan-coated sutures for intestinal anastomosis strength through wound-healing effect.

**METHODS:** Vicryl and PDS sutures were coated with 2% chitosan. While laparotomy was applied to the first group, chitosan was applied in the peritoneal cavity in the second group. Then the following materials were applied to colon anastomosis, in order: Vicryl, PDS, chitosan-coated Vicryl, and chitosan-coated PDS sutures. On the 7<sup>th</sup> and 14<sup>th</sup> days, eight rats from each group were euthanized.

**RESULTS:** The adhesion scores of chitosan and control groups were lower than the suture groups. The vascularization of Vicryl–chitosan was lower than PDS–chitosan on the 14<sup>th</sup> day ( $p=0.038$ ). Fibroblast cells and vascularization of anastomosis with chitosan-coated Vicryl were lower than Vicryl and chitosan-coated PDS on the 14<sup>th</sup> day ( $p<0.05$ ). The tensile strength of Vicryl–chitosan increased more than Vicryl *in vitro* ( $p<0.05$ ) on the 14<sup>th</sup> and 7<sup>th</sup> days, but there was no difference *in vivo*. The tensile strength of PDS–chitosan decreased more than PDS on the 7<sup>th</sup> day *in vivo* ( $p<0.05$ ).

**CONCLUSION:** The chitosan-coating effect on the adhesion and reinforcement of anastomosis in some parts of Vicryl *in vitro* and PDS *in vivo* was slightly improved.

**Keywords:** Anastomosis; chitosan; PDS suture; tensile strength; Vicryl suture; wound healing.

## INTRODUCTION

Leakage from colonic anastomosis is caused by multiple factors and results in morbidity and mortality.<sup>[1]</sup> Anastomotic leakage following colorectal resections occurs in 3%–23% of cases.<sup>[2]</sup> For various reasons, this anastomotic dehiscence is a major problem for anastomotic healing. To reduce this complication, reinforcement of the anastomosis by biological or artificial materials has been tried. Of primary importance are the types of suture materials used for the primary closure of tissues separated by surgical procedures. Numerous sutures with different mechanical properties are used in surgical pro-

cedures, which lead to tensile loading. There has been little research on the changes in the mechanical properties of surgical sutures in experimental conditions.<sup>[3,4]</sup>

Peritoneal adhesion formation resulting from tissue ischemia, inflammation, fibrin organization, and collagen formation following abdominal surgeries remains a major problem.<sup>[5,6]</sup> From various agents that have been used to reduce each of these steps,<sup>[5,6]</sup> we aimed to investigate chitosan for intra-abdominal inflammatory processes, including adhesion formation and anastomosis strength.

Cite this article as: Altinel Y, Chung SS, Okay G, Uğraş N, Işık AF, Öztürk E, et al. Effect of chitosan coating on surgical sutures to strengthen the colonic anastomosis. *Ulus Travma Acil Cerrahi Derg* 2018;24:405-411.

Address for correspondence: Yüksel Altinel, M.D.

Harvard Medical School Boston, United States

Tel: +18622834536 E-mail: yuksel\_altinel@hms.harvard.edu



*Ulus Travma Acil Cerrahi Derg* 2018;24(5):405-411 DOI: 10.5505/tjtes.2018.59280 Submitted: 30.11.2017 Accepted: 11.03.2018 Online: 10.09.2018

Copyright 2018 Turkish Association of Trauma and Emergency Surgery

The alkaline deacetylation of chitin obtained from the exoskeleton of crustaceans generates a natural polymer called chitosan. Immunological, antibacterial, wound-healing activity, biodegradability, and hemostatic potential are among the biological properties affected by chitosan.<sup>[7,8]</sup> We hypothesized that the use of chitosan to suture materials could decrease the dehiscence of colon anastomosis, leakage, and adhesion by preventing inflammation.

Using the multifilament suture Vicryl™ (Ethicon, Somerville NJ) and the monofilament suture PDSTM (Ethicon, Somerville NJ), we compared the effectiveness of chitosan-coated sutures with that of non-chitosan-coated sutures *in vivo* and *in vitro*. Furthermore, this study measured the effect of chitosan on the tensile strength of different sutures. In this experimental model, we also investigated the effect of chitosan coating on adhesion formation and inflammatory responses.

## MATERIALS AND METHODS

This study was approved by the Medical Faculty of Uludag University, Experimental Animals Production and Research Laboratory Ethical Committee (2010/05/02). The protocols were in compliance with the Declaration of Helsinki.

Ninety-six adult female Wistar albino rats (aged 3 or 4 months, weighing between 250 and 300 g) were used. The animals were kept in standard rat cages, with a maximum of four animals per cage, under standard laboratory conditions with pellet food, specifically manufactured for rats and water supplied using a drinking bottle. They were housed at a temperature of 20°C–22°C, with a relative humidity of 50%–60% and 12-h light–dark cycles. Rats were randomly put into six groups, of 16 rats each, and were further divided into groups of eight rats for evaluation on the 7<sup>th</sup> and 14<sup>th</sup> days to compare outcomes.

### Experimental Groups

**Group 1:** The control group; only laparotomy was performed on 16 rats. Then, eight rats from each group were sacrificed on the 7<sup>th</sup> and 14<sup>th</sup> days.

**Group 2:** The chitosan group; only 100 mg of chitosan powder was applied into the peritoneal cavity over the distal part of the cecum following dry gauze repeatedly rubbed to cause sub-serosal bleeding in 16 rats. Then, eight rats from each group were sacrificed on the 7<sup>th</sup> and 14<sup>th</sup> days.

**Group 3:** The Vicryl suture was used to perform a colon anastomosis after cecal enterotomy on 16 rats. Then, eight rats from each group were sacrificed on the 7<sup>th</sup> and 14<sup>th</sup> days.

**Group 4:** The 5/0 PDS suture was used to perform a colon anastomosis after cecal enterotomy on 16 rats. After that eight rats for each group were sacrificed on the 7<sup>th</sup> and 14<sup>th</sup> days.

**Group 5:** The chitosan-coated 5/0 Vicryl sutures were used to perform a colon anastomosis after cecal enterotomy on 16 rats. Then, eight rats from each group were sacrificed on the 7<sup>th</sup> and 14<sup>th</sup> days.

**Group 6:** The chitosan-coated 5/0 PDS sutures were used to perform a colon anastomosis after cecal enterotomy on 16 rats. Then, eight rats from each group were sacrificed on the 7<sup>th</sup> and 14<sup>th</sup> days.

### The Chitosan-Coating Procedure

The chitosan (Sigma, MO, USA) powder was added to a 1% (1 ml acetic acid, 99 ml water) acetic acid (100%, Merck, Germany) solution to prepare a 2% (2 g chitosan, 98 g acetic acid solution) chitosan solution. Then, 5/0 PDS and 5/0 Vicryl sutures were placed into the 2% chitosan solution and incubated for 30 min. The sutures were then warmed at 30°C in an oven in a textile engineering laboratory. Sterilization of the sutures was performed later.

### Surgical Procedures

All animals were fasted overnight before surgery. Anesthesia was maintained with an injection of 10 mg/kg intramuscular ketamine (Ketalar, Phizer, AUSTR) and 1 mL/kg xylazine (Rompun, Bayer, Germany).

An 8-cm midline incision was made on the abdomen after antisepsis by povidone iodine application. Segments of colon approximately 2 cm distal to the cecum were identified and partially transected, following which continuity was restored by anastomosis using a single layer of continuous 5/0 Vicryl or 5/0 PDS sutures.

Moreover, we only performed laparotomy in the control group. The laparotomy closure was performed via a continuous suture technique using 000 polypropylene (Prolene, Ethicon Inc., Somerville, NJ, USA). The skin was closed using a surgical stapler.

On the 7<sup>th</sup> postoperative day, eight randomly chosen rats from each group were sacrificed by cervical dislocation. The others were sacrificed on the 14<sup>th</sup> day. Through the initial laparotomy scar, the abdomen was opened in a cranial-to-caudal manner by midline incision in order to view the exact intra-abdominal adhesion formations. In the suture groups, anastomotic segments, including the anastomosis in the middle surrounding colon tissue, and adhesions of approximately 6×3 cm were carefully resected. In the chitosan group, the damaged cecum area was excised. The specimens were washed in saline, and stool was removed from the lumen. The anastomotic tissue around sutures a 4×3 cm wide strips was taken for the tensile strength of sutures, and a 2×1 cm tissue of anastomosis was taken for histopathological evaluation.

**Table 1.** Adhesion grading according to Diamond classification

Score	Extent	Tenacity	Type
0	0%	None	None
1	<25%	Easily lysed	Filmy, no vessels
2	25–50%	Lysed with traction	Opaque, no vessels
3	50–75%	Required sharp dissection	Opaque, small vessels
4	>75%		Opaque, large vessels

**Table 2.** Histologic grading scale for inflammatory cell infiltration, blood vessel and fibroblast ingrowth and collagen deposition

0	No evidence
1	Occasional evidence
2	Light scattering
3	Abundant evidence
4	Confluent cells or fibers

### Evaluation of Adhesion Formation

The adhesions were graded according to the Diamond classification by a general surgeon who had no knowledge about each rat's groups (Table 1).<sup>[9]</sup>

### Histological Evaluation

A pathologist blinded to the methods and groups examined all the specimens. Through this examination, efficacy of the interaction among the chitosan, sutures, and cecum could be observed. The tissues were fixed in a 10% buffered formaldehyde solution. The tissues were then embedded in paraffin following dehydration. The 5-µm thick sections were stained with hematoxylin and eosin and then evaluated by light microscopy at a magnification of 200×. The histopathological grading was performed with a modified Ehrlich and Hunt numerical scale (Table 2).<sup>[10]</sup>

### In Vivo and In Vitro evaluation of Sutures' Tensile Strength

The anastomotic site surrounding the sutures was resected as a 4×3-cm wide strip for tensile strength. The sutures were then separated from the tissue for *in vivo* measurements. Also, Vicryl and PDS sutures were put into serum for *in vitro* measurements until the 7<sup>th</sup> and 14<sup>th</sup> days.

The tests were evaluated in an Instron (Norwood, MA, USA) 4,301 instrument at room temperature, 21°C. The force employed was 5 kN/min. This action was established in the longitudinal direction in order to maintain the maximum strength at disruption.<sup>[5]</sup>

### Statistical Analysis

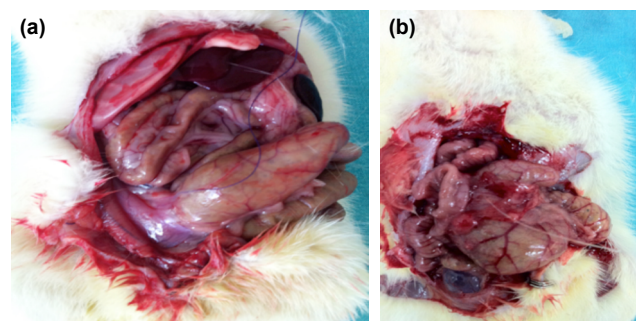
The adhesion, tensile strength, and histopathological scores were compared with Kruskal–Wallis test and Mann–Whitney U-test for intergroup comparisons to evaluate the data. The results were showed as median (minimum–maximum). SPSS 23.0 software (Chicago, IL, USA) was used. A p value <0.05 on a 2-tailed test was considered statistically significant.

### RESULTS

One rat each from Vicryl and Vicryl–chitosan-coated groups and two from PDS group died after the intervention for unidentified reasons. Throughout the investigation, no infections or anastomosis leakage were found. Additionally, the differences in weight and diameter of the sutures were not determined statistically significant.

### Adhesion Score (Fig. 1a, b)

The adhesion score groups were listed in Table 3. When the adhesion scores on the 7<sup>th</sup> and 14<sup>th</sup> days were evaluated, a significant difference between the suture groups was not identified (p>0.05). The adhesion score of Vicryl and PDS groups were higher than the chitosan and control groups when comparing each on the 7<sup>th</sup> day (p<0.05). Also, there was no significant difference between the chitosan and control groups. Even though the adhesion score of the chitosan and control groups was lower than suture groups, the PDS group adhesion score was statistically higher than chitosan on the 14<sup>th</sup> day (p<0.05). In addition, clinically the adhesion scores of chitosan-coated Vicryl and PDS groups observed a minimal decrease at the 14<sup>th</sup> day compared with the 7<sup>th</sup> day.



**Figure 1.** The intra-abdominal adhesion of (a) the Vicryl suture and (b) PDS suture.

**Table 3.** The scores of adhesions

	Control	Chitosan	Vicryl	Polydioxanone	Vicryl Chitosan	Polydioxanone Chitosan	p*
7 <sup>th</sup>	0 (0–1)	0 (0–1)	2.5 (1–3)	2 (1–3)	1 (0–2)	1.5 (0–2)	<0.001*
14 <sup>th</sup>	1 (0–1)	0 (0–1)	1 (1–2)	2 (1–3)	0.5 (0–2)	1 (0–2)	0.012*
p	0.234	1	0.094	0.383	0.281	0.279	

\*Statistically significant.

**Table 4.** Comparison of 7<sup>th</sup> and 14<sup>th</sup> day histopathological values of groups

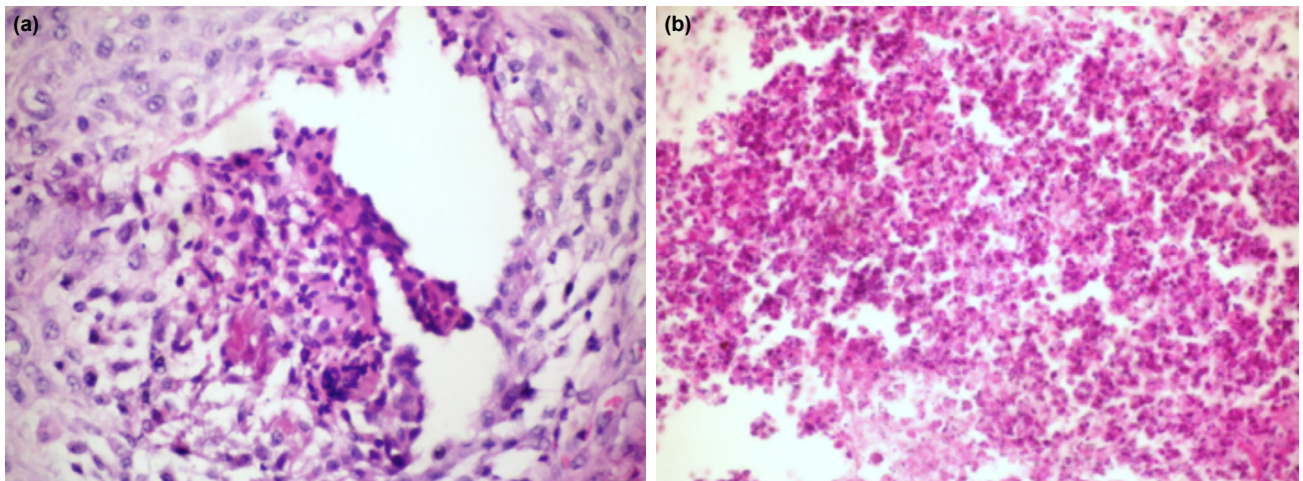
		Chitosan	Vicryl	Polydioxanone	Vicryl Chitosan	Polydioxanone Chitosan	p
Inflammatory cell	7 <sup>th</sup> day	1.25 (1–2)	3 (2–3)	3 (2–3)	2 (2–3)	3 (3–3)	<0.001*
	14 <sup>th</sup> day	1.5 (1–3)	3 (2–3)	3 (2–3)	2.5 (2–3)	3 (2–3)	0.011*
	p	0.645	0.779	1	0.867	0.234	
Fibroblast	7 <sup>th</sup> day	0.87 (0–2)	2 (1–3)	2 (0–3)	1 (0–2)	2 (1–2)	0.019*
	14 <sup>th</sup> day	0.87 (0–2)	2 (2–3)	2 (2–2)	1 (1–2)	2 (1–2)	<0.001*
	p	1	0.281	0.383	0.867	0.442	
Neovascularization	7 <sup>th</sup> day	0.75 (0–2)	2 (1–2)	2 (1–3)	1 (0–2)	2 (1–2)	0.010*
	14 <sup>th</sup> day	1.75 (1–3)	2 (2–3)	2 (1–2)	1 (1–2)	2 (2–2)	0.013*
	p	0.5	0.072	0.71	0.613	0.234	
Collagen	7 <sup>th</sup> day	0.75 (0–2)	0.5 (0–1)	1 (0–2)	0 (0–0)	3 (0–3)	0.009*
	14 <sup>th</sup> day	1.125 (0–2)	1 (0–1)	0 (0–1)	0 (0–1)	0 (0–1)	0.025*
	p	0.328	0.867	0.318	0.463	0.442	

\*Statistically significant.

### Histopathology (Fig. 2a, b)

The histopathological evaluation was shown in Table 4. The fibroblast cell accumulation and vascularization on the 14<sup>th</sup> day in the Vicryl–chitosan group were significantly lower than those in the Vicryl group ( $p=0.009$ ) compared with the other suture groups. Additionally, the vascularization of the Vicryl–chitosan group was observed significantly lower than

the PDS–chitosan group on the 14<sup>th</sup> day ( $p=0.038$ ). However, there wasn't any statistical difference between suture groups on the 7<sup>th</sup> day among inflammatory changes ( $p>0.05$ ). Histopathologically, no statistically significant difference was observed between suture groups of anastomosis for inflammatory cell and collagen accumulation ( $p>0.05$ ). However, the chitosan group had a lower amount of neovascularization,



**Figure 2.** The inflammatory cell infiltration of (a) the Vicryl suture (H&E 10) and (b) PDS suture (H&E 10).

**Table 5.** The tensile strength of sutures (MPa) as median (min–max) value

		7 <sup>th</sup>	14 <sup>th</sup>	p
Vicryl	<i>In vivo</i>	0.0214 (0.019–0.0256)	0.0165 (0.0159–0.0172)	<0.001*
	<i>In vitro</i>	0.0184 (0.0183–0.0188)	0.0017 (0.0016–0.0018)	<0.001*
	P	0.012*	0.018*	
Polydioxanone	<i>In vivo</i>	0.0195 (0.0176–0.0202)	0.0177 (0.0162–0.0188)	0.007*
	<i>In vitro</i>	0.0256 (0.0251–0.0262)	0.0025 (0.0024–0.0026)	0.001*
	P	0.018*	0.018*	
Vicryl Chitosan	<i>In vivo</i>	0.0194 (0.0161–0.0249)	0.01535 (0.0125–0.0208)	0.021*
	<i>In vitro</i>	0.0246 (0.0231–0.0261)	0.02465 (0.0236–0.0257)	0.694
	P	0.028*	0.012*	
Polydioxanone Chitosan	<i>In vivo</i>	0.017 (0.0156–0.0176)	0.016 (0.0149–0.0174)	0.161
	<i>In vitro</i>	0.0252 (0.025–0.0254)	0.0023 (0.002–0.0025)	<0.001*
	P	0.012*	0.012*	
p		<0.05*	<0.05*	

\*Statistically significant.

fibroblast, and inflammatory cell accumulation and higher amount of collagen accumulation than the suture groups on the 7<sup>th</sup> and 14<sup>th</sup> days ( $p < 0.05$ ). It was evident that the chitosan had an influence over the Vicryl suture causing minimal decrease among fibroblast, inflammatory cell and collagen accumulation including vascularization on the 14<sup>th</sup> day. However, no histopathological major change was observed among the chitosan effect on the PDS suture on the 14<sup>th</sup> day ( $p > 0.05$ ).

### **In Vivo and In Vitro Evaluation of Sutures' Tensile Strength**

The tensile strength data for these groups were arranged in Table 5.

The tensile strength of Vicryl was statistically lower than PDS *in vivo* and *in vitro* on the 14<sup>th</sup> day and the 7<sup>th</sup> day ( $p < 0.05$ ). The tensile strength of the PDS's 14<sup>th</sup> day was lower than PDS's 7<sup>th</sup> day, *in vivo* ( $p = 0.007$ ) and *in vitro* ( $p = 0.001$ ). The tensile strength of Vicryl's 14<sup>th</sup> day was lower than Vicryl's 7<sup>th</sup> day, *in vivo* and *in vitro* ( $p < 0.001$ ).

The chitosan decreased the tensile strength of PDS after coating *in vivo* and *in vitro* on the 7<sup>th</sup> and 14<sup>th</sup> days. Even if the tensile strength of PDS–chitosan decreased *in vitro* more than PDS on 7<sup>th</sup> day, statistically significant decline was seen *in vivo* ( $p < 0.05$ ). However, the tensile strength of PDS–chitosan decreased more on the 14<sup>th</sup> day than on the 7<sup>th</sup> day *in vivo* ( $p = 0.161$ ); hence, a significant decline was seen *in vitro* ( $p < 0.001$ ).

The chitosan decreased the tensile strength of Vicryl after coating *in vivo* but increased the tensile strength of Vicryl after coating *in vitro* on the 7<sup>th</sup> and 14<sup>th</sup> days. The tensile strength of Vicryl–chitosan on the 14<sup>th</sup> day had significantly

decreased *in vivo* ( $p = 0.021$ ) more than the 7<sup>th</sup> day, but there was no statistical difference *in vitro* ( $p = 0.694$ ). The tensile strength of Vicryl–chitosan had significantly increased *in vitro* ( $p < 0.05$ ) more than Vicryl on the 14<sup>th</sup> and 7<sup>th</sup> days, but there was no statistical difference *in vivo*. The tensile strength of Vicryl–chitosan had decreased *in vitro* more than PDS–chitosan's on the 7<sup>th</sup> day, but Vicryl–chitosan was statistically more than PDS–chitosan's tensile strength *in vivo* ( $p = 0.09$ ) on the 7<sup>th</sup> day. Vicryl–chitosan had significantly increased *in vitro* ( $p < 0.05$ ) more than PDS–chitosan's tensile strength on the 14<sup>th</sup> day, but there were no significant differences *in vivo*.

### **DISCUSSION**

The chitosan coating on multifilament sutures such as Vicryl™ (Ethicon, Somerville NJ) and monofilament PDSTM (Ethicon, Somerville NJ) was evaluated according to adhesion formation, histopathology, and tensile strength. In our experimental model, the coating of sutures with chitosan provided clinically beneficial effects to intra-abdominal adhesion formation. Moreover, when we respectively considered the evaluation of tensile strength *in vivo* and *in vitro*, we realized that there are some different interactions between the biocompatibility of sutures.

Chitosan has an essential effect on the inhibition of fibroblast migration and the reduction of collagen deposition at the surgical site.<sup>[11–13]</sup> The modified chitosan films such as 100% chitosan film, forms containing 10% or 50% gelatin, N, O-carboxymethyl chitosan gel and NOCC 2% solution forms were used in some of the experimental models. The modified chitosan film and gelatin forms have an effect on preventing peritoneal adhesions.<sup>[14–16]</sup> *In vivo* and *in vitro* the intestine tissue was repaired by laser-activated chitosan adhesive for achiev-

ing the repair strength.<sup>[17]</sup> Furthermore, one of the features of chitosan is its hemostatic potential to prevent postoperative intra-abdominal bleeding which is a stimulus for adhesion.<sup>[8]</sup> However, similar to the study of the chitosan coating over meshes,<sup>[5]</sup> we did not observe any statistically significant decrease in peritoneal adhesion formation after the application of a chitosan on the sutures when compared to the uncoated forms. We can only mention that the beneficial influence of chitosan clinically observed during one of the inflammatory processes of adhesion formation had a collaborative effect on anastomosis strength.

In addition to that, there was not enough statistically significant difference between suture groups related to anastomosis for inflammatory cell and collagen accumulation in our study. The vascularization of Vicryl–chitosan group was observed to be significantly less than Vicryl and PDS–chitosan. In addition, the fibroblast cell accumulation of Vicryl–chitosan group is significantly less than Vicryl on the 14<sup>th</sup> day. Due to this, a correlation could be made that the tensile strength of chitosan-coated Vicryl might be decreased *in vivo*. Our results could be due to the interaction of the chitosan coating and the property of multifilament VicrylTM. The fibroblast cell accumulation associated with inflammation promotes the adhesion formation and fibrosis involving collagen accumulation.<sup>[7,18]</sup> The adhesion score was lower in the chitosan group, although the suture groups were not strongly affected by the chitosan coating. However, it was estimated that the insufficient determination of the pathological results for anastomosis strength could be dependent on the amount of chitosan, the technique of coating or the type of suture material.

Moreover, there are many different biological and artificial materials for the prevention of anastomotic leakage and the reinforcing of anastomosis by covering it, like Bio-Gide, grafts, meshes,<sup>[2]</sup> which have been investigated. In addition, the bio-sutures like the mesenchymal stem cell-coated suture,<sup>[19]</sup> albumin-coated bioactive suture,<sup>[20]</sup> IGF-I-coated sutures,<sup>[21]</sup> protein-coated sutures<sup>[22]</sup> were used in various types of wound-healing processes. Some treatment effects of the resveratrol, gentamicin, fibrin glue, and butyrate on the healing of colonic anastomosis were performed in the studies.<sup>[1,23]</sup> In our experiment, we evaluated the multifilament and monofilament sutures by coating with chitosan to encourage the cellular adhesion via inflammatory processes for reinforcing the anastomosis.

On the other hand, the weakest but main difference of our study compared with others is related to the evaluation of the bursting pressure of anastomosis.<sup>[24]</sup> The lack of proof by one of the measurements is the bursting pressure of the anastomotic strength.<sup>[25]</sup> When we investigated the breaking strength of anastomosis, we determined the tensile strength of sutures by evaluating the tensile strength of sutures *in vivo* and *in vitro*. We observed that chitosan interaction was more evident at chitosan-coated Vicryl *in vitro* and chitosan-

coated PDS *in vivo*. Although there were few different examples of chitosan biocompatibility or Nano-technics including electrospinning and new approaches to the development of suture materials.<sup>[26,27]</sup> According to recent experiments, as we observed, the newly developed suture coating process concludes as a promising method for obtaining a beneficial antibacterial effect. Similarly, to our study, it appears that the coating slightly improved the tensile strength of the sutures after the application of natural coatings on non-absorbable sutures.<sup>[28,29]</sup>

Consequently, the results of our experiment did partially support our hypothesis. The chitosan coating over the sutures ameliorates the adhesion scores, the tensile strength, or the histopathological criteria in some parts over the reinforcement of anastomosis. The chitosan coating on the adhesion potential has shown clinically beneficial effects compared to statistical results. In addition, the chitosan improved the reinforcement of anastomosis in some parts of Vicryl *in vitro* and PDS *in vivo*. It is obvious that further investigations are required for the definitive clinical usage with new technical approaches for the chitosan-coated sutures among the anastomosis reinforcement. Moreover, there will be new challenges to create different suture properties.

## Acknowledgments

This study was presented as a poster at the ESCP 8<sup>th</sup> Scientific and Annual Meeting, 25–27 September 2013, Belgrade.

Conflict of interest: None declared.

## REFERENCES

1. Subhas G, Bhullar JS, Cook J, Shah A, Silberberg B, Andrus L, et al. Topical gentamicin does not provide any additional anastomotic strength when combined with fibrin glue. *Am J Surg* 2011;201:339–43.
2. Hoepfner J, Willa K, Timme S, Tittelbach-Helmrich D, Hopt UT, Keck T, et al. Reinforcement of colonic anastomoses with a collagenous double-layer matrix extracted from porcine dermis. *Eur Surg Res* 2010;45:68–76. [CrossRef]
3. Kim JC, Lee YK, Lim BS, Rhee SH, Yang HC. Comparison of tensile and knot security properties of surgical sutures. *J Mater Sci Mater Med* 2007;18:2363–9. [CrossRef]
4. Hernandez KA, Hooper RC, Boyko T, Golas AR, van Harten M, Wu DQ, et al. Reduction of suture associated inflammation after 28 days using novel biocompatible pseudoprotein poly(ester amide) biomaterials. *J Biomed Mater Res B Appl Biomater* 2015;103:457–63. [CrossRef]
5. Altinel Y, Öztürk E, Özkaya G, Akyıldız EÜ, Ulcay Y, Özgüç H. The effect of a chitosan coating on the adhesive potential and tensile strength of polypropylene meshes. *Hernia* 2012;16:709–14. [CrossRef]
6. Altinel Y, Taşpınar E, Özgüç H, Öztürk E, Ulker Akyıldız E, Bağdaş D. The protective effect of ClinOleic against post-surgical adhesions. *Ulus Travma Acil Cerrahi Derg* 2014;20:1–6. [CrossRef]
7. Gómez-Estaca J, López de Lacey A, López-Caballero ME, Gómez-Guilén MC, Montero P. Biodegradable gelatin-chitosan films incorporated with essential oils as antimicrobial agents for fish preservation. *Food Microbiol* 2010;27:889–96. [CrossRef]
8. Ong SY, Wu J, Mochhala SM, Tan MH, Lu J. Development of a chi-

- tosan-based wound dressing with improved hemostatic and antimicrobial properties. *J Biomaterials* 2008;29:4323–32. [CrossRef]
9. Schneider A, Bennek J, Olsen K. Experimental study evaluating the effect of a barrier method on postoperative intraabdominal adhesions. *Dig Dis Sci* 2006;51:566–70. [CrossRef]
  10. Phillips JD, Kim CS, Folkalsrud EW. Effects of chronic corticosteroids and vitamin A on the healing of intestinal anastomoses. *Am J Surg* 1992;163:71–7. [CrossRef]
  11. Zhou J, Elson C, Le TD. Reduction in postoperative adhesion formation and re-formation after an abdominal operation with the use of N, O - carboxymethyl chitosan. *J Surg* 2004;135:307–12.
  12. Risbud M, Hardikar A, Bhone R. Growth modulation of fibroblasts by chitosan-polyvinyl pyrrolidone hydrogel: implications for wound management? *J Biosci* 2000;25:25–31. [CrossRef]
  13. van der Wal JB, Jeekel J. Biology of the peritoneum in normal homeostasis and after surgical trauma. *Colorectal Dis* 2007;9:9–13. [CrossRef]
  14. Zhang Z, Xu S, Zhou XL. Preventive effects of chitosan on peritoneal adhesion in rats. *W J Gastroenterol* 2006; 28:4572–77.
  15. Zhou X, Chen S, Liao G, Shen ZJ, Zhang ZL, Sun L, et al. Preventive effect of gelatinized-modified chitosan film on peritoneal adhesion of different types. *World J Gastroenterol* 2007;13:1262–67. [CrossRef]
  16. Costain DJ, Kennedy R, Ciona C, McAlister VC, Lee TD. Prevention of postsurgical adhesions with N,O-carboxymethyl chitosan: examination of the most efficacious preparation and the effect of N,O-carboxymethyl chitosan on postsurgical healing. *J Surg* 1997;121:314–19.
  17. Lauto A, Stoodley M, Marcel H, Avolio A, Sarris M, McKenzie G, et al. In vitro and in vivo tissue repair with laser-activated chitosan adhesive. *Lasers Surg Med* 2007;39:19–27. [CrossRef]
  18. Bachman S, Ramshaw B. Prosthetic material in ventral hernia repair: how do I choose? *Surg Clin N Am* 2008;88:101–12. [CrossRef]
  19. Pascual I, Fernández de Miguel G, García Arranz M, García-Olmo D. Biosutures improve healing of experimental weak colonic anastomoses. *Int J Colorectal Dis* 2010;25:1447–51. [CrossRef]
  20. Horváthy DB, Vác G, Cselenyák A, Weszl M, Kiss L, Lacza Z. Albumin-coated bioactive suture for cell transplantation. *Surg Innov* 2013;20:249–55. [CrossRef]
  21. Rijcken E, Fuchs T, Sachs L, Kersting CM, Bruewer M, Krieglstein CF. Insulin-like growth factor 1-coated sutures improve anastomotic healing in an experimental model of colitis. *Br J Surg* 2010;97:258–65. [CrossRef]
  22. Mazzocca AD, McCarthy MB, Arciero C, Jhaveri A, Obopilwe E, Rincon L, et al. Tendon and bone responses to a collagen-coated suture material. *J Shoulder Elbow Surg* 2007;16:222–30. [CrossRef]
  23. Cakmak GK, Irkorucu O, Ucan BH, Tascilar O, Emre AU, Karakaya K, et al. The effects of resveratrol on the healing of left colonic anastomosis. *J Invest Surg* 2009;22:353–61. [CrossRef]
  24. Månsson P, Zhang XW, Jeppsson B, Thorlacius H. Anastomotic healing in the rat colon: comparison between a radiological method, breaking strength and bursting pressure. *Int J Colorectal Disease* 2002;17:420–5. [CrossRef]
  25. Posma LA, Bleichrodt RP, Lomme RM, de Man BM, van Goor H, Hendriks T. Early anastomotic repair in the rat intestine is affected by transient preoperative mesenteric ischemia. *J Gastrointest Surg* 2009;13:1099–106. [CrossRef]
  26. Sanders D, Lambie J, Bond P, Moate R, Steer JA. An in vitro study assessing the effect of mesh morphology and suture fixation on bacterial adherence. *Hernia* 2013;17:779–89. [CrossRef]
  27. Norowski PA, Mishra S, Adatrow PC, Haggard WO, Bumgardner JD. Suture pullout strength and in vitro fibroblast and RAW 264.7 monocyte biocompatibility of genipin crosslinked nanofibrous chitosan mats for guided tissue regeneration. *J Biomed Mater Res A* 2012;100:2890–6.
  28. Debbabi F, Gargoubi S, Hadj Ayed MA, Abdessalem SB. Development and characterization of antibacterial braided polyamide suture coated with chitosan-citric acid biopolymer. *J Biomater Appl* 2017;32:384–98.
  29. Masood R, Hussain T, Umar M, Azeemullah, Areeb T, Riaz S. In situ development and application of natural coatings on non-absorbable sutures to reduce incision site infections. *J Wound Care* 2017;26:115–20.

## DENEYSSEL ÇALIŞMA - ÖZET

### Kitosan kaplı ipliklerin anastomoz gücü artırma üzerine etkisi

Dr. Yüksel Altinel,<sup>1</sup> Dr. Soon Soup Chung,<sup>2</sup> Dr. Güven Okay,<sup>3</sup> Dr. Nesrin Uğraş,<sup>4</sup> Dr. Ahmet Fatih Işık,<sup>5</sup> Dr. Ersin Öztürk,<sup>1</sup> Dr. Halil Özgüç<sup>1</sup>

<sup>1</sup>Uludağ Üniversitesi Tıp Fakültesi, Genel Cerrahi Anabilim Dalı, Bursa

<sup>2</sup>Ewha Üniversitesi Hastanesi, Genel Cerrahi Anabilim Dalı, Seul-Kore

<sup>3</sup>Uludağ Üniversitesi Tıp Fakültesi, Biostatistics Anabilim Dalı, Bursa

<sup>4</sup>Uludağ Üniversitesi Tıp Fakültesi, Patoloji Anabilim Dalı, Bursa

<sup>5</sup>Uludağ Üniversitesi Tekstil Mühendisliği Fakültesi, Tekstil Anabilim Dalı, Bursa

**AMAÇ:** Yara iyileşmesi etkisiyle, kitosan kaplı ipliklerin bağırsak anastomozu gücü üzerine uygulanabilir olmasını araştırdık.

**GEREÇ VE YÖNTEM:** Vikril ve PDS iplikler %2 kitosanla kaplandı. Laparotomi birinci gruba uygulanırken, kitosan ikinci grupta periton boşluğuna uygulandı. Takibinde sırasıyla vikril, PDS, kitosan kaplı vikril ve kitosan kaplı PDS iplikler kolon anastomozunda kullanıldı. Yedinci ve 14. günlerde her gruptan sekiz sıçan sakrifiye edilerek inceleme yapıldı.

**BULGULAR:** Kitosan ve kontrol grubunun adezyon değeri iplik gruplarına göre anlamlı olarak daha düşük saptandı (p<0.05). Kitosan kaplı vikril grubunun 14. günde vaskülarizasyon değeri, kitosan kaplı PDS iplik grubuna göre anlamlı olarak daha az olduğu belirlendi (p=0.038). Kitosan kaplı vikrilin 14. gününde, anastomoz vaskülarizasyonu ve fibroblast hücreleri üzerinde vikril ve kitosan kaplı PDS göre etkisi daha düşük bulundu (p<0.05). Kitosan kaplı vikrilin 14. ve yedinci günündeki in vitro mukavemet gücü vikrilden daha yüksek olmasına rağmen (p<0.05), in vivo farklılık görülmedi. The PDS-kitosan'ın mukavemet gücü in vivo yedinci günde, PDS'den daha az olarak saptandı (p<0.05).

**TARTIŞMA:** Kitosan ile kaplama, anastomoz gücünü ve adezyon etkisini hafif oranda in vitro vikril ve in vivo PDS üzerinde arttırdı.

**Anahtar sözcükler:** Anastomoz; kitosan; mukavemet gücü, PDS ve Vicryl iplikler; yara iyileşmesi.

Ulus Travma Acil Cerrahi Derg 2018;24(5):405-411 doi: 10.5505/tjtes.2018.59280