

An unusual entry site for a nasal foreign body: a neglected trauma patient

Selçuk Mülazımoğlu, M.D., Emre Ocak, M.D., Süha Beton, M.D., Ozan Bağış Özgürsoy, M.D.

Department of Otorinolaryngology Head and Neck Surgery, Ankara University Faculty of Medicine, Ankara

ABSTRACT

Foreign body (FB) in the nose is a frequent situation seen generally among children. A variety of objects left in different sites of the nose has been reported in the literature. Insertion of a FB to the nose is generally via the anterior nares. In this report, an unusual entry site for a nasal FB in a neglected trauma patient is presented. FB should be suspected and investigated in children after penetrating facial injury.

Key words: Maxillofacial trauma; nose; penetrating injury.

INTRODUCTION

Most otorhinolaryngologists do not give careful attention in the follow-up of foreign bodies (FBs) in the nose. FB in the nose is generally seen among young children. Many factors lead children to insert FBs into the upper aerodigestive system, including curiosity, frivolity, nasal itching or irritation caused by rhinitis or otalgia, and attraction to small, round objects, as shown in the literature.^[1] Studies show that the younger the child, the more frequent the insertion of FBs.^[2] The most common FBs are toys, nuts, beans, rubber erasers, grapes, and paper. Some typical anatomical sites of FBs include nasal entrance anterior to the middle turbinate and floor of the nasal cavity just below the inferior turbinate.^[3] However, one must visualize every anatomical location in the nasal cavity to avoid overlooking FBs.

We present a neglected case of FB in which the FB entered the nasal cavity after external trauma to the face and went unnoticed for four years.

CASE REPORT

An 11-year-old female patient complaining of a foul nasal odor for about six months admitted to our outpatient clinic. She had a trauma history in which she fell onto a plastic pen four years ago, and as the patient described, the pen lodged in her right nasolabial skin and was removed immediately. After being taken to an emergency department, the skin laceration at the nasolabial sulcus was sutured. She complained about odorous nasal discharge and admitted to an otorhinolaryngologist four years after the trauma. A paranasal computerized tomography showed a FB in the right nasal cavity penetrating through the middle concha and septum (Fig. 1). Afterwards, the patient was referred to our clinic for the removal of the FB. The physical examination revealed a 2 cm scar on the right nasolabial sulcus (Fig. 2). Nasal endoscopy under topical anesthesia showed a cylindrical FB in the right nasal cavity lateral to the middle concha (Fig. 3). The middle concha was retracted medially and the FB, a plastic pen cap, was removed using a Blakesley nasal forceps (Fig. 4). Nasal irrigation and antibiotics were given, and no infection or purulent discharge was seen in the follow-up.

DISCUSSION

Nasal FB in children is a frequent situation in otorhinolaryngology practice. It can be presented with odorous nasal discharge, foul nasal odor, and pain or discomfort in the nose. However, some authors have reported that 63% of the cases may be asymptomatic.^[4] When a patient complains of long-standing, unilateral mucopurulent nasal discharge, one should suspect FB in the nasal cavity. The most common entry site for FBs is via the anterior nares, especially in young children.^[5]

Presented at the 9th Turkish Rhinology Congress (23-26 May 2013, Antalya, Turkey).

Address for correspondence: Selçuk Mülazımoğlu, M.D.
Ankara Üniversitesi Tıp Fakültesi, Kulak Burun Boğaz Hastalıkları
Anabilim Dalı, Sıhhiye, 06100 Ankara, Turkey
Tel: +90 312 - 508 20 30 E-mail: selcukmulazim@gmail.com

Quick Response Code



Ulus Travma Acil Cerrahi Derg
2014;20(3):221-223
doi: 10.5505/tjtes.2014.56805

Copyright 2014
TJTES

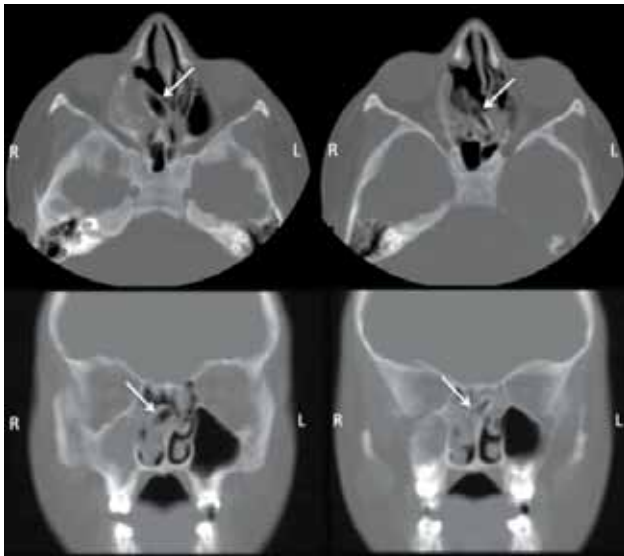


Figure 1. Paranasal computerized tomography showing the right nasal foreign body (arrow) penetrating through the middle concha and septum.

In this case, the FB had entered the nasal cavity transcutaneously, which is very unusual. Although there have been some cases with unusual sites of penetration, such as craniofacial trauma resulting from orbital foreign body,^[6] the entrance of the nasal FB described above remains unique.

Foltran et al.^[7] reviewed 1475 articles regarding FB in the airways over a period of 30 years, and noted that pen cap is not a common FB in the nose. Patients with nasal FBs usually admit to emergency departments for removal of their FBs. FBs can be removed either in the emergency service or otorhinolaryngology department. Although emergency practitioners

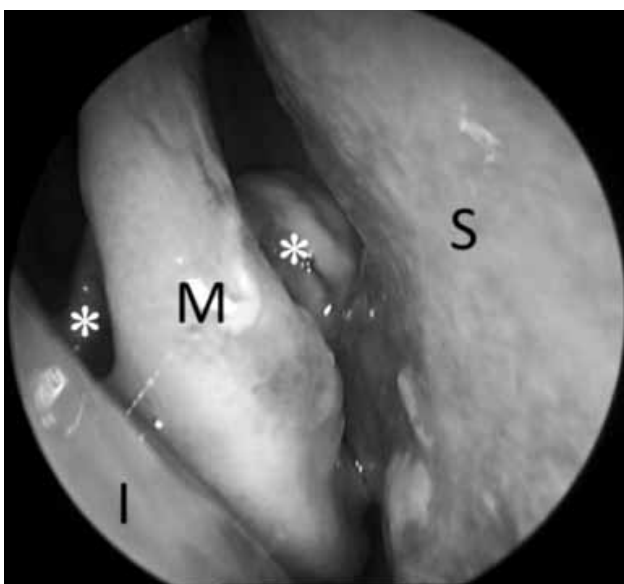


Figure 3. Endoscopic view of the right nasal foreign body (asterisk) penetrating through the middle concha (S: Septum, M: Middle concha, I: Inferior concha).

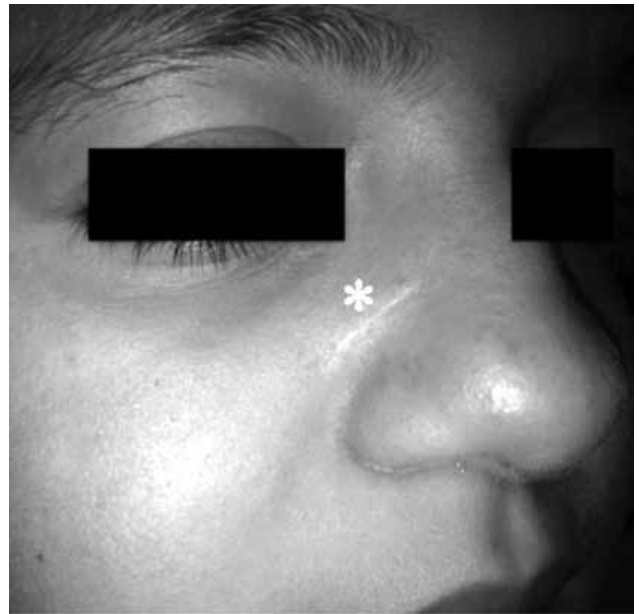

Figure 2. Traumatic scar on the right nasolabial sulcus (asterisk).

are familiar with the removal techniques, multiple attempts may be required for removal,^[8] and their failure rate can be as high as 35%.^[9] Some FBs are inert and may remain in the nose for years, but others can harm the nasal mucosa, leading to mucosal ulcerations, epistaxis and toxemia in some cases. Longstanding FBs in the nose also tend to become encrusted with calcified material and become a rhinolith.^[3] There are some cases in which the FB remained in the nasal cavity up to 40 years.^[10] These can cause nasomaxillary abnormalities in the growing child.

Nasal FBs should not be neglected and must be removed as soon as possible, preferably by an otorhinolaryngologist. After removal, one must visualize the entire nasal cavity, endoscopically if possible, to ensure no other pieces are left in the cavity. In a child with a penetrating injury to the face, one should suspect and investigate any hidden FB embedded in deep tissues, even in the nasal cavity. If the penetrating object is available, it should be examined to ascertain if any part is missing.

Conflict of interest: None declared.



Figure 4. Nasal foreign body after removal (plastic pen cap).

REFERENCES

1. Balbani AP, Sanchez TG, Butugan O, Kii MA, Angélico FV Jr, Ikino CM, et al. Ear and nose foreign body removal in children. *Int J Pediatr Otorhinolaryngol* 1998;46:37-42.
2. Das SK. Aetiological evaluation of foreign bodies in the ear and nose. *J Laryngol Otol* 1984;98:989-91.
3. Kalan A, Tariq M. Foreign bodies in the nasal cavities: a comprehensive review of the aetiology, diagnostic pointers, and therapeutic measures. *Postgrad Med J* 2000;76:484-7.
4. Kadish HA, Corneli HM. Removal of nasal foreign bodies in the pediatric population. *Am J Emerg Med* 1997;15:54-6.
5. Tay AB. Long-standing intranasal foreign body: an incidental finding on dental radiograph: a case report and literature review. *Oral Surg Oral Med Oral Pathol Oral Radiol Endod* 2000;90:546-9.
6. LaFrentz JR, Mair EA, Casler JD. Craniofacial ballpoint pen injury: endoscopic management. *Ann Otol Rhinol Laryngol* 2000;109:119-22.
7. Foltran F, Ballali S, Passali FM, Kern E, Morra B, Passali GC, et al. Foreign bodies in the airways: a meta-analysis of published papers. *Int J Pediatr Otorhinolaryngol* 2012;76 Suppl 1:12-9.
8. Chan TC, Ufberg J, Harrigan RA, Vilke GM. Nasal foreign body removal. *J Emerg Med* 2004;26:441-5.
9. Mackle T, Conlon B. Foreign bodies of the nose and ears in children. Should these be managed in the accident and emergency setting? *Int J Pediatr Otorhinolaryngol* 2006;70:425-8.
10. Uđur MB, Evren C, Corakçı S, Taş E, Cinar F. Foreign body which resembles concha bulloza in the middle meatus: a case report. *Kulak Burun Bogaz Ihtis Derg* 2009;19:307-10.

OLGU SUNUMU - ÖZET

Burunda yabancı cisimde sıradışı bir giriş yolu: İhmal edilmiş bir travma olgusu

Dr. Selçuk Mülazımođlu, Dr. Emre Ocak, Dr. Süha Beton, Dr. Ozan Bađış Özgürsoy

Ankara Üniversitesi Tıp Fakültesi, Kulak Burun Bođaz Hastalıkları Anabilim Dalı, Ankara

Burunda yabancı cisim özellikle çocuklarda sıkça karşılaşılan bir durumdur. Literatürde burunun deđişik bölgelerinde çok çeşitli yabancı cisim bildirilmiştir. Yabancı cisimin giriş yolu sıklıkla burun delikleridir. Bu yazıda, ihmal edilmiş bir travma hastasında, burunda yabancı cisim için sıradışı bir giriş yolu sunuldu. Çocuklarda penetran yüz yaralanması sonrasında yabancı cisimden şüphelenilmeli ve detaylı aranmalıdır.

Anahtar sözcükler: Burun; maksillofasial travma; penetran yaralanma.

IX. Türk Rinoloji Kongresi'nde sunulmuştur (23-26 Mayıs, Antalya, Türkiye).

Ulus Travma Acil Cerrahi Derg 2014;20(3):221-223 doi: 10.5505/tjtes.2014.56805