

Perforation of Meckel's diverticulum by a button battery: Report of two cases

Düğme pilin neden olduğu Meckel divertikülü perforasyonu: İki olgu sunumu

Bülent Hayri ÖZOKUTAN, Haluk CEYLAN, Sefa YAPICI, Sedat SIMSIK

Ingested button battery perforation of Meckel's diverticulum is extremely rare, with only two reported cases in the recent literature. Two additional preschool children who accidentally swallowed an alkaline button battery and developed a perforated Meckel's diverticulum are reported. Surgeons should be aware of this rare complication. Careful clinical, radiologic and laboratory monitoring of children who ingest a button battery is advisable.

Key Words: Button battery; foreign body; Meckel's diverticulum; perforation.

Yutulan düğme pilin neden olduğu Meckel divertikülü perforasyonu oldukça nadirdir ve literatürde günümüze kadar yalnızca iki olgu bildirilmiştir. Bu yazıda, okul öncesi çağıdaki iki çocukta kazayla yutulan düğme pilin yol açtığı Meckel divertikülü perforasyonu sunuldu. Düğme pil yutan çocuklarda gelişebilecek bu nadir komplikasyon akılda tutulmalı, olguların klinik, radyolojik ve laboratuvar bulguları dikkatle izlenmelidir.

Anahtar Sözcükler: Düğme pil; yabancı cisim; Meckel divertikülü; perforasyon.

Swallowed foreign bodies account for a significant number of emergency admissions of children.^[1] An ingested foreign body generally causes no morbidity.^[2] However, those that lodge in the gastrointestinal (GI) tract can cause significant complications.^[3] Perforation of a Meckel's diverticulum is a very rare complication of foreign body ingestion. A variety of foreign bodies, such as fish bones, needles and chicken bones, have been reported as causing perforation of a Meckel's diverticulum.^[4,5] Perforation of Meckel's diverticulum by a button battery is exceptional and, to the best of our knowledge, only two cases have been reported in the English-language literature.^[6,7] In this study, we report two further cases.

CASE REPORTS

Case 1– A 3-year-old boy who swallowed a button battery that he took out of from his toy three days before was brought to our emergency department. The child had first been admitted and observed in another pediatric surgery clinic for 2 nights. As the foreign

body had not changed its position on plain abdominal radiographs and the boy developed abdominal pain and vomiting, he was referred to our hospital for further management. On examination, he had lower abdominal tenderness. Laboratory data were normal except for leukocytosis of $15.8 \times 10^3/\mu\text{L}$. A plain abdominal radiograph showed the button battery in the lower abdomen, in the same position as on previous films; there was no evidence of free air (Fig. 1a). The abdomen was explored through a right lower quadrant incision, and this showed a perforated Meckel's diverticulum from the button battery approximately 50 cm distal to the ileocecal valve. The perforation site was adherent to the rectum and ileum. An additional ileal perforation was present where the Meckel's diverticulum was adherent to small bowel (Fig. 2a). The button battery was 10 mm in diameter and 3 mm in thickness and its envelope was intact. A segmental resection of the ileum including the Meckel's diverticulum and adjacent ileal perforation site was performed. The child made an uneventful recovery.

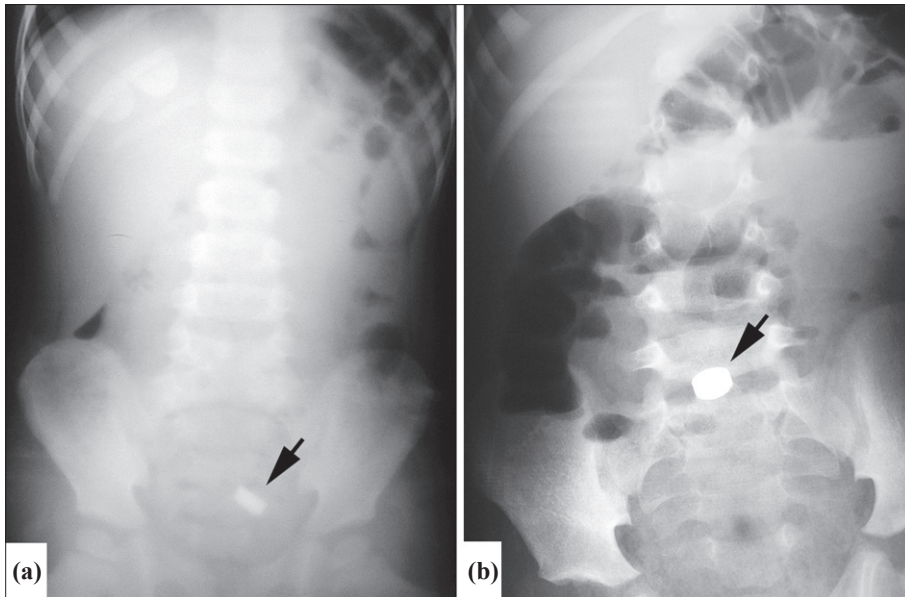


Fig. 1. (a) Case 1. The button battery is seen (arrow) in the pelvis on the plain abdominal radiograph; (b) Case 2. Radiograph showing the battery in the lower abdomen (arrow) and air-fluid levels throughout the abdomen.

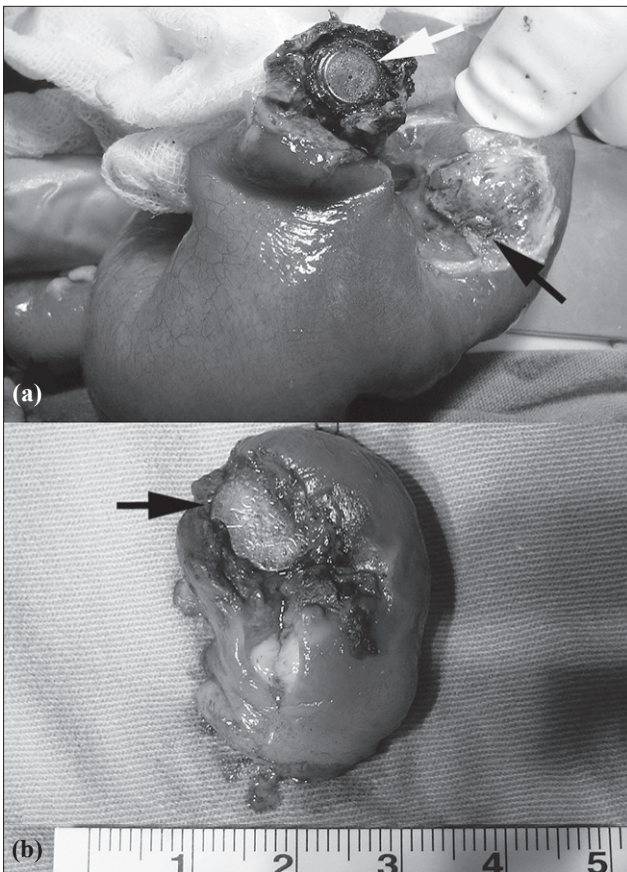


Fig. 2. (a) Case 1. Perforation of a Meckel's diverticulum by a button battery (white arrow). There was an additional perforation in the adjacent ileum where the Meckel's diverticulum was adherent (black arrow); (b) Case 2. Macroscopic appearance of the resected specimen. The button battery is visible through the perforation in the Meckel's diverticulum (arrow).

Case 2- A previously fit 5-year-old boy was admitted to the emergency room two days after swallowing a button battery from a toy. On examination, his abdomen was soft with no guarding or tenderness. Routine laboratory blood tests were normal. An abdominal radiograph demonstrated a round metallic foreign body in the lower abdomen. On the day after admission, he developed abdominal pain and tenderness. A repeat plain abdominal radiograph showed that the button battery had not moved from its original position, and there was no evidence of free air (Fig. 1b). His leukocyte count had increased to $14.5 \times 10^3/\mu\text{L}$. An urgent laparotomy was performed with a presumptive diagnosis of GI perforation. Examination of the ileum revealed an edematous and indurated Meckel's diverticulum, which had been perforated by a button battery measuring 10 mm in diameter and 3 mm in thickness with an intact envelope. A small segment of the ileum and the perforated Meckel's diverticulum were resected (Fig. 2b), and the child made an uneventful recovery.

Both cases had a Meckel's diverticulum measuring 2 cm wide and 3-4 cm in length. Pathological examination showed focal ulceration and perforation of the diverticulum, but no evidence of ectopic mucosa.

DISCUSSION

Accidental ingestion of a foreign body is a common occurrence in children. In most cases, there is no resultant morbidity, but serious complications and fatalities have occasionally been reported.^[2,3,8] Button batteries account for less than 2% of all foreign bodies ingested by children.^[8,9] These batteries are widely

used in toys and household electrical devices, and are easily accessible to children. Ingested button batteries are physically and chemically active, with the potential to cause intense tissue irritation. Perforation of the GI tract by an ingested button battery can occur by three mechanisms: i) electrical discharge and mucosal burn, ii) alkaline caustic injury due to leakage, and iii) pressure necrosis. These batteries may also be toxic due to the absorption of substances such as mercury.^[10]

Meckel's diverticulum, the most common congenital malformation of the GI tract, is typically located on the anti-mesenteric border of the ileum in 2% of the population. It represents persistence of the vitellointestinal duct. Complications such as bleeding, diverticulitis, intussusception, and Meckel's band obstruction are well recognized.^[11] Perforation of a Meckel's diverticulum due to an ingested foreign body is a very rare complication; fish bones, needles, chicken bones, and food items are the most common causes in such cases.^[4,5] Perforation of Meckel's diverticulum by a button battery is exceptional. Only two cases appear to have been reported before.^[6,7] Both were in boys, aged 1 year and 2.5 years.

After ingestion of a button battery, management depends on its localization. Batteries lodged in the esophagus should be removed promptly. If a radiograph suggests that the button battery is in the stomach, endoscopic removal is recommended if the battery has not progressed within 24 hours.^[9] Cases in which the button battery has passed into the bowel should be monitored both clinically and radiologically for possible complications.^[9] Abdominal tenderness, a static position of the foreign body on repeated plain abdominal radiographs and leukocytosis are worrying features.^[6,9] All these features were present in both of our cases. The duration of conservative management varies between patients. Willis and Ho^[6] operated on their patient on the third day after ingestion, whilst Karaman et al.^[7] operated on their case on the sixth day after ingestion. Both of our cases underwent surgery three days after ingestion.

In the case reported by Karaman et al.,^[7] the button battery perforated a Meckel's diverticulum which was adherent to the cecum and appendix. Willis and Ho^[6] described an area of superficial necrosis in the ileum that probably represented a point of contact with the perforated Meckel's diverticulum. In our first case, the battery caused a perforation in a Meckel's diverticulum and was stuck to a segment of the proximal

ileum (causing an ileal perforation) and to the rectum. In light of these observations, we recommend careful examination of adjacent bowel segments in operated cases to rule out additional pathology.

In conclusion, a swallowed button battery has the potential to cause GI perforation, particularly if it is held up in a Meckel's diverticulum. Careful clinical, radiologic and laboratory monitoring of children who ingest a button battery is required. In those that require surgery, adjacent bowel segments should be carefully inspected to exclude additional associated pathology.

Acknowledgment

The authors would like to thank Professor Mark D. Stringer of the Otago School of Medical Sciences of the University of Otago, Dunedin, New Zealand, for his helpful comments and for editing the grammar and style of the manuscript.

REFERENCES

1. Wahbeh G, Wyllie R, Kay M. Foreign body ingestion in infants and children: location, location, location. *Clin Pediatr (Phila)* 2002;41:633-40.
2. Arana A, Hauser B, Hachimi-Idrissi S, Vandenplas Y. Management of ingested foreign bodies in childhood and review of the literature. *Eur J Pediatr* 2001;160:468-72.
3. Hamilton JM, Schraff SA, Notrica DM. Severe injuries from coin cell battery ingestions: 2 case reports. *J Pediatr Surg* 2009;44:644-7.
4. Rosswick RP. Perforation of Meckel's diverticulum by foreign bodies. *Postgrad Med J* 1965;41:105-7.
5. Yagci G, Cetiner S, Tufan T. Perforation of Meckel's diverticulum by a chicken bone, a rare complication: report of a case. *Surg Today* 2004;34:606-8.
6. Willis GA, Ho WC. Perforation of Meckel's diverticulum by an alkaline hearing aid battery. *Can Med Assoc J* 1982;126:497-8.
7. Karaman A, Karaman I, Erdoğan D, Cavuşoğlu YH, Aslan MK, Varlikli O, et al. Perforation of Meckel's diverticulum by a button battery: report of a case. *Surg Today* 2007;37:1115-6.
8. Yalçın S, Karnak I, Ciftci AO, Senocak ME, Tanyel FC, Büyükpamukçu N. Foreign body ingestion in children: an analysis of pediatric surgical practice. *Pediatr Surg Int* 2007;23:755-61.
9. Litovitz T, Schmitz BF. Ingestion of cylindrical and button batteries: an analysis of 2382 cases. *Pediatrics* 1992;89:747-57.
10. Yardeni D, Yardeni H, Coran AG, Golladay ES. Severe esophageal damage due to button battery ingestion: can it be prevented? *Pediatr Surg Int* 2004;20:496-501.
11. Lloyd D. Omphalomesenteric duct remnants. In: Puri P, Höllwarth ME, editors. *Pediatric surgery*. 1st ed. Heidelberg: Springer-Verlag; 2006. p 327-32.