

# Emergent approach to small bowel tumors: diagnosis and treatment

Enes Sahin,<sup>1</sup> Kazım Şahin,<sup>3</sup> Haşim Köken,<sup>1</sup> Sertaç Ata Güler,<sup>1</sup> Turgay Şimşek,<sup>1</sup>  
Nihat Zafer Utkan,<sup>1</sup> Mustafa Şahin<sup>2</sup>

<sup>1</sup>Department of General Surgery, Kocaeli University Faculty of Medicine, Kocaeli-Türkiye

<sup>2</sup>Department of General Surgery, Selçuk University Faculty of Medicine, Konya-Türkiye

<sup>3</sup>Department of General Surgery, Kandıra State Hospital, Kocaeli-Türkiye

## ABSTRACT

**BACKGROUND:** This study presents the diagnosis and treatment of rare small bowel tumors through clinical cases.

**METHODS:** Patients treated between 2000 and 2023 were included in the study. The clinical records of the patients were analyzed retrospectively.

**RESULTS:** A total of 34 patients were included in the study. Of these patients, 26 (75.5%) were male and eight (23.5%) were female. The mean age of the patients was 62.1 years. The most common symptoms and signs were abdominal pain (76.4%), bloating (38.2%), and nausea and vomiting (17.6%). Diagnostic methods included computed tomography (CT) (82.3%), upper gastrointestinal double balloon enteroscopy (35.2%), and capsule endoscopy (5.8%). Diagnoses included adenocarcinoma in 13 cases, gastrointestinal stromal tumors (GISTs) in 12 cases, and neuroendocrine tumors (NETs) in two cases.

**CONCLUSION:** Small bowel tumors frequently present with abdominal pain, bloating, and nausea and vomiting. CT and endoscopic procedures are the primary diagnostic tools. Small bowel cancers are often diagnosed late due to subtle clinical findings and the limitations of endoscopic imaging. Targeted screening strategies may be beneficial for certain at-risk and symptomatic patient groups. Early surgical intervention offers significant advantages for diagnosed patients.

**Keywords:** Abdominal pain; bloating; capsule endoscopy; double balloon enteroscopy; small bowel tumor.

## INTRODUCTION

Tumors originating from the small intestine account for only 2% of all gastrointestinal system tumors. Over the last decade, the incidence of small intestinal tumors has increased by 2.3%.<sup>[1]</sup>

Although there are many histopathological subtypes of malignant tumors in the small intestine, the most common are adenocarcinoma, neuroendocrine tumors, sarcomas, and gastrointestinal stromal tumors (GISTs).<sup>[1,2]</sup>

The most common benign tumors of the small intestine are adenomas, with other types including lipomas, fibromas, hemangiomas, lymphangiomas and neurofibromas.<sup>[3]</sup>

Tumors originating from other organs may also locally invade the small intestine. While generally the metastasis rates are low, melanomas exhibit a high rate of metastasis to the small intestine.

Small bowel cancers are often diagnosed late due to subtle clinical findings and inadequate endoscopic imaging. Research on small bowel tumors is typically retrospective and involves

Cite this article as: Sahin E, Şahin K, Köken H, Güler SA, Şimşek T, Nihat Utkan Z, Sahin M. Emergent approach to small bowel tumors: diagnosis and treatment. *Ulus Travma Acil Cerrahi Derg* 2024;30:155-159.

Address for correspondence: Enes Şahin

Department of General Surgery, Kocaeli University Faculty of Medicine, Kocaeli, Türkiye

E-mail: dr.enessahin@hotmail.com

*Ulus Travma Acil Cerrahi Derg* 2024;30(3):155-159 DOI: 10.14744/tjtes.2024.33680

Submitted: 18.09.2023 Revised: 08.02.2024 Accepted: 26.02.2024 Published: 13.03.2024

OPEN ACCESS This is an open access article under the CC BY-NC license (<http://creativecommons.org/licenses/by-nc/4.0/>).



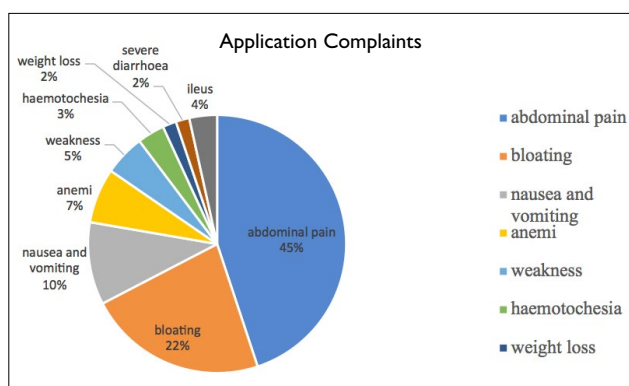


Figure 1. The percentages of complaints.

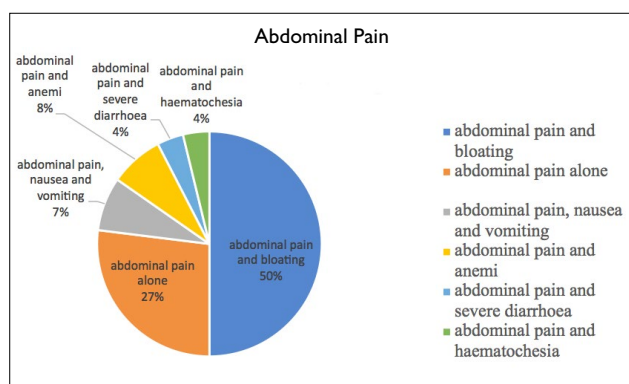


Figure 2. Complaints accompanied by abdominal pain.

small groups. There is a need for multicenter studies to obtain more detailed information about small bowel tumors.

In our study, we analyzed small bowel tumors treated in two different clinics between 2000 and 2023, focusing on stage, location, age, gender, symptoms, diagnostic methods, and treatment options. The findings were discussed and presented in light of the literature.

## MATERIALS AND METHODS

The clinical records of patients over 18 years of age diagnosed with small bowel tumors between 2000 and 2023 were retrospectively evaluated. We analyzed preoperative symptoms, diagnostic methods, operations performed, and postoperative pathological results. Since this study was retrospective, informed consent was not obtained from the patients.

### Ethics Committee Approval

This study was conducted with the approval of the Kocaeli University Ethics Committee, dated 02/11/2021 (Decision No: KÜ GOKAEK-2021/22.06) (Project No: 2021/338).

### Statistical Analysis

All statistical analyses were performed using IBM Statistical Package for the Social Sciences (SPSS) for Windows, version 20.0 (IBM Corp., Armonk, NY, USA). The Shapiro-Wilk test was used to assess the normality of data distribution. Continuous variables were expressed as mean ± standard deviation,

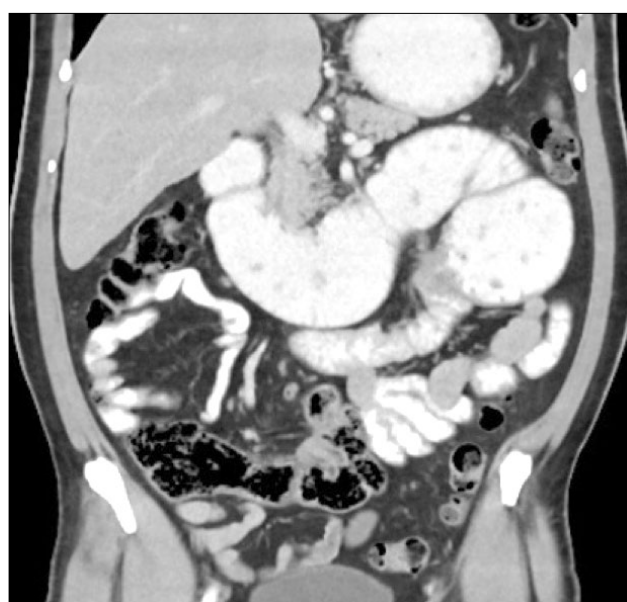

Figure 3. Emergency CT image showing a small bowel tumor.

and categorical variables were expressed as counts (percentages). A two-sided P-value < 0.05 was considered statistically significant.

## RESULTS

Upon analyzing the demographic characteristics of the patients, a total of 34 patients were diagnosed and treated. Of these, 26 (76.5%) were male and eight (23.5%) were female. The mean age was 62.09 years (range 34-82).

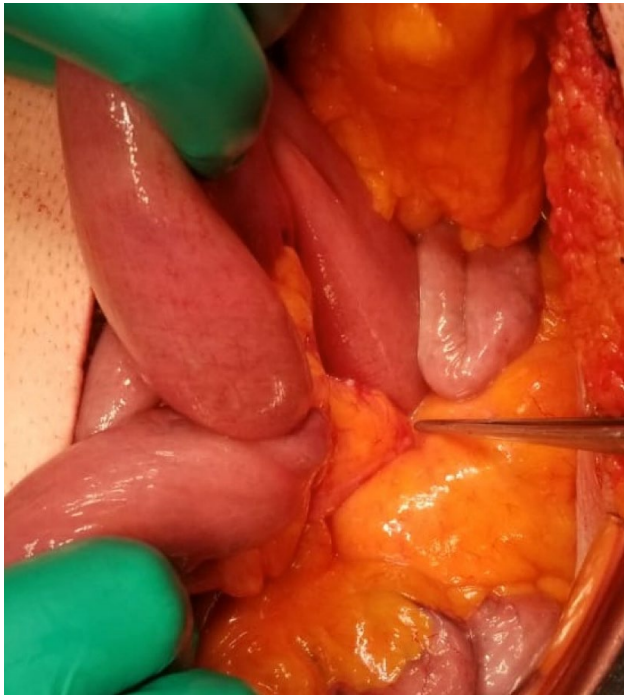The presenting complaints were as follows: abdominal pain 76.4%, bloating 38.2%, nausea and vomiting 17.6%, anemia 11.7%, weakness 8.7%, hematochesia 5.8%, weight loss 2.9%, severe diarrhea 2.9%, and ileus 5.9% (Figures 1 and 2).

In the preoperative period, a jejunal mass was observed by capsule endoscopy in two (5.8%) patients. Endoscopy performed in 12 (35.2%) patients revealed a mass in the bulb in two patients, a mass in the second part of the duodenum in five patients, a mass on the ampulla of Vater in two patients, and no lesion was seen in three patients. In four patients, double balloon endoscopy identified a mass in the jejunum.

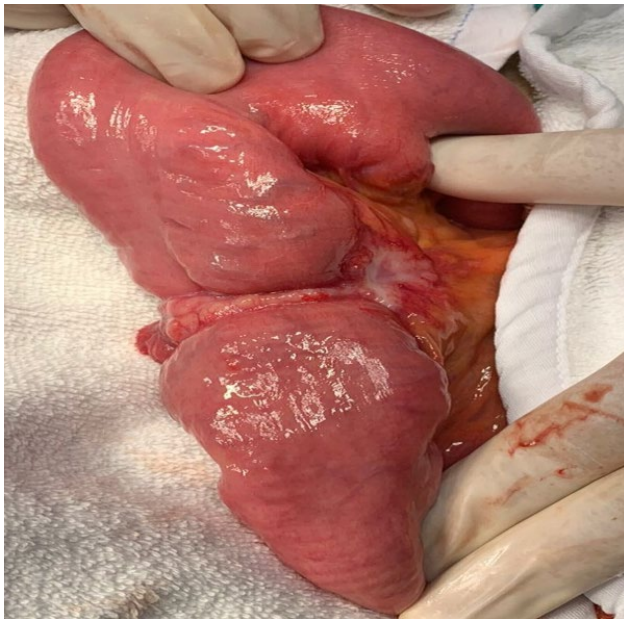
Computed tomography (CT) diagnosed 28 (82.3%) patients. A mass in the duodenum was seen in nine patients, in the ileum in eight patients, and in the jejunum in nine patients. Two patients were reported as normal (Fig. 3).

A positron emission tomography-computed tomography (PET-CT) scan was performed in four patients, and magnetic resonance (MR) enteroclysis was performed in five patients.

Of the nine patients who underwent biopsy, adenocarcinoma was found in six patients (66.6%), GIST in one patient, spindle cell mesenchymal tumor in one patient, and undifferentiated malignant tumor with neuronal differentiation in one patient.

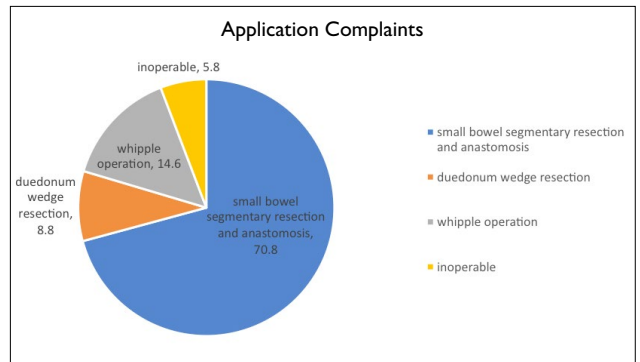


**Figure 4.** During the operation, the tumor in the small intestine caused retraction towards the mesentery.

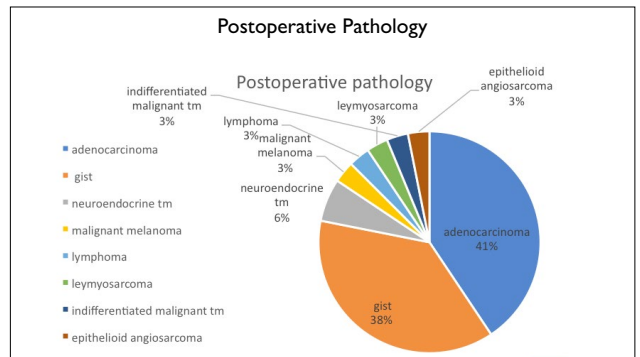


**Figure 5.** Tumor in the small intestine causing ileus during an emergency operation.

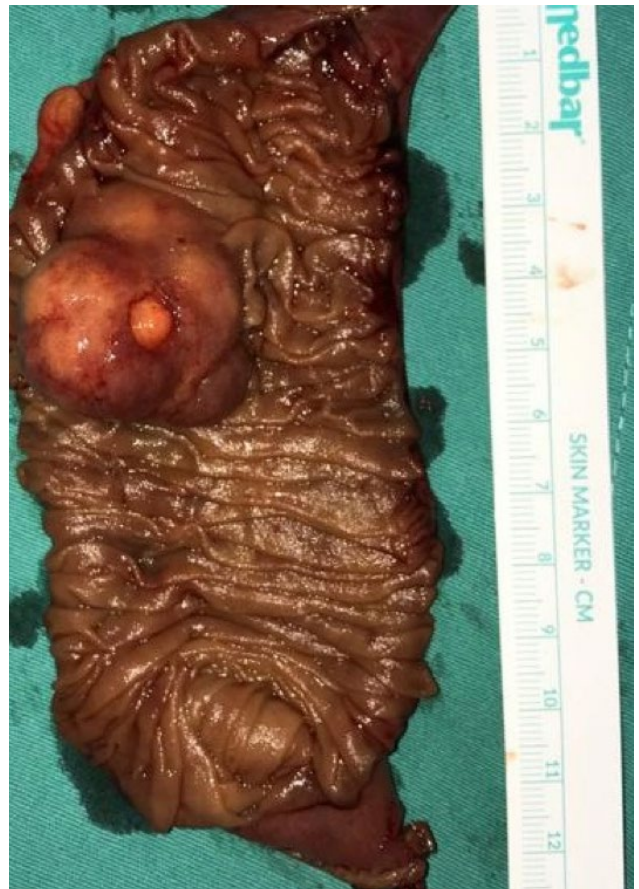Of these patients, six (17.6%) were operated on urgently (Figures 4 and 5), and 28 (82.4%) were operated on electively. Twenty-four (70.8%) patients underwent small bowel segmental resection and end-to-end anastomosis, three (8.8%) patients underwent duodenal wedge resection, five (14.6%) patients underwent a Whipple operation, and two (5.8%) inoperable duodenal tumor patients underwent loop gastrojejunostomy (Fig. 6).



**Figure 6.** Distribution of operations performed.



**Figure 7.** Distribution of postoperative pathologies.



**Figure 8.** Macroscopic image of the postoperative pyesis.

Of the 32 patients with postoperative pathology, 13 (40.6%) had adenocarcinoma, 12 (37.5%) had GIST, two had neuroendocrine tumors, one had malignant melanoma, one had malignant melanoma, one had lymphoma, one had leiomyosarcoma, one had undifferentiated malignant tumor, and one had epithelioid angiosarcoma (Figures 7 and 8).

## DISCUSSION

Small bowel cancers are rare malignancies of the gastrointestinal tract. Although the small intestine accounts for approximately 75% of the total length and 90% of the functional absorptive capacity of the gastrointestinal tract, small bowel tumors account for only 2% of gastrointestinal malignancies.<sup>[4]</sup>

Due to the length and structure of the small intestine, small bowel tumors often present symptoms late, and these symptoms are mostly nonspecific. Therefore, diagnosis is usually very difficult, leading to delays in diagnosis. In this study, we aimed to draw attention to the diagnostic difficulty of small bowel tumors and to raise awareness of this issue.

The most common symptom encountered in our patients was abdominal pain, accompanied frequently by bloating. However, both of these symptoms are not specific to small bowel tumors and may occur in many diseases.

Although screening for small bowel cancers in asymptomatic patients is ineffective and inefficient, targeted screening strategies can be applied in certain at-risk and symptomatic patient groups.

Computed tomography (CT), magnetic resonance imaging (MRI) enterography, and CT enterography, along with device-assisted enteroscopy, are the most commonly used radiological techniques for the detection of small bowel cancers, yielding effective results.<sup>[5-6]</sup> In our study, 28 (82.3%) patients underwent oral/intravenous (IV) contrast-enhanced CT as a diagnostic method. A mass in the duodenum was seen in nine patients, in ileum in eight patients, and in the jejunum in nine patients. A mass was seen in all five patients who underwent MR enteroclysis.

In common gastroscopy and total colonoscopy, endoscopic examinations are inadequate because of the inability to visualize the small intestine, except for the duodenum's first, second, and third segments, and terminal ileum. The double balloon enteroscopy procedure is not widely available; there are insufficient experienced gastroenterology and/or general surgery specialists, and equipment is scarce. Additionally, nonspecific symptoms contribute to delays in diagnosis. Patients are often diagnosed during emergency surgeries due to ileus, perforation, and bleeding. By the time a diagnosis is made, the prognosis is usually poor due to the advanced stage of the disease.<sup>[3]</sup> However, the introduction of double balloon enteroscopy and capsule endoscopy has allowed for earlier diagnosis of small bowel cancers.<sup>[7-8]</sup> In our study, capsule endoscopy was performed on two patients and double balloon

enteroscopy on four patients. All these patients were found to have a mass in the jejunum. While capsule endoscopy is highly sensitive in diagnosing occult small bowel hemorrhage, it is anticipated to be increasingly utilized in diagnosing small bowel tumors.<sup>[9]</sup>

Neuroendocrine tumors and adenocarcinomas require lymph node resection, whereas gastrointestinal stromal tumors typically do not metastasize to regional nodes and thus only necessitate resection.<sup>[10]</sup> All 34 patients in our study underwent surgery with the diagnosis or prediagnosis of a small bowel tumor, which was confirmed during the operation. The most common procedure was segmental small bowel resection. At the same time, the lymph nodes of the relevant small bowel segment were completely excised. However, excision of the lymph nodes around the superior mesenteric artery and vein was not performed in any of the patients.

Small bowel adenocarcinomas, constituting 62% of cases, have the potential for curative resection. Complete resection along with adequate lymph node dissection can lead to prolonged survival. Unfortunately, recurrence of small bowel adenocarcinoma is common, and the prognosis following recurrence is poor.<sup>[11-14]</sup> Curative surgery was achieved in 32 of the patients included in our study, while two patients were deemed inoperable and underwent palliative procedures instead. No early or late recurrences were observed in patients who underwent curative surgery.

Adenocarcinoma was the most frequently encountered tumor among our patients, followed by GIST. The most common histopathological types identified were neuroendocrine tumors (NETs), adenocarcinoma, and GISTs.<sup>[2]</sup>

Reports indicate that small bowel tumors are most commonly found in the duodenum and that duodenal adenocarcinomas metastasize less frequently than those located in the ileum and jejunum.<sup>[15]</sup> In our series, the distribution of tumor localizations in the duodenum, jejunum, and ileum was found to be similar. The relatively high frequency of diagnoses may be attributed to the fact that tumors located proximally tend to exhibit earlier signs and symptoms, facilitating earlier detection, especially through endoscopic examinations. Additionally, early diagnosis may contribute to lower metastasis rates. Given these findings, small bowel tumors should be considered in patients presenting with symptoms such as abdominal pain, nausea, vomiting, bleeding and abdominal distension.

## CONCLUSION

Small bowel tumors are rare malignancies of the gastrointestinal tract that can lead to acute intestinal obstruction symptoms. They are often diagnosed late due to clinically subtle findings and the limitations of endoscopic imaging. Therefore, small bowel tumors should be considered in patients presenting with unexplained abdominal pain, bloating, nausea and vomiting. Targeted screening strategies should be applied to certain high-risk and symptomatic patient groups exhibit-

ing signs of acute intestinal obstruction. CT scans, MRI, and upper gastrointestinal (GI) endoscopy are the primary diagnostic methods to be considered. Early diagnosis and prompt surgical intervention significantly improve patient outcomes.

**Ethics Committee Approval:** This study was approved by the Kocaeli University Ethics Committee (Date: 02.11.2021, Decision No: 2021/338).

**Peer-review:** Externally peer-reviewed.

**Authorship Contributions:** Concept: E.Ş.; Design: K.Ş.; Supervision: E.Ş.; Resource: S.A.G.; Materials: T.Ş.; Data collection and/or processing: H.K.; Analysis and/or interpretation: E.Ş.; Literature search: H.K.; Writing: K.Ş.; Critical review: N.Z.U., M.Ş.

**Conflict of Interest:** None declared.

**Financial Disclosure:** The author declared that this study has received no financial support.

## REFERENCES

1. Puccini A, Battagli F, Lenz HJ. Management of Advanced Small Bowel Cancer. *Curr Treat Options Oncol* 2018;19:69. [CrossRef]
2. Bilimoria KY, Bentrem DJ, Wayne JD, Ko CY, Bennett CL, Talamonti MS. Small bowel cancer in the United States: changes in epidemiology, treatment, and survival over the last 20 years. *Ann Surg* 2009;249:63–71.
3. Tavakkoli A, Ashley SW, Zinner MJ. Schwartz's Principles of Surgery Eleventh. Chapter 28: Small Intestine. Available from: <https://accessmedicine.mhmedical.com/content.aspx?bookid=2576&sectionid=216214191>. Accessed Feb 26, 2024.
4. Siegel RL, Miller KD, Jemal A. Cancer statistics, 2018. *CA Cancer J Clin* 2018;68:7–30. [CrossRef]
5. Kim JS, Park SH, Hansel S, Fletcher JG. Imaging and screening of cancer of the small bowel. *Radiol Clin North Am* 2017;55:1273–91. [CrossRef]
6. Vlachou E, Koffas A, Toumpanakis C, Keuchel M. Updates in the diagnosis and management of small-bowel tumors. *Best Pract Res Clin Gastroenterol* 2023;64:101860. [CrossRef]
7. Mitsui K, Tanaka S, Yamamoto H, Kobayashi T, Ehara A, Yano T, et al. Role of double-balloon endoscopy in the diagnosis of small-bowel tumors: the first Japanese multicenter study. *Gastrointest Endosc* 2009;70:498–504. [CrossRef]
8. Urbain D. Small bowel tumors and videocapsule: a productive union. *J Gastrointest Liver Dis JGLD* 2010;19:9.
9. Schwartz GD, Barkin JS. Small bowel tumors. *Gastrointest Endosc Clin N Am* 2006;16:267–75. [CrossRef]
10. Baiu I, Visser BC. Minimally invasive small bowel cancer surgery. *Surg Oncol Clin N Am* 2019;28:273–83. [CrossRef]
11. Raghav K, Katz MHG, Overman MJ. Cancers of the small bowel. *Textb Uncommon Cancer* 2012;345:441–51. [CrossRef]
12. Ojha A, Zacherl J, Scheuba C, Jakesz R, Wenzl E. Primary small bowel malignancies: single-center results of three decades. *J Clin Gastroenterol* 2000;30:289–93. [CrossRef]
13. Cunningham JD, Aleali R, Aleali M, Brower ST, Aufses AH. Malignant small bowel neoplasms: Histopathologic determinants of recurrence and survival. *Ann Surg* 1997;225:300–6. [CrossRef]
14. NCCN. Clinical Practice Guidelines in Oncology (NCCN Guidelines®) Small Bowel Adenocarcinoma. NCCN; Philadelphia, PA, USA; Sep 10, 2021. Version 2.
15. Alfagih A, Alrehaili M, Asmis T. Small bowel adenocarcinoma: 10-year experience in a cancer center-The Ottawa Hospital (TOH). *Curr Oncol Tor Ont* 2022;29:7439–49. [CrossRef]

## ORİJİNAL ÇALIŞMA - ÖZ

### İnce bağırsak tümörlerine acil yaklaşım: Teşhis ve tedavi

Enes Şahin,<sup>1</sup> Kazım Şahin,<sup>3</sup> Haşim Köken,<sup>1</sup> Sertaç Ata Güler,<sup>1</sup> Turgay Şimşek,<sup>1</sup> Nihat Zafer Utkan,<sup>1</sup> Mustafa Şahin<sup>2</sup>

<sup>1</sup>Kocaeli Üniversitesi Tıp Fakültesi, Genel Cerrahi Anabilim Dalı, Kocaeli, Türkiye

<sup>2</sup>Selçuk Üniversitesi Tıp Fakültesi, Genel Cerrahi Anabilim Dalı, Kocaeli, Türkiye

<sup>3</sup>Kandıra Devlet Hastanesi, Genel Cerrahi Kliniği, Kocaeli, Türkiye

**AMAÇ:** Nadir görülen ince bağırsak tümörlerinin tanı ve tedavisini klinik olgularla sunmak.

**GEREÇ VE YÖNTEM:** 2000-2023 yılları arasında tedavi edilen hastalar çalışmaya dahil edildi. Hastaların klinik kayıtları retrospektif olarak analiz edildi.

**BULGULAR:** Çalışmaya 34 hasta dahil edildi: Çalışmaya 34 hasta dahil edildi. Bu hastaların 26'sı (%75.5) erkek ve 8'i (%23.5) kadındı. Hastaların ortalama yaşı 62.1 idi. En sık görülen semptom ve bulgular karın ağrısı (%76.4), şişkinlik (%38.2), bulantı ve kusma (%17.6) idi. Tanı yöntemleri olarak bilgisayarlı tomografi (BT) (%82.3), üst gastrointestinal çift balon enteroskopi (%35.2), kapsül endoskopi (%5.8) kullanıldı. Olguların 13'ünde adenokarsinom, 12'sinde GİST ve 2'sinde NET saptandı.

**SONUÇ:** İnce bağırsak tümörleri sıklıkla karın ağrısı, şişkinlik ve bulantı-kusma ile başvurur. BT ve endoskopik işlemler tanı için ilk tercihtir. İnce bağırsak kanserleri klinik olarak silik bulgular ve yetersiz endoskopik görüntüleme nedeniyle geç teşhis edilmektedir. Belirli risk altındaki ve semptomatik hasta gruplarında hedefe yönelik tarama stratejileri uygulanabilir. Tanı konulan hastalarda erken cerrahi müdahale önemli avantajlar sağlamaktadır.

**Anahtar sözcükler:** Çift balon enteroskopi; ince bağırsak tümörü; kapsül endoskopi; karın ağrısı; şişkinlik.

Ulus Travma Acil Cerrahi Derg 2024;30(3):155-159 DOI: 10.14744/tjtes.2024.33680