

A rare association: inferior vena cava anomalies and congenital heart diseases

Nadir görülen birliktelik: İnferiyör vena kava anomalileri ve doğumsal kalp hastalıkları

İlker Ertuğrul, M.D., Vehbi Doğan, M.D., Utku Arman Örün, M.D., Selmin Karademir, M.D.

Department of Pediatric Cardiology, Dr. Sami Ulus Maternity and Children's Health and Diseases Training and Research Hospital, Ankara

Summary– The numerous variations of abnormalities of the inferior vena cava (IVC) result in anomalies such as isolated left IVC, double IVC and more than 60 types of malformation. These anomalies are rare and recognized incidentally during surgical or radiological procedures. They may lead to clinical complications during abdominal surgery, and predispose to venous thrombosis. Although they have no definite relationship to other congenital cardiac lesions, identification of these anomalies are important for pre-operative planning and post-operative follow-up. This report presents two cases of congenital IVC anomalies accompanied by congenital heart diseases.

Abnormalities of the inferior vena cava (IVC) in the general population have been documented. Embryogenesis of the IVC involves persistence or regression of three layers of embryonic veins. Numerous variations result in anomalies such as isolated left IVC, double IVC and in excess of 60 types of malformation.^[1] Although rare, and recognized incidentally during surgical or radiological procedures, these anomalies may lead to clinical complications during abdominal surgery, and predispose to venous thrombosis.^[2] Azygos and hemiazygos continuation of the IVC has been associated with situs anomalies and other congenital heart anomalies, as well as asplenia and polysplenia syndromes. Right-sided IVC and double IVC have

Abbreviations:

CHD	Congenital heart disease
CT	Computed tomography
DVT	Deep vein thrombosis
IVC	Inferior vena cava
MRI	Magnetic resonance imaging
USG	Ultrasonography

Özet– İnferyör vena kava (IVC) anomali varyasyonları genel popülasyonda bildirilmektedir. Sol IVC, çift IVC yanında 60'dan fazla değişik IVC anomali bildirilmiştir. Bu anomaliler genellikle cerrahi ve radyolojik girişimler sırasında tesadüfen fark edilirler. Abdominal cerrahide klinik komplikasyonlara ve venöz tromboz gelişimine zemin hazırlayabilirler. Kalp hastalıklarıyla ilişkisi bildirilmese de kalp hastalığı varlığında IVC anomalileri ameliyat öncesi planlamada ve ameliyat sonrası takip için önemlidir. Bu yazıda doğumsal kalp hastalıklarına eşlik eden IVC anomali olan iki olgu sunuldu.

become increasingly recognized in the absence of any complaints. They have no definite relationship to other congenital cardiac lesions,^[3] but they are important for management of patients with congenital heart disease (CHD).

This report presents two cases of congenital anomalies of IVC accompanied by CHDs.

CASE REPORT

Case 1– A 15-month-old infant with a diagnosis of Fallot tetralogy underwent cardiac catheterization. He had been followed up in the clinic since birth. Prior to catheterization, there were no reported episodes of cyanotic spell. Oxygen saturation measured with pulse oximetry was 79%. He was 11 kg at the time of intervention. During the procedure, a left IVC was detected after femoral puncture. The right femoral vein

Received: April 02, 2015 Accepted: June 25, 2015

Correspondence: Dr. İlker Ertuğrul. Dr. Sami Ulus Kadın Doğum Çocuk Sağlığı ve Hastalıkları Eğitim ve Araştırma Hastanesi, Çocuk Kardiyoloji Bölümü, Ankara.

Tel: +90 312 - 305 11 57 e-mail: ilkerer@hacettepe.edu.tr

© 2015 Turkish Society of Cardiology



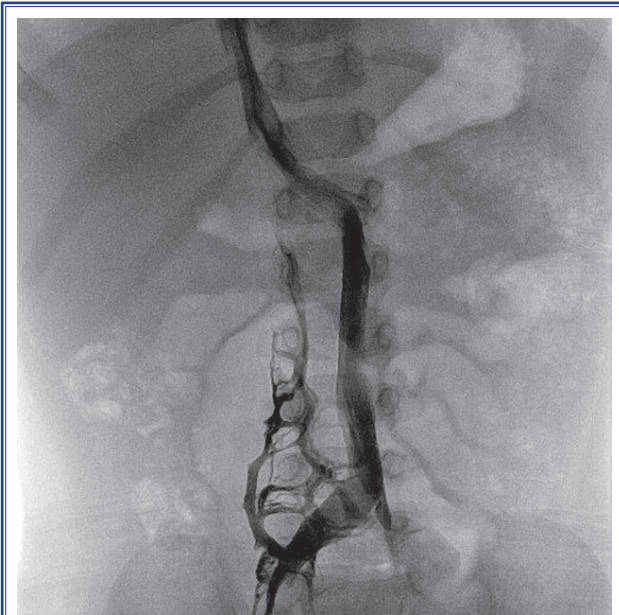


Figure 1. Case 1 femoral vein contrast material injection.

was connected to the left-sided IVC and it drained to the hepatic segment of the IVC at liver level. The procedure was completed via the left IVC, and right ventricular and aortic contrast material injection was done. McGoon index was calculated as 1.9 and she was assessed as appropriate for total correction procedure. Total corrective surgery was performed two months after the intervention without any complications (Figure 1).

Case 2– A 5-month-old female infant was admitted to clinic with a complaint of poor weight gain. Tachypnea and a murmur were detected on physical examination, and echocardiography revealed atrial and ventricular septal defects and pulmonary hypertension. Diagnostic catheterization was performed in order to assess patient operability. A left-sided IVC was noticed during the venous puncture the catheterization. Right heart catheterization was completed and left ventricular contrast material injection was done via the left IVC. Pulmonary vascular resistance was measured as 2.1 WU/m². Surgery was planned for the patient.

DISCUSSION

The IVC develops in a complex process which is completed at the eighth week approximately. The IVC is formed from three pairs of parallel veins that subsequently appear and regress. Left-sided IVC develops

due to regression anomalies of the supracardinal vein. Persistence of this vein, with regression of the right supracardinal vein, leads to formation of a left-sided vena cava.^[4] The prevalence of left-sided IVC is reported as between 0.2–0.5%.^[1,5] Lack of pre-operative identification of this entity may have grave consequences, especially during surgery involving retroperitoneal structures. Since abnormal venous structures are generally dilated and tortuous, they are prone to intraoperative trauma and development of thrombus, which may escape detection or be misdiagnosed.^[6] Several studies have demonstrated an increased risk for deep vein thrombosis (DVT) in the presence of an IVC anomaly. Fuster and et al. evaluated 116 patients under 50 years of age with DVT. They found that 6 of 37 (16.2%) patients with iliac vein thrombosis had a venous anomaly.^[7] Similar studies have shown that the presence of a venous anomaly is a strong predisposition factor for DVT in young patients, with a prevalence of 5–9%. Stasis due to abnormal venous structure is thought to be responsible for these complications.^[8]

Although there is no reported association of IVC anomalies and CHDs, they may lead to morbidity in these patients and are important for management of CHDs. The risk of thromboembolism is increased in patients with cyanotic CHD. The precise mechanisms of thromboembolism in patients with cyanotic CHD have not yet been determined.^[9] The coexistence of CHD and IVC anomalies, as in our cases, increase risk of thrombosis and, by causing right to left shunt, may lead to systemic emboli. Unawareness of an IVC anomaly may lead to misdiagnosis. These patients may have additional risk factors such as genetic predisposition. A retrospective study analyzing 28 thrombotic children with different cardiac disorders revealed 22% incidence of Factor V Leiden and prothrombin G20210A mutations.^[10] The first case in the present report, the infant with Fallot tetralogy, had a higher risk of thromboembolism. Awareness of the increased risk of thrombus formation may lead to a decision of earlier intervention for that patient in order to avoid thromboembolic events.

The Fontan operation was designed to provide blood flow in series to the pulmonary and systemic circulation without the need for a right ventricular pumping chamber. This arrangement has improved life expectancy for patients with single-ventricle and

pulmonary outflow obstruction compared with previous arterial shunts. Since this physiology is affected by numerous factors, any additional pathology will lead to an increase in mortality. Physical barriers to pulmonary and systemic circulation (stenosis at the site of anastomosis, valvular insufficiencies, outflow tract obstructions, congenital anomalies of systemic and pulmonary veins, any stenosis of pulmonary and venous system) are leading factors for increased mortality and morbidity.^[11] There may also be failure of Fontan circulation in patients with CHD associated with IVC anomalies. Additionally, Fontan circulation has a high risk of thromboembolism, which is a significant contributor to late morbidity and mortality after operation. Presence of IVC anomalies is also an additional factor for development of thrombosis in patients with Fontan physiology.^[12]

Reporting and research on the association of CHD and IVC anomalies is scant, but identification of these anomalies is important for pre-operative planning and post-operative follow-up. While IVC anomalies have been reported as rare (0.2–1%), they should be investigated in patients with CHD prior to surgery. Abdominal ultrasonography (USG), computed tomography (CT) and magnetic resonance imaging (MRI) are all methods in which diagnostic cardiac catheterization is not performed. Compared to CT, abdominal USG and MRI are much safer procedures in exposing such anomalies. For patients with CHDs, the presence of such an anomaly may affect both timing and method of surgery. Although venous anomalies are mostly asymptomatic, their recognition is important because of their potential to lead to surgical complications and thrombosis. In order to decrease mortality and morbidity among patients, pre-operative evaluation of an IVC anomaly is essential, especially in patients with single ventricle physiology and a high risk of thromboembolism.

Conflict-of-interest issues regarding the authorship or article: None declared.

REFERENCES

1. Bass JE, Redwine MD, Kramer LA, Huynh PT, Harris JH Jr. Spectrum of congenital anomalies of the inferior vena cava: cross-sectional imaging findings. *Radiographics* 2000;20:639–52. [CrossRef](#)
2. Ang WC, Doyle T, Stringer MD. Left-sided and duplicate inferior vena cava: a case series and review. *Clin Anat* 2013;26:990–1001. [CrossRef](#)
3. Price G. Anomalous systemic venous return. In: Anderson R, Baker E, Redington A, Rigby M, Penny D Wernovsky G, editors. *Paediatric cardiology*, New York: Churchill Livingstone; 2009. p. 485–96.
4. Malaki M, Willis AP, Jones RG. Congenital anomalies of the inferior vena cava. *Clin Radiol* 2012;67:165–71. [CrossRef](#)
5. Zhang L, Yang G, Shen W, Qi J. Spectrum of the inferior vena cava: MDCT findings. *Abdom Imaging* 2007;32:495–503.
6. Mathews R, Smith PA, Fishman EK, Marshall FF. Anomalies of the inferior vena cava and renal veins: embryologic and surgical considerations. *Urology* 1999;53:873–80. [CrossRef](#)
7. García-Fuster MJ, Forner MJ, Flor-Lorente B, Soler J, Campos S. Inferior vena cava malformations and deep venous thrombosis. [Article in Spanish] *Rev Esp Cardiol* 2006;59:171–5. [Abstract] [CrossRef](#)
8. Nanda S, Bhatt SP, Turki MA. Inferior vena cava anomalies—a common cause of DVT and PE commonly not diagnosed. *Am J Med Sci* 2008;335:409–10. [CrossRef](#)
9. Kajimoto H, Nakazawa M, Murasaki K, Mori Y, Tanoue K, Kasanuki H, et al. Increased thrombogenesis in patients with cyanotic congenital heart disease. *Circ J* 2007;71:948–53.
10. Gurgey A, Ozyurek E, Gümrük F, Celiker A, Ozkutlu S, Ozer S, et al. Thrombosis in children with cardiac pathology: frequency of factor V Leiden and prothrombin G20210A mutations. *Pediatr Cardiol* 2003;24:244–8. [CrossRef](#)
11. Kırallı K, Omeroglu SN, Mansuroglu D, Rabus MB, Kayalar N, Balankay M, et al. Long-term results of modified fontan procedures (right heart bypass operations). *J Turkish Thorac Cardiovasc Surg* 2001;9:26–30.
12. Coon PD, Rychik J, Novello RT, Ro PS, Gaynor JW, Spray TL. Thrombus formation after the Fontan operation. *Ann Thorac Surg* 2001;71:1990–4. [CrossRef](#)

Keywords: Heart defects; IVC anomalies; surgery; thrombus.

Anahtar sözcükler: Kalp defekti; IVC anomalisi; cerrahi; tromboz.