

## Tricuspid valve dysfunction associated with entrapment of the guide wire in the tricuspid valve during central venous catheterization

Santral venöz kateterizasyon sırasında klavuz telin triküspit kapakta sıkışmasına bağlı triküspit kapak disfonksiyonu

Fatih Koc, M.D., Orhan Dogdu, M.D., Bahadır Sarlı, M.D., Mehmet Gungor Kaya, M.D.

Erciyes University, Faculty of Medicine, Department of Cardiology, Kayseri

Central venous catheterization which is frequently used for hemodynamic monitoring represents a high risk for catheter-related complications. Tricuspid valve dysfunction associated with central venous catheterization is very rare. A 22-year old woman with acute renal failure was scheduled for hemodialysis. After completion of catheter placement, attempts to remove the guide wire failed. Radiographic examination was not helpful in showing the extension of the wire. Transthoracic echocardiography showed tricuspid valve motion upon the movement of guide wire. Color Doppler imaging revealed mild to moderate tricuspid regurgitation. A right atriotomy was performed through a right anterolateral thoracotomy to remove the guide wire entrapped in the tricuspid chordae. Postoperative transthoracic echocardiography showed complete disappearance of tricuspid dysfunction.

**Key words:** Catheterization, central venous/adverse effects; tricuspid valve/injuries; ultrasonography, interventional.

Hemodinamik monitörizasyon için sıkça kullanılan santral venöz kateterizasyonun ciddi komplikasyon riskleri vardır. Santral venöz kateterizasyona bağlı triküspit kapak disfonksiyonu oldukça nadirdir. Yirmi iki yaşında kadın hastaya akut böbrek yetersizliği tanısıyla hemodiyaliz planlandı. Hemodiyaliz kateterini yerleştirme işlemi tamamlandıktan sonra, klavuz tel çıkarılamadı. Radyografide telin hangi yapıya kadar uzandığı net olarak belirlenemedi. Transtorasik ekokardiyografide, klavuz telin hareketiyle triküspit kapağın hareket ettiği görüldü. Renkli Doppler ile hafif-orta şiddette triküspit yetersizliği saptandı. Hastaya sağ anterolateral torakotomi yoluyla sağ atriyyotomi yapıldı ve triküspit kapağı geçip kordalar arasına sıkışan klavuz tel çıkarıldı. Ameliyat sonrası yapılan transtorasik ekokardiyografide hastadaki triküspit yetersizliğinin tamamen kaybolduğu görüldü.

**Anahtar sözcükler:** Kateterizasyon, santral venöz/yan etki; triküspit kapak/yaralanma; ultrasonografi, girişimsel.

Central venous catheterization (CVC) is frequently used during emergency hemodialysis, total parenteral nutrition, hemodynamic monitorization, or during implantation of a temporary pacemaker and during conditions when peripheral veins are not used.<sup>[1]</sup> The incidence of complications during the procedure is approximately 15%.<sup>[2]</sup> Early stage complications include arterial injury, pneumothorax, nerve damage, valve trauma, arrhythmia, trauma to the pulmonary artery, thrombosis, and infection.<sup>[3]</sup> Complications such as venous thrombosis, vena cava superior syndrome, endocarditis, sepsis and related complications may also occur during the late stages of the condition.<sup>[3]</sup> In addition to these complications, rare but life threatening complications such as perforation of the superior vena cava, aortic injury and cardiac tamponade have also

been reported.<sup>[4-6]</sup> The incidence of complications is reduced by increasing the possibility inserting the catheter on the first attempt (first entrance), if the procedure is performed with ultrasonographic guidance.<sup>[2]</sup>

### CASE REPORT

A 22-year old woman presented to the emergency unit with complaints of malaise for the past one week. Her blood pressure was 100/60 mmHg and pulse rate was 110 beats/min. Heart sounds were characteristic of tachycardia and no murmur was heard. Electrocardiography showed sinus tachycardia. Following the diagnosis of acute renal failure, hemodialysis was scheduled. After insertion of a hemodialysis catheter using a J-tip guide wire which was not previously used, the guide wire could not be removed despite ret-

Received: 10.04.2009; Accepted: 08.06.2009

Corresponding address: Dr. Fatih Koc. Erciyes Üniversitesi Tıp Fakültesi, Kardiyoloji Anabilim Dalı, Talas Yolu, 38039 Kayseri, Tel: +90 – 352 – 437 49 37 / 27776, e-mail: drfatkoc@gmail.com

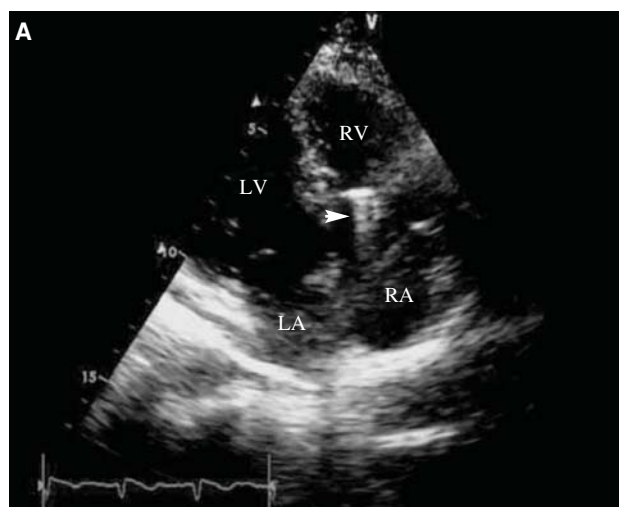
rieval attempts. An X-ray was obtained, however the exact extension of the wire could not be identified. A transthoracic echocardiography was then performed and following external front and backwards movements of the guide wire the tricuspid valve motion was observed (Figure 1). A mild to moderate tricuspid regurgitation was detected by color Doppler imaging. The patient was scheduled for surgery to avoid damage to the tricuspid valve. A right atriotomy was performed via the right anterolateral thoracotomy approach. The guide wire which was entrapped within the chordae was removed through the tricuspid valve. Postoperative transthoracic echocardiography showed a completely disappeared tricuspid regurgitation.

## DISCUSSION

Central venous catheterization (CVC) is currently frequently used with severe complications. Arterial puncture, hematoma and pneumothorax are the most commonly observed complications.<sup>[2]</sup> The incidence of pneumothorax is about 1-1.5% and more frequently seen at the subclavian entrance compared to the internal jugular vein entrance.<sup>[2,7]</sup> The experience of the operator is very important for the development of complications, which seem to be reduced to half when the procedure is performed by an experienced operator (who has performed >50 procedures).<sup>[8]</sup> Three or more trails during puncture has a six-fold increase in the risk of complications.<sup>[8]</sup> Another important factor is the anatomical structure and the materials used.<sup>[9,10]</sup> Variations in anatomic structure is observed at a rate of approximately 0.3%.<sup>[7]</sup> A variety of catheters are used for the catheterization procedure. These may have a single lumen or double lumen. The number of lumens does not affect the rate of complications.<sup>[8]</sup> Arrhythmias may occur when advancing the guide wire. The most commonly seen are the early atrial and ventricular arrhythmias. Although it is very rare, complete heart block and sudden death related to the guide wire have been also reported.<sup>[7]</sup>

There are many recommendations for the reduction of complications associated with central venous catheterization. Experience of the operator and use of ultrasonography during the procedure are important factors.<sup>[11]</sup> Ultrasonography both facilitates the procedure and helps in identifying the patency and variations of the vein used.<sup>[12]</sup> Ultrasonography-guided catheterization through the internal jugular vein has been shown by various studies to reduce mechanic complications, unsuccessful attempt rates, and duration required for the procedure.<sup>[11,12]</sup>

Tricuspid valve dysfunction associated with central venous catheterization is very rare and only two cases have been reported.<sup>[13,14]</sup> In the cases reported by Araki et



**Figure 1.** Apical four chamber view showing the guide wire over the tricuspid valve (white arrow).

al.<sup>[14]</sup> resistance during removal of the guide wire was reported and the wire was retrieved from the right ventricle through the catheter. On the other hand, the guide wire in our case could not be removed percutaneously, despite several attempts, and was rather removed surgically to avoid damage to the tricuspid valve.

Due to the life threatening complications of central venous catheterization, the procedure should carefully be performed and by experienced individuals, which would significantly reduce complications.

## REFERENCES

1. Dailey RH. "Code Red" protocol for resuscitation of the exsanguinated patient. *J Emerg Med* 1985;2:373-8.
2. Feller-Kopman D. Ultrasound-guided internal jugular access: a proposed standardized approach and implications for training and practice. *Chest* 2007;132:302-9.
3. Mathew JP, Newman MF. Hemodynamic and related monitoring. In: Estafanous FG, Barash PG, Reves JG, editors. *Cardiac anesthesia: principles and clinical practice*. Philadelphia: Lippincott Williams & Wilkins; 2001. P. 195-237.
4. Schummer W, Schummer C, Fritz H. Perforation of the superior vena cava due to unrecognized stenosis. Case report of a lethal complication of central venous catheterization. *Anaesthesist* 2001;50:772-7.[Abstract]
5. Fangio P, Mourgeon E, Romelaer A, Goarin JP, Coriat P, Rouby JJ. Aortic injury and cardiac tamponade as a complication of subclavian venous catheterization. *Anesthesiology* 2002;96:1520-2.

6. Klotz HP, Schöpke W, Kohler A, Pestalozzi B, Largiadèr F. Catheter fracture: a rare complication of totally implantable subclavian venous access devices. *J Surg Oncol* 1996;62:222-5.
7. Kusminsky RE. Complications of central venous catheterization. *J Am Coll Surg* 2007;204:681-96.
8. Taylor RW, Palagiri AV. Central venous catheterization. *Crit. Care Med* 2007;35:1390-6.
9. Batra RK, Guleria S, Mandal S. unusual complication of internal jugular vein cannulation. *Indian J Chest Dis Allied Sci* 2002;44:137-9.
10. Paw HG. Bilateral pleural effusions: unexpected complication after left internal jugular venous catheterization for total parenteral nutrition. *Br J Anaesth* 2002;89:647-50.
11. Lefrant JY, Muller I, De La Coussaye JE, Prudhomme M, Ripart J, Gouzes C, et al. Risk factors of failure and immediate complications of subclavian vein catheterization in critically ill patients. *Intensive Care Med* 2002;28:1036-41.
12. Randolph AG, Cook DJ, Gonzales CA, Pribble CG. Ultrasound guidance for placement of central venous catheters: a meta-analysis of the literature. *Crit Care Med* 1996;24:2053-8.
13. Hoda MQ, Das G, Mamsa KA, Salimulla H. Unusual site of guide-wire entrapment during central venous catheterization. *J Pak Med Assoc* 2006;56:139-41.
14. Araki Y, Fukuda I, Hirano M, Matsuoka N, Kazama T. Central venous catheterization complication by a guide wire. *Masui* 2009;58:3546. [Abstract]