

Percutaneous treatment of Lutembacher syndrome: a case report

Lutembacher sendromlu bir olguda perkütan tedavi

Aydan Ongun Ozdemir, M.D., Deniz Kumbasar, M.D., Irem Dincer, M.D., Yusuf Atmaca, M.D.

Ankara University, Faculty of Medicine, Department of Cardiology, Ankara

Lutembacher syndrome is a rare combination of congenital atrial septal defect (ASD) and acquired mitral stenosis (MS). Although it is traditionally corrected by surgical treatment, both conditions are amenable to transcatheter treatment without the need for surgery. We present a 49-year-old woman with Lutembacher syndrome. On pretreatment transthoracic echocardiography, planimetric mitral valve area was 1.5 cm², maximum diastolic gradient was 17 mmHg, and mean diastolic gradient was 9 mmHg. Combined percutaneous treatment was performed including balloon valvuloplasty for MS and closure of the ASD with the Amplatzer septal occluder. The patient was discharged uneventfully. Transthoracic echocardiography performed a week later showed planimetric mitral valve area as 2.1 cm², maximum diastolic gradient as 9 mmHg, and mean diastolic gradient as 4 mmHg. Complete closure of the ASD was achieved. Transcatheter treatment may be an effective alternative to surgery in selected patients with Lutembacher syndrome.

Key words: Balloon dilatation; heart catheterization; heart septal defects, atrial/therapy; Lutembacher syndrome/therapy; mitral valve stenosis/therapy.

Concomitant congenital atrial septal defect (ASD) and rheumatic mitral stenosis (MS) was first described in 1916 by Lutembacher on a 61-year-old woman.^[1] The hemodynamic effects of these two diseases are worth mentioning. MS increases the left-to-right shunt caused by ASD, whereas ASD decreases left atrial pressure and as a result the mitral valve gradient.^[2] A large ASD plays a role in the improvement of symptoms associated with MS. The treatment choice in such patients is surgery. However, percutaneous intervention is currently used for the management of both conditions.^[3,4] Ruiz et al.^[5] first described the use

Lutembacher sendromu doğuştan atriyal septal defekt (ASD) ve edinsel mitral darlık (MD) birleşiminden oluşan nadir bir durumdur. Geleneksel olarak cerrahi tedavi uygulansa da, günümüzde bu sendromu oluşturan her iki hastalık da kateter yoluyla tedaviye uygundur. Bu yazıda Lutembacher sendromlu 49 yaşında bir kadın hasta sunuldu. Tedavi öncesindeki transtorasik ekokardiyografide mitral kapak alanı planimetrik olarak 1.5 cm², en yüksek diyastolik gradiyent 17 mmHg, ortalama diyastolik gradiyent 9 mmHg ölçüldü. Hastaya balon valvotomi yapıldı ve ASD Amplatzer septal tıkaçıcı cihaz ile kapatıldı. Sorunsuz taburcu edilen hastada bir hafta sonra yapılan transtorasik ekokardiyografide mitral kapak alanı planimetrik olarak 2.1 cm², en yüksek diyastolik gradiyent 9 mmHg, ortalama diyastolik gradiyent 4 mmHg ölçüldü. Tıkaçıcı cihaz ile ASD'ni tamamen kapandığı görüldü. Lutembacher sendromlu seçilmiş olgularda kateter yoluyla yapılan tedavi cerrahiye etkin bir seçenek olabilir.

Anahtar sözcükler: Balon genişletme; kalp kateterizasyonu; kalp septal defekti, atriyal/tedavi;

of catheter intervention in 1992 in a patients with Lutembacher syndrome.

In this paper, we present the first case of Lutembacher syndrome in Turkey, who underwent mitral balloon valvotomy (MBV) and whose ASD was closed using the septal occluder device.

CASE REPORT

A 49-year-old woman who presented with complaints of exertional dyspnea and palpitation was referred to our clinic following the diagnosis of rheumatic MS

Received: 27.03.2009; Accepted: 10.07.2009

Corresponding address: Dr. Aydan Ongun Özdemir. 31. Sok., 5/12, 06490 Bahçelievler, Ankara.

Tel: +90 - 312 - 508 27 76, e-mail: aongun@msn.com

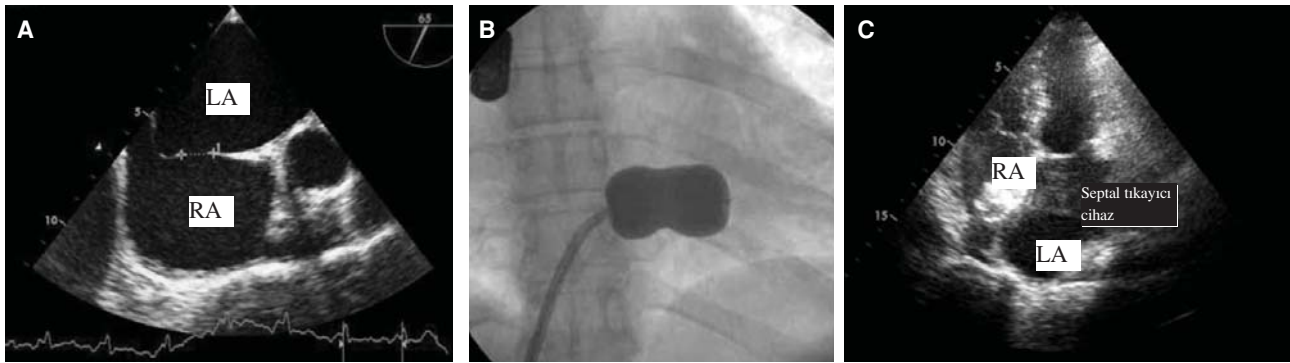


Figure 1. (A) Identification of the size of atrial septal defect on transesophageal echocardiography before percutaneous intervention. (B) Dilatation of the mitral valve with the Inoue balloon. (C) Image of the Amplatzer septal occluder device in the four chamber section on transthoracic echocardiography after percutaneous intervention.

and ostium secundum-type ASD by transthoracic echocardiography at a health center. The planimetric mitral valve area of the patient was 1.5 cm², her maximum diastolic gradient was 17 mmHg, mean diastolic gradient was 9 mmHg, and the pulmonary artery systolic pressure was measured as 45 mmHg. The physical examination performed at our clinic revealed a 2/6 systolic murmur at left sternal border, a 2/6 diastolic rumble and a mitral opening sound was heard at the apex. Pulmonary examination showed normal findings. Exercise capacity was of New York Heart Association (NYHA) Class II. A normal sinus rhythm and dilatation in both atria were observed on electrocardiography. Transesophageal echocardiography (TEE) demonstrated enlargement of both atria and the right ventricular spaces. The mitral valve leaflets were thickened, movement was maintained and no calcification was observed. The morphologic mitral valve score was 5 and a mild degree of mitral regurgitation (MR) was observed by color Doppler flow. The pulmonary/systemic flow rate was measured as 2 for the ASD with diameters of 1.2x1.1 cm (Figure 1a). The border of atrial septal defect was large for all atrial septal walls and was deemed adequate for percutaneous treatment. Treatment by the catheter was scheduled since ASD and MS were both suitable for percutaneous treatment. The coronary angiography which was performed at the catheter laboratory after obtaining a consent form from the patient was found to be normal. The mitral valve was penetrated by the guidance of TEE and mild sedation after administering heparin (5000 U); the mitral valve was then dilated to 28 mm using the Inoue balloon catheter set (Toray International America Inc. Houston, TX, USA) (Figure 1b). The mean gradient fell from 9 mmHg to 3 mmHg after mitral balloon valvotomy and a mild MR was observed. The stretch diameter of the ASD was found to be 15 mm by the sizing balloon catheter. The 16 mm Amp-

latzer septal occluder device (AGA Medical Corporation, Minnesota, USA) was implanted under fluoroscopy through guidance of TEE and the ASD was observed to be totally closed and left-to-right shunt was seen in the color Doppler flow image performed with TEE. No symptoms were reported during discharge. The transthoracic echocardiography performed a week later showed the planimetric mitral valve area as 2.1 cm², maximum diastolic gradient as 9 mmHg, and the mean diastolic gradient as 4 mmHg; a first degree MR was observed. The ASD was observed to be closed and no left-to-right shunt was seen with the occluder device implanted in the interstitial septum (Figure 1c).

DISCUSSION

Lutembacher syndrome shows a predisposition for women since mitral stenosis and ASD are more frequently observed in women. Approximately 4% cases of MS are seen in patients with ASD, whereas 0.6-0.7% of ASD cases are seen in patients with MS.^[1] The diagnosis of Lutembacher syndrome was previously made many years ago since the pathogenesis of the mid-diastolic murmur of ASD was unknown; however, the frequency has decreased since the period when mid-diastolic murmur was reported to be due to increased flow through the tricuspid valve. In patients with Lutembacher syndrome MS is known to increase the left-to-right shunt caused by ASD, whereas ASD plays a role in the improvement of left atrial pressure and decrease in the diastolic mitral pressure gradient. As a result, mitral valve measurements in patients with Lutembacher syndrome should be identified by planimetric or continuity equation; and the Doppler pressure should not be used due to faulty half life.^[2]

Ruiz et al.^[5] first performed a combined percutaneous treatment on a patient with Lutembacher syndrome in 1992. There is currently no randomized

or cross-sectional study which investigates combined percutaneous treatment in patients with Lutembacher syndrome. However, the success rate of combined percutaneous treatment in case studies is very high and no short or long term complications have been reported. On the other hand, the complete closure rate of ASD by the septal occluder device during combined percutaneous treatment was found to be 93-97%.^[6] The most important complication of the procedure is embolization of the septal occluder device. The procedure of retrieval and re-implantation is implemented when there is embolization of small devices; however, surgical interventions are required for large devices.^[7] The success rate of the other percutaneous intervention with MBV by the transseptal Inoue balloon technique was 99%.^[8] The life threatening complication rate (death, puncture in the left ventricle and stroke) was very low (0-0.5%) and the risk of developing important and severe complications (3-4 degree MR, cardiac tamponade, thromboembolism) was found to be lower when compared to the other procedures.^[9]

The combined percutaneous treatment technique is reported to reduce the mortality and morbidity risk associated with cardiac surgery, to decrease physiologic trauma due to thoracotomy scar and to reduce the surgery-related length of stay in the hospital in patients with Lutembacher syndrome.^[10] MBV may be performed in these patients when there is recurrence of severe MS. However, since the transseptal approach can not be used due to the Amplatzer septal occluder device, MBV can be performed using the retrograde nontransseptal approach by passing from the left ventricle into the left atrium with the transarterial technique.^[11]

To the best of our knowledge, this case is the first case of Lutembacher syndrome in Turkey to undergo a combined percutaneous treatment intervention. Despite limited, our experience shows that treatment by the combined catheter technique can be performed safely and successfully without the need for open heart surgery.

REFERENCES

1. Perloff JK. Atrial septal defect. In: The clinical recognition of congenital heart disease. 4th ed. Philadelphia: W. B. Saunders; 1994. p. 233-99.
2. Vasan RS, Shrivastava S, Kumar MV. Value and limitations of Doppler echocardiographic determination of mitral valve area in Lutembacher syndrome. *J Am Coll Cardiol* 1992;20:1362-70.
3. Masura J, Gavora P, Formanek A, Hijazi ZM. Transcatheter closure of secundum atrial septal defects using the new self-centering Amplatzer septal occluder: initial human experience. *Cathet Cardiovasc Diagn* 1997;42:388-93.
4. Carabello BA. Modern management of mitral stenosis. *Circulation* 2005;112:432-7.
5. Ruiz CE, Gamra H, Mahrer P, Allen JW, O'Laughlin MP, Lau FY. Percutaneous closure of a secundum atrial septal defect and double balloon valvotomies of a severe mitral and aortic valve stenosis in a patient with Lutembacher's syndrome and severe pulmonary hypertension. *Cathet Cardiovasc Diagn* 1992;25:309-12.
6. Thanopoulos BD, Laskari CV, Tsaousis GS, Zarayelyan A, Vekiou A, Papadopoulos GS. Closure of atrial septal defects with the Amplatzer occlusion device: preliminary results. *J Am Coll Cardiol* 1998;31:1110-6.
7. Wilson NJ, Smith J, Prommete B, O'Donnell C, Gentles TL, Ruygrok PN. Transcatheter closure of secundum atrial septal defects with the Amplatzer septal occluder in adults and children -follow-up closure rates, degree of mitral regurgitation and evolution of arrhythmias. *Heart Lung Circ* 2008;17:318-24.
8. Chen CR, Cheng TO. Percutaneous balloon mitral valvuloplasty by the Inoue technique: a multicenter study of 4832 patients in China. *Am Heart J* 1995;129:1197-203.
9. Cheng TO, Holmes DR Jr. Percutaneous balloon mitral valvuloplasty by the Inoue balloon technique: the procedure of choice for treatment of mitral stenosis. *Am J Cardiol* 1998;81:624-8.
10. Cheng TO. Coexistent atrial septal defect and mitral stenosis (Lutembacher syndrome): An ideal combination for percutaneous treatment. *Catheter Cardiovasc Interv* 1999;48:205-6.
11. Stefanadis CI, Stratos CG, Lambrou SG, Bahl VK, Cokkinos DV, Voudris VA, et al. Retrograde nontransseptal balloon mitral valvuloplasty: immediate results and intermediate long-term outcome in 441 cases-a multicenter experience. *J Am Coll Cardiol* 1998;32:1009-16.