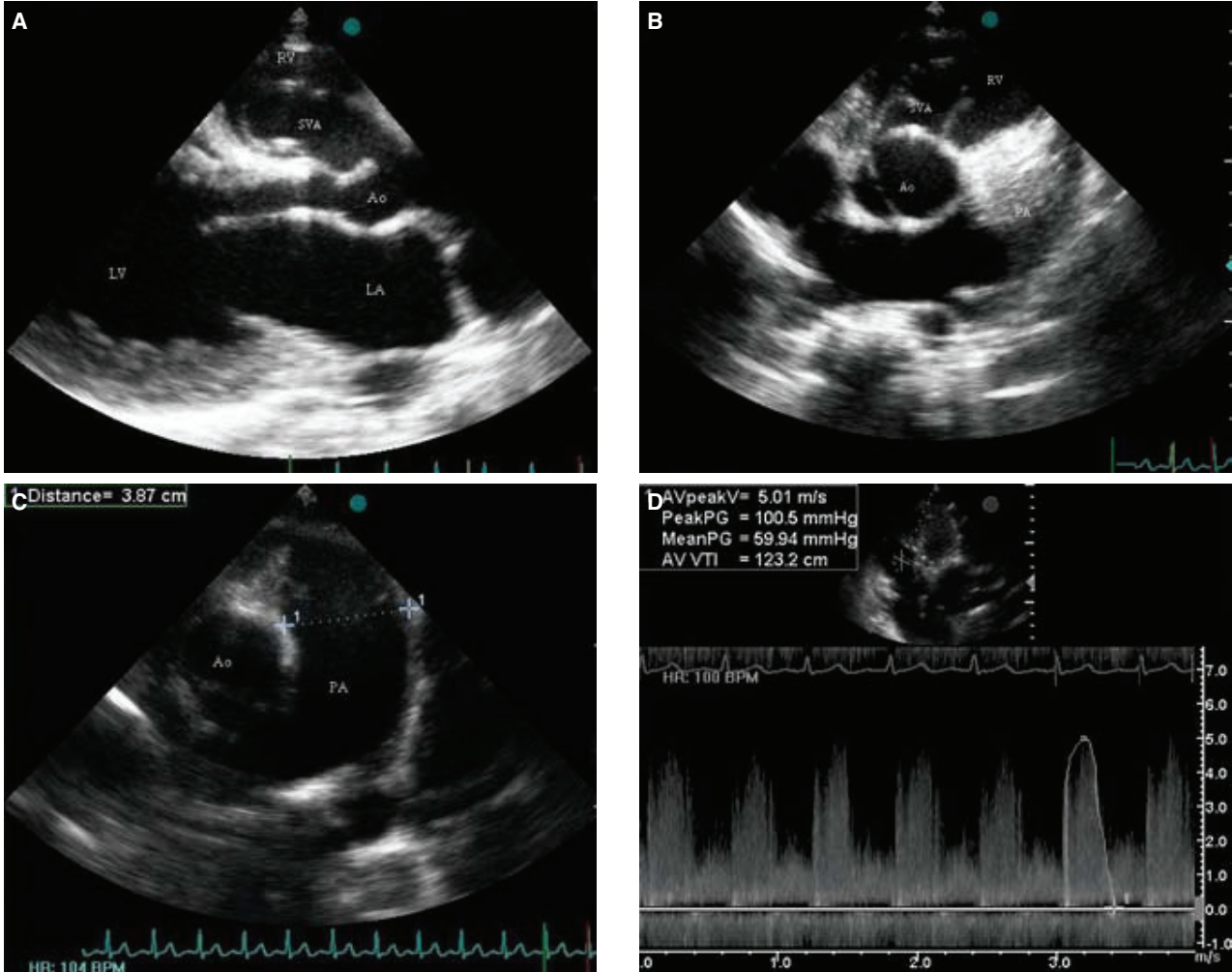


## Ruptured aneurysm of the right sinus of Valsalva protruding into the right ventricle

## Sağ ventriküle açılan, yırtılmış sağ sinüs Valsalva anevrizması



Anıl Avcı  
Aytekin Aksakal  
Mustafa Güler<sup>1</sup>  
Ali Metin Esen

Departments of  
Cardiology and  
Cardiovascular  
Surgery,  
Kartal Koşuyolu  
Cardiovascular  
Research and  
Training Hospital,  
İstanbul

A 23-year-old woman presented with complaints of palpitation and mild-to-moderate dyspnea on exertion. A grade 3/6 continuous heart murmur, best audible over the left second intercostal space, was detected on physical examination. The electrocardiogram showed sinus tachycardia of 120 bpm. Other physical examination findings and lab-

oratory test results were unremarkable. Transthoracic echocardiography performed to detect the cause of heart murmur revealed a mobile right sinus of Valsalva aneurysm (SVA) extending into the right ventricle (Fig. A, B). Another important echocardiographic finding was enlargement of the pulmonary artery (3.87 cm) (Fig. C). Color flow Doppler showed a left-to-right cardiac shunt and, by continuous wave Doppler, the peak and mean pressure gradients between the right SVA and the right ventricle were measured as 100 mmHg and 60 mmHg, respectively (Fig. D). The patient was referred for early cardiac surgery.

**Figures.** Transthoracic echocardiographic images: (A) Parasternal long-axis view showing a right sinus of Valsalva aneurysm (SVA) extending into the right ventricle. (B) Parasternal short-axis view showing SVA arising from the right coronary cusp of the aorta. (C) Short-axis view showing enlargement of the pulmonary artery. (D) Continuous flow Doppler showing the gradient between the right SVA and the right ventricle. LA: Left atrium; LV: Left ventricle; RV: Right ventricle; Ao: Aorta; SVA: Sinus of Valsalva aneurysm; PA: Pulmonary artery.