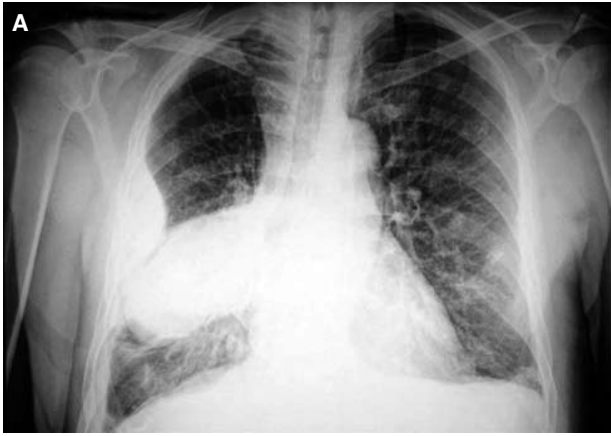

Görüntülü olgu örnekleri

Case images

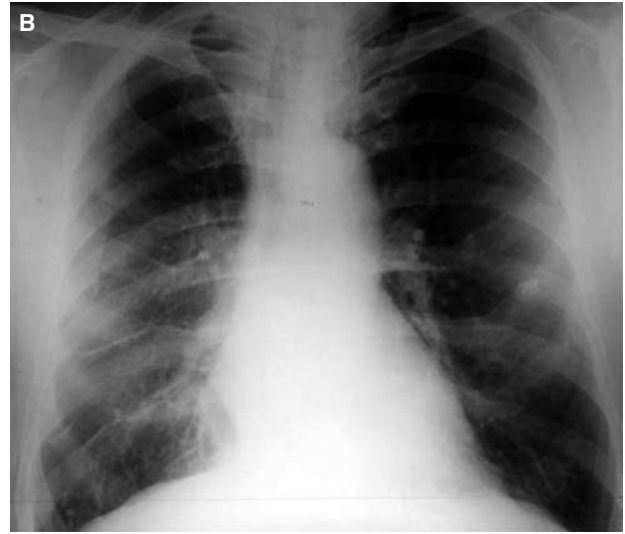
Phantom tumor of the lung
in a patient with preserved
left ventricular systolic functionSol ventrikül sistolik fonksiyonu
korunmuş bir hastada
akciğerin hayalet tümörü

Cengiz Çeliker
Farid Aliyev
Cengizhan Türkoğlu
İşıl Uzunhasan

Department of Cardiology,
İstanbul University,
Institute of Cardiology,
İstanbul

Phantom tumor of the lung refers to the accumulation of fluid in the interlobar spaces as a result of congestive heart failure, giving the radiological appearance of a neoplasm. Rapid radiological improvement in response to treatment for heart failure is a classical feature

of this clinical entity. A 55-year-old male patient with a past history of inferior myocardial infarction presented with symptoms of heart failure. Chest radiography revealed a spherical mass in the middle lobe of the right lung, obscuring the right side of the cardiac silhouette (Fig. A). Echocardiographic evaluation showed preserved left ventricular systolic function with ejection fraction of 50%, akinetic segments in the



basal and middle parts of the inferior wall, and signs of restrictive type of diastolic dysfunction ($E/A=4.5$, $DT 90$ msec). An increase in diuretic dose resulted in improvement in the patient's symptoms and disappearance of phantom tumor (Fig. B). Although phantom tumor is generally believed to occur in patients with systolic dysfunction, in our case, its appearance was secondary to diastolic dysfunction. Right heart border is not obscured in patients with phantom tumor and this feature helps distinguish it from atelectasis; however, in our patient, the right border of the heart was completely obscured.

Figures. (A) Spherical mass in the middle lobe of the right lung. (B) Disappearance of phantom tumor after initiation of diuretic therapy.