

Coronary vasospasm and acute myocardial infarction induced by a topical capsaicin patch

Topikal kapsaisin yamasına bağlı gelişen koroner vazospazm ve akut miyokart enfarktüsü

Adnan Burak Akçay, M.D.,¹ Türkay Özcan, M.D., Sabri Seyis, M.D., Armağan Acele, M.D.

¹Department of Cardiology, Medicine Faculty of Mustafa Kemal University, Hatay;

Department of Cardiology, Medicine Faculty of Mersin University, Mersin

Capsaicin is the active component of chili peppers, which has been shown to possess several beneficial effects. Currently, the best-known medical use of capsaicin is as a topical painkiller. Drug-induced myocardial infarction is not a common phenomenon and the underlying mechanism has been related with coronary spasm in the majority of cases. We present a 29-year-old man who experienced coronary vasospasm and acute myocardial infarction (AMI) which were possibly induced by the use of a topical capsaicin patch to relieve lumbago. He presented with chest pain of one hour onset. The electrocardiogram showed ST-segment elevation in the leads II, III, and aVF, consistent with inferior wall AMI. Echocardiography confirmed inferior hypokinesia. Urgent coronary angiography showed normal right and left coronary arteries. Since he had no cardiac risk factors for coronary artery disease, nor a history of recent emotional or physical stress, or ingestion of any illicit substance, the vasospasm and subsequent AMI was attributed to the use of the capsaicin patch for six days. Upon institution of appropriate treatment and removal of the patch, no new anginal attacks or ischemic episodes were seen within a follow-up of one month. This is the first case report of AMI induced by the use of a topical capsaicin patch.

Key words: Capsaicin/adverse effects; coronary vasospasm/chemically induced; myocardial infarction/chemically induced.

Capsaicin and related compounds are called capsaicinoids and are produced as a secondary metabolite by chili peppers, which are plants that belong to the genus *Capsicum*. Topical capsaicin is an alternative application in patients with muscle-skeletal pain, who do not tolerate nonsteroidal anti-inflammatory drugs because of side effects. Capsaicin is a potent analgesic

Kapsaisin, yararlı birçok etkisi olduğu gösterilen acı kırmızıbiberin aktif bileşenidir. Günümüzde topikal ağrıkesici olarak kullanılmaktadır. İlaç kullanımı ile ilişkili miyokart enfarktüsü sık görülen bir durum değildir ve olguların çoğunda altta yatan mekanizma koroner vazospazm ile ilişkilidir. Bu yazıda, bel ağrısını dindirmek için topikal kapsaisin yaması kullandığı sırada koroner vazospazm ve sonrasında akut miyokart enfarktüsü (AME) geçiren 29 yaşında bir erkek hasta sunuldu. Göğüs ağrısı başladıktan bir saat sonra başvuran hastanın elektrokardiyogramında, II, III, ve aVF derivasyonlarında inferiyor duvar enfarktüsü ile uyumlu ST-segment yükselmesi izlendi. Ekokardiyografik incelemede inferiyor hipokinezi görüldü. Acil koroner anjiyografide hastanın sağ ve sol koroner arterleri normal bulundu. Hastada koroner arter hastalığı için hiçbir risk faktörü, yakın zamanda yaşanmış duygusal veya fiziksel sıkıntı veya herhangi bir yasak madde alımı gibi bir durum olmadığından, vazospazm ve sonrasındaki AME, altı gündür kullanmakta olduğu kapsaisin yamasına bağlandı. Uygun tedaviye başlanması ve yamanın çıkarılması sonrasında, hastada bir aylık takip süresi içinde herhangi bir anjina atağı veya iskemik epizot görülmedi. Sunulan olgu, topikal kapsaisin yamasına bağlı olarak AME geliştiği bildirilen ilk olgudur.

Anahtar sözcükler: Kapsaisin/yan etki; koroner vazospazm/kimyasal yolla oluşan; miyokart enfarktüsü /kimyasal yolla oluşan.

substance which, when applied topically or injected into the skin, can produce pain, hyperalgesia, and analgesia.^[1] Capsaicin seems to have quite complex neurochemical effects on the nervous system. When applied directly to an area of pain source, capsaicin empties the stores of inflammatory mediators from the nerve endings so that they can no longer transmit

Received: November 11, 2008 Accepted: March 12, 2009

Correspondence: Dr. Adnan Burak Akçay, Mustafa Kemal Üniversitesi Tıp Fakültesi, Kardiyoloji Anabilim Dalı, 31000 Hatay, Turkey. Tel: +90 326 - 229 10 00 e-mail: burakakcay2002@myynet.com

pain signals to the brain. Animal studies have shown that capsaicin prevents binding of certain carcinogens to DNA, suggesting that it may be used as a potential anti-cancer drug.^[2]

We present a case of coronary vasospasm and acute myocardial infarction (AMI) which were possibly induced by the use of a topical capsaicin patch, a condition that has not been previously reported.

CASE REPORT

A 29-year-old man presented to our clinic with a complaint of chest pressure, one hour after the onset of pain. The electrocardiogram (ECG) showed ST-segment elevation of 2.5 mm in the leads II, III, and aVF, consistent with inferior wall AMI (Fig. 1). Echocardiography confirmed inferior hypokinesia. The patient was alert, his blood pressure was 130/85 mmHg, pulse rate was 78 beats/min, and respiration was 23/min. Heart sounds were normal without a gallop sound or significant murmur. He had no cardiac risk factors for coronary artery disease and he was a nonsmoker. He denied any history of recent emotional or physical stress. The initial cardiac enzyme levels were normal, but then showed a crescendo-decrescendo pattern with a peak troponin T value of 1.7 ng/ml (normal <0.01 ng/ml). The patient was diagnosed as having inferior AMI, and appropriate treatment was instituted including aspirin, loading-dose clopidogrel, low-dose metoprolol, sublingual nitroglycerin, and unfractionated heparin. Primary percutaneous intervention was planned. His chest pain was relieved at the beginning of angiography. Urgent diagnostic coronary angiography showed normal right and left coronary arteries (Fig. 2). His chest pain recurred twice after coronary angiography. During anginal attacks, serial electrocardiograms showed dynamic changes as a response to intravenous nitroglycerin

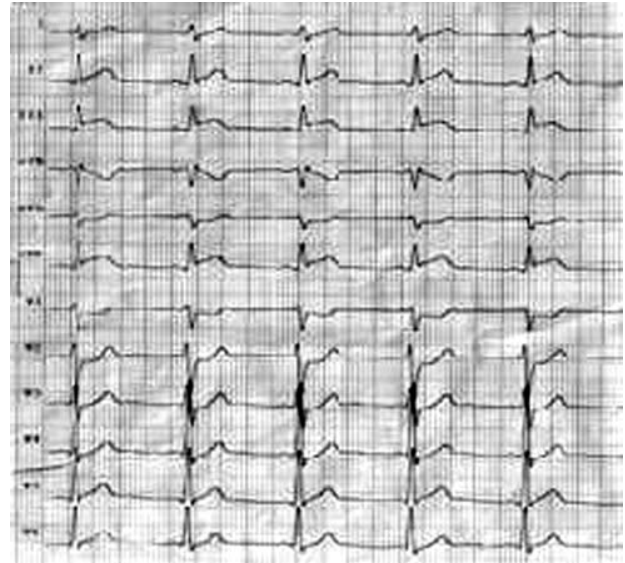


Figure 1. The electrocardiogram showing ST-segment elevation in the leads II, III, and aVF.

administration, which were similar to those seen on admission ECG. His detailed history showed no use of legal or illegal substances. On physical examination, a topical painkiller patch with capsaicin was noted in the middle of his back, which had been there for six days to relieve lumbago (Fig. 3). The patch was removed and the patient was switched from beta-blocker therapy to a calcium antagonist, and there were no new ischemic episodes. One month later, he had no anginal attacks and echocardiography showed mild hypokinesia of the inferior wall.

DISCUSSION

The characteristic effects of capsaicin (excitation, desensitization, and neurotoxicity) may be of therapeutic value. Of these, stimulation (counterirrita-

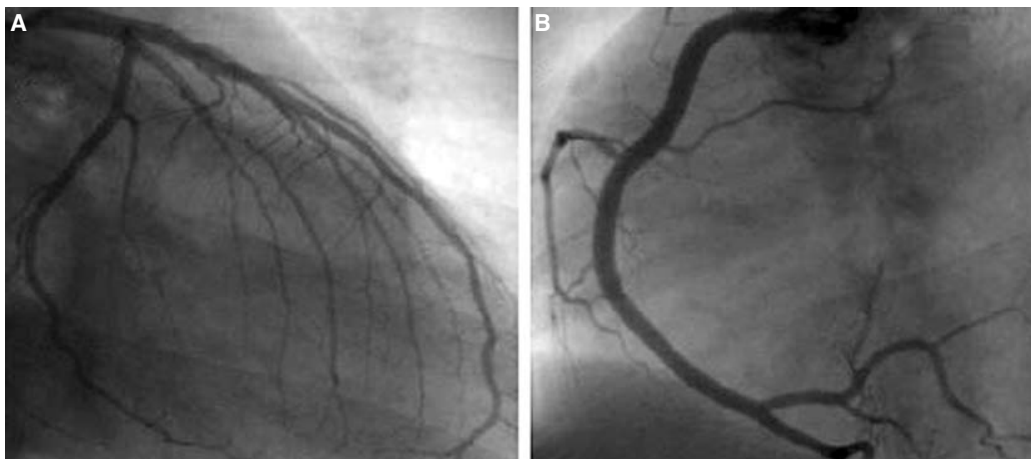


Figure 2. Coronary angiograms showing normal (A) right and (B) left coronary arteries.

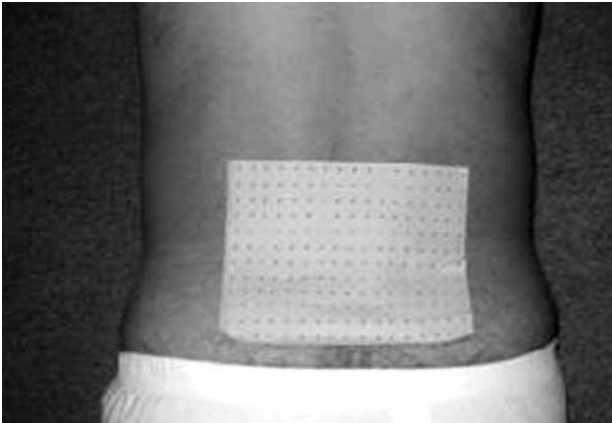


Figure 3. Topical painkiller patch with capsaicin attached in the middle of the back.

tion) and desensitization have been used in clinical practice. Cancer patients with unresponsive pain may benefit from perineural capsaicin injection for ablation of C-fibers.^[1] At present, capsaicin is utilized as a topical painkiller. It is believed that it relieves pain by decreasing substance P levels in the treatment of neuropathic pain. Creams with capsaicin are used as painkillers for conditions such as herpes (shingles), arthritis, and neuralgia.^[2]

Drug-induced AMI secondary to coronary artery spasm occurring in teenagers and young adults is mainly related to cigarette smoking, marijuana use, alcohol intake, butane inhalation, and cocaine use.^[3] Zimmerman et al.^[4] examined 8,839 patients with myocardial infarction (MI), of which 294 (3%) were males aged ≤ 35 years. In comparison with older patients, young patients often had patent coronary arteries, normal angiography or nonobstructive lesions. Smoking and a positive family history of coronary artery disease were the risk factors in young patients, whereas diabetes and hypertension were more prevalent in older patients.^[4]

Most of the illicit substances are known to cause intense coronary vasospasm through exaggerating the vasospastic activity of other drugs, enhancing endothelial dysfunction, increasing platelet aggregation and sympathetic activity, and decreasing myocardial oxygen supply.^[5,6] In our patient, there was no history of substance abuse.

Okumura et al.^[7] observed in their study that substance P infusion dilated the spasm-related arteries of patients with coronary spastic angina to a degree similar to that in the control group, indicating that endothelium-dependent dilator response is preserved at the site of coronary spasm by way of substance P

receptor. Szolcsányi et al.^[8] showed that the majority of the effects of capsaicin in the rat heart were mediated by neural endothelin release. In our patient, we attributed the occurrence of vasospasm and AMI to the longer use of the topical patch than recommended (up to two days) in the prospectus, which possibly decreased substance P level and/or neural endothelin release, predisposing to vasospasm.

Coronary angiography is the standard diagnostic tool in patients presenting with angina pectoris at rest with transient ST-segment elevation. In most cases with clinical and electrocardiographic signs of acute coronary events, the diagnosis is based on the patency of coronary arteries on elective coronary angiography.^[9,10] Since provocation of coronary artery spasm after MI carries a high risk, we did not perform a provocation test in our patient. Our patient had no cardiac risk factors and his chest pain began after six days of topical capsaicin use. Improvement in clinical and electrocardiographic findings and relief of chest pain after removing the patch supported the role of capsaicin in the development of coronary vasospasm through decreasing substance P level.

In conclusion, since capsaicin has a wide use with many indications, it should be recalled that it may be responsible for adverse cardiovascular effects in the absence of illicit substance use especially in young patients. This is the first case report of coronary vasospasm and AMI induced by topical capsaicin patch.

REFERENCES

1. LaMotte RH, Lundberg LE, Torebjörk HE. Pain, hyperalgesia and activity in nociceptive C units in humans after intradermal injection of capsaicin. *J Physiol* 1992; 448:749-64.
2. Szallasi A, Blumberg PM. Vanilloid (Capsaicin) receptors and mechanisms. *Pharmacol Rev* 1999;51:159-212.
3. El Menyhar AA. Drug-induced myocardial infarction secondary to coronary artery spasm in teenagers and young adults. *J Postgrad Med* 2006;52:51-6.
4. Zimmerman FH, Cameron A, Fisher LD, Ng G. Myocardial infarction in young adults: angiographic characterization, risk factors and prognosis (Coronary Artery Surgery Study Registry). *J Am Coll Cardiol* 1995; 26:654-61.
5. Lange RA, Cigarroa RG, Flores ED, McBride W, Kim AS, Wells PJ, et al. Potentiation of cocaine-induced coronary vasoconstriction by beta-adrenergic blockade. *Ann Intern Med* 1990;112:897-903.
6. Pederson KJ, Kuntz DH, Garbe GJ. Acute myocardial ischemia associated with ingestion of bupropion and pseudoephedrine in a 21-year-old man. *Can J Cardiol*

- 2001;17:599-601.
7. Okumura K, Yasue H, Ishizaka H, Ogawa H, Fujii H, Yoshimura M. Endothelium-dependent dilator response to substance P in patients with coronary spastic angina. *J Am Coll Cardiol* 1992;20:838-44.
 8. Szolcsányi J, Oroszi G, Németh J, Szilvássy Z, Tószaki A. Endothelin release by capsaicin in isolated working rat heart. *Eur J Pharmacol* 1999;376:247-50.
 9. Tun A, Khan IA. Myocardial infarction with normal coronary arteries: the pathologic and clinical perspectives. *Angiology* 2001;52:299-304.
 10. Williams MJ, Restieaux NJ, Low CJ. Myocardial infarction in young people with normal coronary arteries. *Heart* 1998;79:191-4.