

Prosthetic mechanic valve thrombosis in pregnant women: a report of two cases

Gebelerde mekanik protez kapak trombozu: İki olgu sunumu

Mehmet Tuğrul İnanç M.D., Orhan Dođdu M.D., Mehmet Güngör Kaya M.D., Ali Dođan M.D.

Erciyes University Faculty of Medicine, Cardiology Department, Kayseri

Patients with prosthetic mechanical heart valves should always be on prophylactic anticoagulation therapy for thromboembolic events. As pregnancy represents a high-risk period for thrombosis, those with mechanical heart valves should be accorded greater importance. We presented two pregnant patients with prosthetic mechanical mitral valves, who developed mechanical valve thrombosis while on fractionated and unfractionated heparin treatment, respectively. One patient received intensive anticoagulation treatment, and the other underwent redo valve replacement. Both patients were free of symptoms.

Key words: Anticoagulants; heart valve prosthesis; heparin/adverse effects; mitral valve; pregnancy complications, cardiovascular; thrombosis/etiology.

Anticoagulation therapy is the most commonly encountered problem in pregnant women who underwent prosthetic mechanical valve replacement. Guidelines recommend the use of warfarin up to the 36th week of pregnancy, excluding the period between the 6th and 12th weeks. On the other hand, daily warfarin treatment at a dose of 5 mg or lower reduces the risk of valve thrombosis in the mother to a lower degree, in the absence of fetal malformation risk.^[1,2]

Although warfarin protects the mother from thromboembolic complications, it may lead to embryopathy, prematurity and abortion. Though heparin use is not associated with the risk of embryopathy, the incidence of thromboembolic complications may be more than that observed with warfarin. In this article we presented thromboembolic complications and subsequent problems encountered in pregnant women who have undergone prosthetic mechanical valve replacement, with no history of thromboembolism, and who regularly used warfarin before pregnancy, but used unfractionated heparin or low molecular weight heparin following pregnancy.

Mekanik kalp kapađı olan hastalarda tromboembolik olaylara yönelik profilaksi için antikoagülasyon tedavisinin ömür boyu sürdürülmesi gerekir. Gebelik tromboza yatkınlık oluşturan yüksek riskli bir dönem olduğundan, protez kalp kapađı takılmış olan gebe hastalar ayrıca önem kazanmaktadır. Bu yazıda, mitral protez kapak nedeniyle fraksiyone olan ve olmayan heparin kullanımı sırasında kapak trombozu gelişen iki gebe olgu sunuldu. Olgulardan biri yoğun antikoagülasyonla, diđeri ise acil kapak deđişimi ile başarılı şekilde tedavi edildi.

Anahtar sözcükler: Antikoagülan; kalp kapađı protezi; heparin/yan etki; mitral kapađı; gebelik komplikasyonu, kardiyovasküler; tromboz/etyoloji.

CASE PRESENTATION

Case 1 – A thirty-year patient who was 8 weeks pregnant, presented with complaints of speech disorder, syncope, loss of strength in the right upper and lower extremities, and dyspnea to our clinic. Her history revealed that she underwent prosthetic mitral replacement of two valves as a result of mitral stenosis and mitral insufficiency. The patient reported that warfarin treatment was stopped with pregnancy, and that she was started on a 20.000 unit dose of unfractionated heparin. The physical examination revealed that the patient was orthopedic, with disorientation of place and time, and was not cooperative. The heart rate was 110/min, and blood pressure was 100/50 mmHg; the prosthetic valve click sound was found to be weak. In the patient's neurological examination there was a 3/5 degree hemiparesia in the right lower and upper extremities, dysphagia and the presence of a mixed type dysphasia. Her transthoracic echocardiography demonstrated an echogenicity consistent with a 1.1x1.0 cm thrombus on the prosthetic valve, adjacent to the point where the valve-ends meet. In her Doppler evaluation a pressure difference of a

Received: 12.12.2007 Accepted: 21.03.2008

Corresponding address: Dr. Mehmet Tuğrul İnanç. Erciyes Üniversitesi Tıp Fakültesi, Kardiyoloji Anabilim Dalı, Talas Yolu 38039 Kayseri.
Tel: +90 352 – 437 49 37 e-mail: mtinanc@msn.com

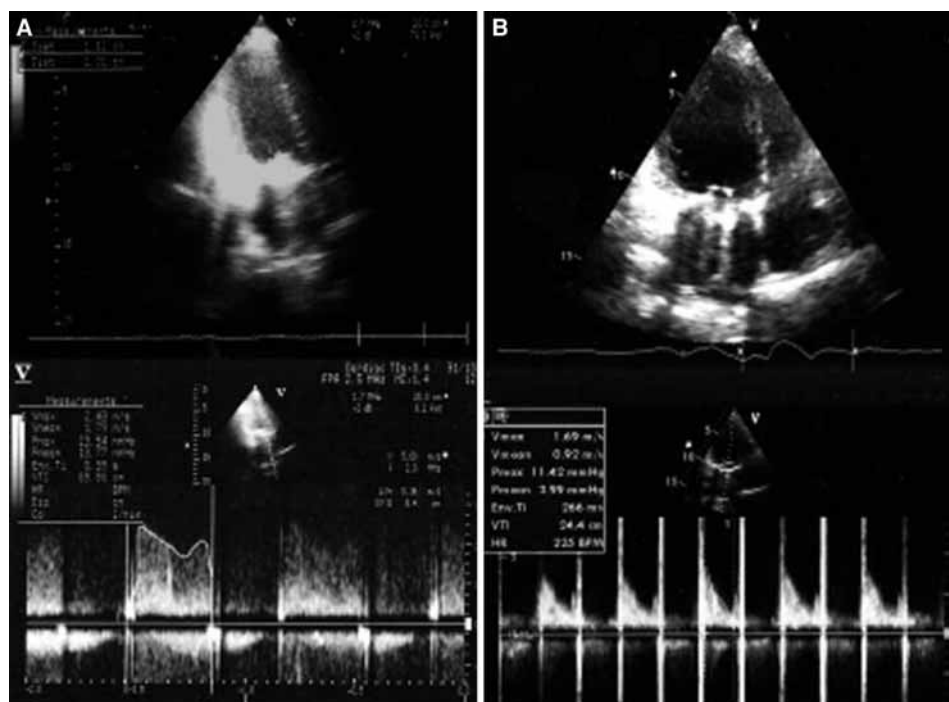


Figure 1 (A). A thrombus with a size of 1.0x1.1 cm is seen on the mechanic valve, and a pressure difference of 23 mmHg maximum, and of 13 mmHg average is observed at the level of the valve. **(B)** During the first month of follow-up period after treatment of the same patient, the thrombus on the valve was seen to have disappeared completely and no serious narrowness was observed (pressure difference; maximum 11 mmHg, average 3 mmHg).

maximum of 23 mmHg, and an average of 13 mmHg, was identified caused by thrombus on the valve which inhibited the valve to open. On the other hand, a moderate insufficiency was observed in the aortic valve. The patient's activated partial thromboplastin time (aPTT) was measured as 40.5 sec, whereas the prothrombin time (PTT)-INR valve was measured as 1.29 sec. The patient's cranial computerized tomography (CT) was obtained by placing a lead barrier in the abdominal region, thereby protecting the fetus from X-rays. Results of the investigation did not demonstrate any finding consistent with cerebral hemorrhage and the patient was started on heparin infusion. The aPTT value reached the expected effective value (60-80 sec) within a few days; and the patient's complaints of loss of strength, speech difficulty and dyspnea started to regress. The patient's neurological problems were linked to the thromboembolism on the patient's prosthetic mitral valve. Reversion to subcutaneous heparin was not initiated throughout the discharging period and 5 mg/day oral warfarin was initiated. The thrombus of the valve was found to have disappeared during the control echocardiography, and the pressure difference on the valve was found to be 13 mmHg maximum, and 3 mmHg average (Figure 1). The INR value was regulated at 2.5 and the patient was discharged and placed under strict follow-up. The fetus was reported to continue normal development.

Case 2 – A 31-year-old female patient visited our clinic with complaints of cough and dyspnea, which started within the past 24 hours. Her history revealed a double mitral valve prosthetic replacement that was performed two years ago and a live birth delivery from a cesarean section two days ago. The patient reported using a subcutaneous enoxaparine 0.8 ml single dose daily throughout her pregnancy, and that the click sound from the prosthetic valve had reduced. The physical examination revealed that the patient was orthopneic, had sinus tachycardia and S3 was present; the heart rate was 120/min and blood pressure was 100/60 mmHg. Click sounds from the mechanic prosthetic valve were very faint and widespread rales could be heard from the base of the lungs. In her transthoracic echocardiography an image of 1x1.4 cm was observed on the prosthetic mitral valve that was consistent with a thrombus. Her Doppler evaluation demonstrated a pressure difference of 31 mmHg maximum and 23 mmHg average. Administration of 2000-units dose of heparin infusion, intravenous furosemide, and nitrate treatment was initiated. However, an emergency valve replacement was performed following worsening of the general condition of the patient, together with the development of hypotension during the follow-up period. During the post-operative period heparin infusion was started followed by the initiation of warfarin treatment. The patient was discharged with instructions after the regulation of the INR values above 2.5.

DISCUSSION

During pregnancy there is a physiological general increase in the volume of body water and in heart rate, and also a decrease in peripheral vascular resistance. In pregnant women with mechanic prosthetic valve replacement, these changes are generally well tolerated. However, in the event of left ventricular dysfunction these changes may lead to a decrease in the patient's functional capacity, to pulmonary edema, and even may cause life threatening findings of heart failure.^[3-6] The change in the estrogen-progesterone balance, increase in factor VIII and fibrinogen levels, decrease in the level of protein S and the accumulation of blood in the lower extremities due to vena cava compression during pregnancy may all lead to an increase in thromboembolic events. The latest guidelines recommend the use of warfarin up to the 36th week of pregnancy, excluding the period between week 6 and 12, in order to prevent mechanical valve thrombosis.^[2]

In the cases presented, mechanical prosthetic valve replacement was performed before pregnancy and there was regular use of warfarin. However, on the physician's recommendation warfarin was stopped and unfractionated heparin was initiated in the first case, and low molecular weight heparin was initiated in the second case. Although there was no valvular thrombosis before pregnancy in our patients, the prosthetic valve led to thrombosis as a result of the propensity of pregnancy for thrombosis and also due to the use of unfractionated heparin and low molecular weight heparin, instead of warfarin. Similar cases have also been reported in our country. Tuygun et al.^[7] successfully performed valve replacement on a patient with mitral valve thrombosis by the 27th week of pregnancy. Ulaş et al.^[8] in their study also identified valvular thrombosis after administering low molecular weight heparin in a 3.5 month pregnant woman, and successfully performed a valve replacement. A case similar to our second case was reported by Koçak et al.^[9] A 35-week pregnant woman visited due to mitral valve thrombosis and an elective valve replacement was performed on the 8th day following delivery.

Classical guidelines recommend the evaluation of aPTT twice a day, during the use of unfractionated heparin, in order to provide adequate anticoagulation in patients with prosthetic mechanical valves. Guidelines also recommend the evaluation of anti-Xa when administering low molecular weight heparin to a pregnant woman.^[2] In our first case the level of aPTT was evaluated and found to be low; however, anti-Xa was not evaluated in the other case. Both types of heparin do not lead to fetal hemorrhage and teratogenicity, since they do not cross the placenta. As a result both heparins may be considered to be safer than warfarin. However, pregnant women using unfractionated heparin or low molecular weight heparin have been found to have a 12-24% higher risk of developing thromboembolic complications, such as life threatening valvular thrombosis, when compared to warfarin.^[10,11] Although low molecular

weight heparin seems to be more advantageous than unfractionated heparin due to ease of use and fewer side effects, evidence is lacking for its ability to prevent mechanical valve thrombosis in pregnant women.

Valvular repair should always be preferred to replacement with a prosthetic valve, in patients with valve lesions suitable for this repair. However, in cases where valvular repair is not possible, prosthetic valve replacement should be performed. The choice of the type of prosthetic valve in women of child bearing age has always been controversial. Although bioprosthetic valves do not need anticoagulation, they are prone to rapid degeneration during the early stage. Pregnancy accelerates this process and a second surgical operation is necessary due to damage to the valve at an early stage. On the other hand, mechanical valves are preferred due to their greater robustness and their durability. However, due to the constant need for anticoagulation, they may threaten the current pregnancy and future anticipated pregnancies.^[12] Mechanical valve thrombosis has been reported in patients with mechanical prosthetic valve at an average rate of 13% (7%-23%).^[4,13-15] This complication is mostly observed in the older generation valves which are located at the mitral position and are structurally more thrombogenic (Bjork-Shiley, Starr-Edwards). However, mechanical valve thrombosis can also be found in the new generation valves.^[16-22]

New generation double-leaf mechanical prosthetic valves were implanted in our patients before pregnancy. Our patients were regularly using warfarin and no previous thromboembolic event was reported. Following initiation of heparin administration after pregnancy, mechanical valve thrombosis associated with inadequate anticoagulation in the patients was observed. Warfarin is a safe drug which can be used for the prevention of thromboembolic events during pregnancy. Warfarin at a dose of 5 mg or lower prevents thromboembolic events in the pregnant women during the first six weeks of pregnancy, and also from the 12th week right up to birth. On the other hand, warfarin-associated embryopathy can be observed only in approximately 5% of cases between the 6th and 12th week of pregnancy, and the risk is dose related. Recent data have demonstrated that the risk of embryopathy or abortion is very low with the use of doses less than 5 mg. Fractionated heparin may be used as an alternative to warfarin during the 6th-12th weeks.

In conclusion, patients with mechanical prosthetic valves who are planning pregnancy should be informed about thromboembolic complications associated with anticoagulation therapy changes, and they should discuss and decide with their physician before choosing the anticoagulation therapy to be used during pregnancy.

REFERENCES

1. Vahanian A, Baumgartner H, Bax J, Butchart E, Dion R, Filippatos G, et al. Guidelines on the management of valvular heart disease: The Task Force on the Management of Valvular Heart Disease of the European Society of Cardiology. *Eur Heart J* 2007;28:230-68.
2. Bonow RO, Carabello BA, Kanu C, de Leon AC Jr, Faxon DP, Freed MD, et al. ACC/AHA 2006 guidelines for the management of patients with valvular heart disease: a report of the American College of Cardiology/American Heart Association Task Force on Practice Guidelines. *Circulation* 2006;114:e84-231.
3. Sadler L, McCowan L, White H, Stewart A, Bracken M, North R. Pregnancy outcomes and cardiac complications in women with mechanical, bioprosthetic and homograft valves. *BJOG* 2000;107:245-53.
4. Sbarouni E, Oakley CM. Outcome of pregnancy in women with valve prostheses. *Br Heart J* 1994;71:196-201.
5. Caruso A, de Carolis S, Ferrazzani S, Paradisi G, Pomini F, Pompei A. Pregnancy outcome in women with cardiac valve prosthesis. *Eur J Obstet Gynecol Reprod Biol* 1994;54:7-11.
6. Bhatla N, Lal S, Behera G, Kriplani A, Mittal S, Agarwal N, et al. Cardiac disease in pregnancy. *Int J Gynaecol Obstet* 2003;82:153-9.
7. Tuygun AK, Olsun A, Yurtseven N, Karaca P, Çiloğlu U, Tuygun A ve ark. Gebelik ve açık kalp cerrahisi: iki ucu keskin kılıç. *Türk Göğüs Kalp Damar Cer Derg* 2004;12:262-4.
8. Ulaş MM, Çağlı K, Çetin E, Boysan E, Mavioğlu L, Sarıtaş A. Mitral kapak replasmanı sonrası ikinci gebeliği esnasında tromboza bağlı mekanik kapak disfonksiyonu nedeniyle opere edilen bir hasta. *Anadolu Kardiyol Derg* 2005;5:240-1.
9. Koçak T, Güzelmeriç F, Oğuş H, Orki T, Erkiş A. Mitral protez kapak disfonksiyonu ve pulmoner hipertansiyonu olan gebede acil sezaryen operasyonunda anestezi yaklaşım (olgu sunumu). *Anestezi Dergisi* 2006;14:269-72.
10. Ginsberg JS, Hirsh J. Use of antithrombotic agents during pregnancy. *Chest* 1995;108(4 Suppl):305S-311S.
11. Elkayam UR. Anticoagulation in pregnant women with prosthetic heart valves: a double jeopardy. *J Am Coll Cardiol* 1996;27:1704-6.
12. Jamieson WR, Miller DC, Akins CW, Munro AI, Glower DD, Moore KA, et al. Pregnancy and bioprostheses: influence on structural valve deterioration. *Ann Thorac Surg* 1995;60(2 Suppl):S282-6.
13. Hanania G, Thomas D, Michel PL, Garbarz E, Age C, Millaire A, et al. Pregnancy in patients with heart valve prosthesis. A French retrospective cooperative study (155cases). *Arch Mal Coeur Vaiss* 1994;87:429-37. [Abstract]
14. Born D, Martinez EE, Almeida PA, Santos DV, Carvalho AC, Moron AF, et al. Pregnancy in patients with prosthetic heart valves: the effects of anticoagulation on mother, fetus, and neonate. *Am Heart J* 1992;124:413-7.
15. Lee CN, Wu CC, Lin PY, Hsieh FJ, Chen HY. Pregnancy following cardiac prosthetic valve replacement. *Obstet Gynecol* 1994;83:353-6.
16. Behrendt P, Schwartzkopff B, Perings S, Gerhardt A, Zotz RB, Strauer BE. Successful thrombolysis of St. Jude medical aortic prosthesis with tissue-type plasminogen activator in a pregnant woman: a case report. *Cardiol Rev* 2002;10:349-53.
17. Lev-Ran O, Kramer A, Gurevitch J, Shapira I, Mohr R. Low-molecular-weight heparin for prosthetic heart valves: treatment failure. *Ann Thorac Surg* 2000;69:264-5.
18. Berndt N, Khan I, Gallo R. A complication in anticoagulation using low-molecular weight heparin in a patient with a mechanical valve prosthesis. A case report. *J Heart Valve Dis* 2000;9:844-6.
19. Rowan JA, McCowan LM, Raudkivi PJ, North RA. Enoxaparin treatment in women with mechanical heart valves during pregnancy. *Am J Obstet Gynecol* 2001;185:633-7.
20. Anbarasan C, Kumar VS, Latchumanadhas K, Mullasari AS. Successful thrombolysis of prosthetic mitral valve thrombosis in early pregnancy. *J Heart Valve Dis* 2001;10:393-5.
21. Sahnoun-Trabelsi I, Jimenez M, Choussat A, Roudaut R. Prosthetic valve thrombosis in pregnancy. A single-center study of 12 cases. *Arch Mal Coeur Vaiss* 2004;97:305-10. [Abstract]
22. Kutay V, Kirali K, Ekim H, Yakut C. Postoperatif erken dönem mekanik mitral kapak trombozları: 5 farklı tip protezin analizi. *Türk Göğüs Kalp Damar Cer Derg* 2003;11:163-8.