

New alternatives to the standard Doppler method in measuring transmitral pressure gradient

Transmitral basınç farkının saptanmasında standart Doppler yöntemine yeni seçenekler

Mesut Demir, M.D., Onur Akpınar, M.D., Mehmet Kanadaşı, M.D., Esmeray Acartürk, M.D.

Department of Cardiology, Medicine Faculty of Çukurova University, Adana

Objectives: Mitral valve pressure gradient measured by echocardiography is a very useful method for the evaluation of mitral valve disease. The standard method is based on the calculation of mean mitral valve pressure gradient with the use of the modified Bernoulli equation, which includes manual drawing of the border of Doppler signal. Recently, two new methods have been described by Devlin M et al. and Yang SS, respectively. This study aimed to compare the results of the standard method with those of the new methods.

Study design: We prospectively studied 78 patients (55 women, 23 men; mean age 43±14 years; range 17 to 78 years) with mitral valve gradient either due to mitral stenosis or mitral valve replacement. Atrial fibrillation was present in 31 patients. The mean mitral valve gradient was measured using the standard method. As for the new methods, measurements of the mean mitral valve gradient were made without manual drawing of the border of Doppler signal and using the formulas which included the peak and trough velocities. Transmitral gradient was also obtained by cardiac catheterization in 14 patients.

Results: The mean transmitral pressure gradients were 9.2±5.7 mmHg, 9.4±6.2 mmHg, and 10.6±6.6 mmHg by the standard method, the first, and the second methods, respectively. The new methods were in good correlation with the standard method (for both methods, $r=0.98$, $p<0.001$). Subgroup analyses based on mitral valve area, rhythm, and the presence of associated valve lesions did not change the consistency of correlations. Transmitral gradients obtained by catheterization were also correlated with those obtained by the standard, first, and second methods ($r=0.97$, $r=0.96$, $r=0.96$, respectively).

Conclusion: Considering that the standard Doppler method and two different approaches yield similar results, the new approaches seem to facilitate the measurement of mitral valve gradient in daily clinical practice.

Key words: Blood flow velocity; echocardiography, doppler; mitral valve/ultrasonography; mitral valve stenosis/ultrasonography.

Amaç: Ekokardiyografik olarak ölçülen transmitral basınç farkı mitral kapak hastalarının kapak fonksiyonlarını değerlendirmede kullanılan önemli bir yöntemdir. Geleneksel yöntemde modifiye Bernoulli eşitliğinden yararlanılarak elde edilen ortalama transmitral basınç farkı, pulse Doppler sinyal sınırlarının elle çizilmesine dayanır. Son zamanlarda, bu ölçüm için sırasıyla Devlin M ve ark. ve Yang SS tarafından daha kolay iki yöntem tanımlanmıştır. Bu çalışmada geleneksel yöntemle yeni yöntemlerin karşılaştırılması amaçlandı.

Çalışma planı: Mitral darlığı veya mitral kapak replasmanı nedeniyle mitral kapak üzerinde basınç farkı oluşan 78 hasta (55 kadın, 23 erkek; ort. yaş 43±14; dağılım 17-78) prospektif olarak incelendi. Hastaların 31'inde atriyal fibrilasyon vardı. Tüm hastalarda geleneksel yöntemle ortalama transmitral basınç farkı bulundu. Yeni yöntemler için, pulse Doppler akım trasesinin sınırları elle çizilmeden, sadece tepe ve orta hızlar ölçüldü, tanımlanan formüller yardımıyla ortalama transmitral basınç farkı hesaplandı. Transmitral basınç farkı ayrıca 14 hastada kardiyak kateterizasyon sırasında da ölçüldü.

Bulgular: Standart yöntemle, birinci ve ikinci yöntemle ölçülen ortalama transmitral basınç farkları sırasıyla 9.2±5.7 mmHg, 9.4±6.2 mmHg ve 10.6±6.6 mmHg bulundu. Yeni yöntemlerin standart yöntemle iyi bir korelasyon gösterdiği görüldü (her iki yöntem için, $r=0.98$, $p<0.001$). Altgrup incelemelerinde, ritim türü, mitral kapak alanı ve eşlik eden lezyon varlığının bu uyumun derecesini değiştirmediği görüldü. Standart yöntem, birinci ve ikinci yöntemlerle ölçülen ortalama transmitral basınç farkları, kardiyak kateterizasyon sonuçlarıyla da uyumlu bulundu (sırasıyla, $r=0.97$, $r=0.96$, $r=0.96$).

Sonuç: Standart Doppler yönetimiyle ve iki yöntemle hesaplanan sonuçların benzer bulunması nedeniyle, yeni yöntemlerin günlük klinik uygulamada transmitral basınç farkının hesaplanmasını kolaylaştırdığı söylenebilir.

Anahtar sözcükler: Kan akım hızı; ekokardiyografi, Doppler; mitral kapağı/ultrasonografi; mitral kapağı darlığı/ultrasonografi.

Received: November 10, 2006 Accepted: December 20, 2006

Correspondence: Dr. Mesut Demir, Çukurova Üniversitesi Tıp Fakültesi, Kardiyoloji Anabilim Dalı, 01330 Adana.
Tel: 0322 - 338 60 60 Faks: 0322 - 338 69 33 e-mail: mdemir@cu.edu.tr

The timing of interventions for mitral stenosis (MS) and mitral valve replacement (MVR) is based on clinical status and the severity of anatomic lesion.^[1] The severity of stenosis can be estimated by measuring mitral valve area and transmitral pressure gradient. Previously, cardiac catheterization was used as an accurate invasive method to obtain transmitral pressure gradient.^[2] However, transthoracic Doppler echocardiography has been shown to be a reliable, reproducible, and accurate method of measuring transmitral pressure gradient for MS and MVR.^[3-5] The standard method for calculation of transmitral pressure gradient is a variation of the modified Bernoulli equation.^[6] In this method, manual drawing of the border of Doppler signal may sometimes be difficult. Recently, two easier methods have been introduced for the measurement of transmitral pressure gradient.^[7,8] The aim of this study was to assess the correlation between standard and these new methods in determining transmitral pressure gradient.

PATIENTS AND METHODS

Patients. We prospectively studied 78 patients (55 females, 23 males; mean age 43 ± 14 years; range 17 to 78 years) with mitral valve gradient either due to MS or MVR, all of whom had a good quality of echocardiographic images. All patients were informed of the nature of the study and their consent was obtained. The study was also approved by the ethics committee. After physical examination and 12-lead electrocardiographic recordings, the patients underwent transthoracic echocardiography.

Echocardiographic examination. The patients were assessed using an Acuson Sequoia C 256 echocardiography device (Acuson Corporation, Mountain View, CA, USA) and a 2.5- or 3.5-MHz transducer. Echocardiographic images were obtained from apical windows with the patients in the left lateral recumbent position. All recordings were obtained at the end of expiration to get good quality images. M-mode measurements were performed according to the recommendations of the American Society of Echocardiography.^[9] In the short-axis view, mitral valve area was obtained at the smallest valve orifice in early diastole by using the planimetric method. Transmitral inflow velocities were recorded by continuous wave Doppler echocardiography from the apical four-chamber view. Valve gradients were estimated by averaging five beats in sinus rhythm and seven in atrial fibrillation. The mean mitral valve gradients were measured by the standard and the new methods. Spectral Doppler was

traced and analyzed using the software package on Acuson Sequoia C 256 echocardiography device to determine the mean transmitral gradients for the standard method (Fig. 1), which involved the application of the modified Bernoulli equation.^[6]

Only peak (V_p) and trough (V_T) velocities were measured to obtain the mean transmitral gradients (ΔP_M) for the new methods (Fig. 2). The mean mitral valve gradient was calculated using the following two formulas for the first^[7] and second^[8] methods, respectively:

$$(i) \Delta P_{M1} = 1/3 (4V_p^2) + 2/3 (4V_T^2)$$

$$(ii) \Delta P_{M2} = 4/3 (V_p^2 + V_p V_T + V_T^2).$$

The presence of mitral regurgitation was assessed by color Doppler flow mapping. The severity of regurgitation was evaluated in multiple views and graded from 0 to 4 according to the size and extent of the regurgitant jet within the left atrium (1=trace, 2=mild, 3=moderate, and 4=severe).^[10] The presence and severity of aortic regurgitation (grades 0 to 4) were evaluated based on the ratio of cross-sections of the proximal regurgitant color jet and the left ventricular outflow tract, as described previously.^[10]

Transmitral gradient could be obtained by cardiac catheterization only in 14 patients.

Statistical analysis. Statistical analysis was performed using SPSS for Windows version 8.0. All values were expressed as mean \pm SD. Student's t-test was used to compare the corresponding mean values. Correlations between the standard and new methods were sought by the Pearson's correlation test. A p value of less than 0.05 was considered statistically significant.

RESULTS

The clinical and echocardiographic characteristics of the patients are shown in Table 1.

Table 1. Clinical and echocardiographic characteristics of the patients

	No.	%	Mean \pm SD
Male	23	29.5	
Female	55	70.5	
Age			43 \pm 14
Atrial fibrillation	31	39.7	
Sinus rhythm	47	60.3	
Aortic regurgitation	31	39.7	
Mitral regurgitation	24	30.8	
Native valve	49	62.8	
Prosthetic valve	29	37.2	
Planimetric mitral valve area (cm ²)			1.3 \pm 0.4
Left atrial diameter (mm)			54.6 \pm 13.3
Left ventricular diastolic diameter (mm)			48.7 \pm 9.1
Ejection fraction (%)			63.1 \pm 8.2

Table 2. Correlations in the measurement of mitral valve gradient between the methods used

	Mean transmitral gradient (mmHg)			r1	r2	r3
	Standard method	First method ^[7]	Second method ^[8]			
Atrial fibrillation	8.3±3.9	8.0±4.1	9.0±4.5	0.94*	0.94*	0.99*
Sinus rhythm	9.8±6.6	10.2±7.2	11.3±7.6	0.99*	0.99*	0.99*
Mitral regurgitation (+)	9.9±6.3	10.3±6.5	11.5±7.0	0.98*	0.98*	0.99*
Mitral regurgitation (-)	8.9±5.5	8.9±6.1	9.9±6.4	0.98*	0.98*	0.99*
Aortic regurgitation (+)	11.3±6.5	11.7±7.1	12.9±7.6	0.98*	0.98*	0.99*
Aortic regurgitation (-)	7.8±4.7	7.8±5.1	8.7±5.4	0.97*	0.97*	0.99*
Mitral valve area (≥1.5 cm ²)	9.8±4.2	9.6±4.5	10.6±4.4	0.94*	0.92*	0.99*
Mitral valve area (<1.5 cm ²)	15.8±6.3	16.4±7.1	17.9±7.4	0.97*	0.97*	0.99*
Native valve	10.9±6.1	11.2±6.6	12.3±7.0	0.97*	0.97*	0.99*
Prosthetic valve	6.4±3.7	6.3±4.1	7.1±4.5	0.98*	0.98*	0.99*

* p<0.001; r1: Correlation between the standard and first method, r2: Correlation between the standard and second method, r3: Correlation between the first and second method.

The mean transmitral gradients by the standard, the first and the second methods were found to be 9.2±5.7 mmHg, 9.4±6.2 mmHg, and 10.6±6.6 mmHg, respectively. There were good correlations between the standard method and the two new meth-

ods (for both methods, r=0.98, p<0.001). When the patients were divided into groups of MS and MVR, a good correlation existed between the standard method and the two methods. Similar findings were also found in patients with sinus rhythm and atrial

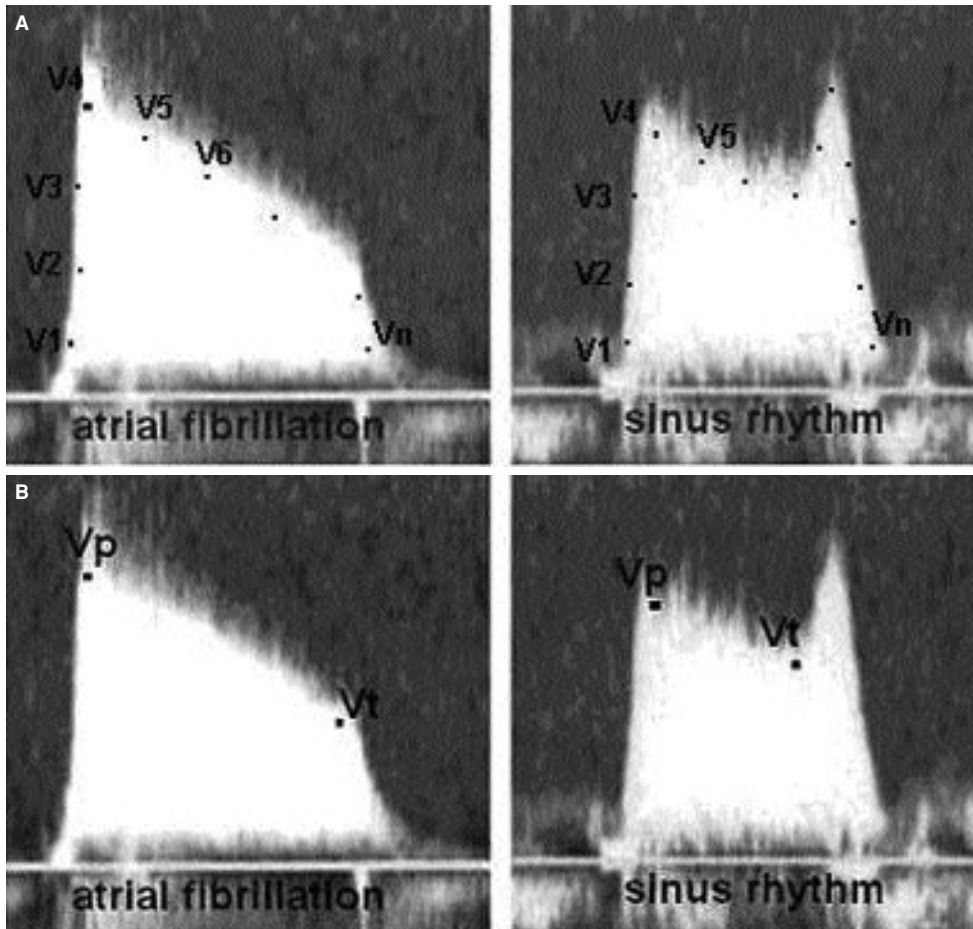


Figure 1. (A) Tracing of the Doppler signal in the standard method. **(B)** Determination of only peak (V_p) and trough (V_t) velocities in the new methods.

fibrillation (Table 2). Correlations did not change in the presence of aortic and mitral regurgitation.

Transmitral gradients obtained by catheterization in 14 patients were also correlated with those obtained by the standard, first, and second methods ($r=0.97$, $r=0.96$, $r=0.96$, respectively).

DISCUSSION

The severity of mitral stenosis can be determined by measuring mitral valve area and transmitral pressure gradient. Previously, cardiac catheterization was used as an accurate invasive method to obtain transmitral pressure gradient.^[2] However, in 1976, Holen et al.^[11] showed that the pressure gradient across a stenotic mitral valve may be calculated from Doppler ultrasonic measurements of blood velocity in the mitral jet. Later, Hatle et al.^[6] found a good correlation between Doppler measurements and simultaneous pressure recordings during heart catheterization. Other studies have shown that transthoracic Doppler echocardiography is well correlated with catheterization and provides a reliable, reproducible, and accurate method of measuring transmitral pressure gradient in MS and MVR patients.^[3-5] A variation of the modified Bernoulli equation is used as a standard method for calculation of mean transmitral pressure gradient by echocardiography.^[6] In this method, manual drawing of the border of Doppler signals may sometimes be difficult and time-consuming. Recently, Devlin et al.^[7] described a new method and a formula for obtaining mean transmitral pressure gradient. They found a good correlation between the standard method and the new one. Two years later, Yang SS^[8] reported that this method might be inappropriate for patients with atrial fibrillation and described another formula.

In our study, we evaluated these two alternative methods in comparison with the standard one. We found good correlations between the standard method and the new formulas regardless of mitral valve area, rhythm, and the presence of aortic regurgitation, mitral regurgitation, mitral stenosis, or mitral valve replacement. Moreover, we also found a good correlation between cardiac catheterization and these new methods, which was not reported previously.

In conclusion, the mean transmitral pressure gradient detected by the standard Doppler method and

two different approaches yield similar results. Although all these methods can be used to evaluate mitral valve gradient, new approaches seem to facilitate the measurement of mitral valve gradient in daily clinical practice.

REFERENCES

1. Bonow RO, Carabello BA, Kanu C, de Leon AC Jr, Faxon DP, Freed MD, et al. ACC/AHA 2006 guidelines for the management of patients with valvular heart disease. *Circulation* 2006;114:e84-231.
2. Braunwald E. Valvular heart disease. In: *Heart disease: a textbook of cardiovascular medicine*. 5th ed. Philadelphia: W. B. Saunders; 1997. p. 1007-76.
3. Henry WL, Griffith JM, Michaelis LL, McIntosh CL, Morrow AG, Epstein SE. Measurement of mitral orifice area in patients with mitral valve disease by real-time, two-dimensional echocardiography. *Circulation* 1975;51:827-31.
4. Loperfido F, Laurenzi F, Gimigliano F, Pennestri F, Biasucci LM, Vigna C, et al. A comparison of the assessment of mitral valve area by continuous wave Doppler and by cross sectional echocardiography. *Br Heart J* 1987;57:348-55.
5. Martin RP, Rakowski H, Kleiman JH, Beaver W, London E, Popp RL. Reliability and reproducibility of two-dimensional echocardiograph measurement of the stenotic mitral valve orifice area. *Am J Cardiol* 1979;43:560-8.
6. Hatle L, Brubakk A, Tromsdal A, Angelsen B. Noninvasive assessment of pressure drop in mitral stenosis by Doppler ultrasound. *Br Heart J* 1978;40:131-40.
7. Devlin M, Jacobs LE, Oliner CM, Owen AN, Ioli A, Abbrescia VD, et al. A novel approach to calculation of mean mitral valve gradient by Doppler echocardiography. *J Am Soc Echocardiogr* 2001;14:1107-11.
8. Yang SS. A novel approach to calculation of mean atrial valve gradient by Doppler echocardiography. *J Am Soc Echocardiogr* 2003;16:297-8.
9. Sahn DJ, DeMaria A, Kisslo J, Weyman A. Recommendations regarding quantitation in M-mode echocardiography: results of a survey of echocardiographic measurements. *Circulation* 1978;58:1072-83.
10. Feigenbaum H. *Acquired valvular heart disease*. In: *Echocardiography*. 5th ed. Philadelphia: Lea & Febiger; 1994. p. 251-92.
11. Holen J, Aaslid R, Landmark K, Simonsen S. Determination of pressure gradient in mitral stenosis with a non-invasive ultrasound Doppler technique. *Acta Med Scand* 1976;199:455-60.