



Ophthalmic Features of a Rare Case of Costeff Syndrome

Costeff Sendromlu Nadir Bir Olgunun Oftalmik Özellikleri

Özge Temizyürek¹, Metin Ünlü¹, Hidayet Şener², Murat Gültekin³

¹Erciyes University Faculty of Medicine, Department of Ophthalmology, Kayseri, Türkiye

²Cukurca State Hospital, Clinic of Ophthalmology, Hakkari, Türkiye

³Erciyes University Faculty of Medicine, Department of Neurology, Kayseri, Türkiye

Keywords: Costeff syndrome, OPA3 mutation, optic atrophy

Anahtar Kelimeler: Costeff sendromu, OPA3 mutasyonu, optik atrofi

Dear editor,

Costeff syndrome, also known as 3-methylglutaconic aciduria (MGA) type 3, was first reported by Costeff in 1989. A 19-year-old Israeli patient with early-onset bilateral optic atrophy, movement problems, and motor disability from the first decade of life has been reported (1). Costeff syndrome is inherited as autosomal recessive and develops because of a mutation in the *OPA3* gene. In patients with Costeff syndrome, the amount of MGA excretion in the urine increases due to the disruption of leucine catabolism. Diagnosis is by molecular genetic tests and urine organic acid analysis (2).

A 22-year-old female patient was admitted to the neurology clinic because of unsteadiness while walking. Even though the patient could currently walk without support, she had gait ataxia that had occurred during childhood and increased over the years. During a neurological examination of the patient, deep tendon reflexes were normoactive in the upper extremities and hyperactive in the lower extremities. Muscle strength was 4/5 in the bilateral upper and lower extremities, and bilateral Babinski reflexes were positive. There was no spasticity, but gate ataxia existed. The patient did not have extrapyramidal involvement. Motor and sensory nerve conduction velocities were normal in an electromyography test. The patient's cranial magnetic resonance findings were evaluated as normal, and cerebellar atrophy was not observed. The genetic test for Friedreich's ataxia was normal. The patient was consulted in the ophthalmology clinic due to poor vision. The best

bilaterally corrected visual acuity was counting fingers from three meters. There was bilateral horizontal nystagmus, and optic disc pallor that was more prominent in the bilateral temporal sector was diagnosed during a retinal examination (Figure 1). In a retinal nerve fiber layer (RNFL) analysis, it was observed that the RNFL in the temporal sectors was thinner according to age (Figure 2). In a visual evoked potential (VEP) test, prolonged bilateral latencies were observed (Figure 3). In a genetic analysis, the p.Gln108_Glu113del (c.322_339delCAGCGCCACAAGGAGGAG) variant was observed as homozygous in the *OPA3* gene. Biallelic variants in this gene have been reported to cause 3-MGA type 3. While this variant was found to be heterozygous in the patient's parents and homozygous in only patient's symptomatic sibling among three siblings, it was not detected in the others. The patient and her family were directed to genetic counseling for family planning.

The gene responsible for type-3 MGA is the *OPA3* gene. The *OPA3* protein is a mitochondrial protein. Studies have shown that mitochondrial activity is highest in the optic nerve, retinal ganglion cell layer, plexiform layers of the retina, photoreceptor cell layer and retinal pigment epithelium, cerebral cortex, cerebellum, and frontal lobe (3,4). Since the intraocular part of the optic nerve is unmyelinated, it is particularly dependent on energy for transmitting action potential. Therefore, optic nerve atrophy is common in mitochondrial disorders caused by *OPA3* gene mutation (5). By the same mechanism, spasticity, ataxia, dysarthria, and cognitive impairment develop due to damage in

Address for Correspondence/Yazışma Adresi: Özge Temizyürek MD, Erciyes University Faculty of Medicine, Department of Ophthalmology, Kayseri, Türkiye
Phone: +90 506 835 86 77 E-mail: ozgetemizyurek@gmail.com ORCID: orcid.org/0000-0002-6099-994X

Received/Geliş Tarihi: 14.06.2022 **Accepted/Kabul Tarihi:** 02.09.2022

©Copyright 2023 by Turkish Neurological Society
Turkish Journal of Neurology published by Galenos Publishing House.

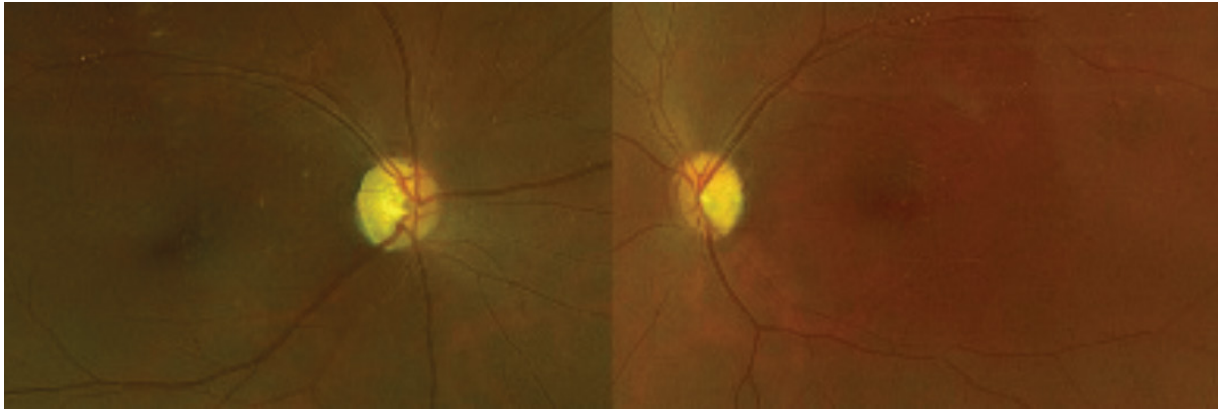


Figure 1. Color fundus images of the patient’s right and left optic discs, respectively. Bilateral optic discs appear pale

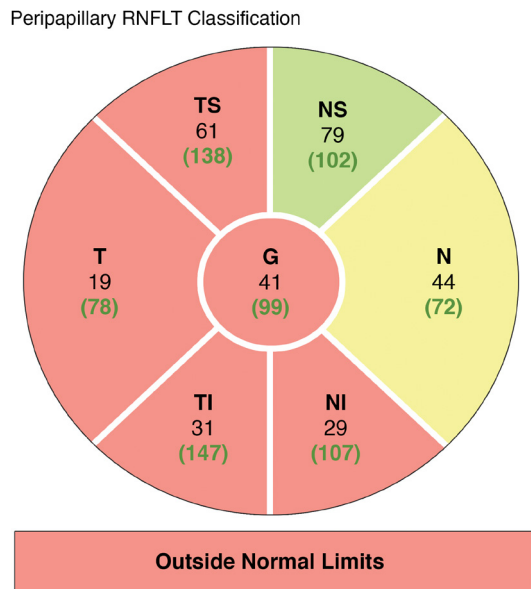


Figure 2. Optical coherence tomography image of the right eye: 4.1 mm diameter peripapillary circle with decreased retinal nerve fiber layer thickness (since the patient had nystagmus, RNFL analysis could be performed only on the right eye)
 RNFLT: Retinal nerve fiber layer thickness

neurons that provide movement control with a high mitochondrial requirement (4,5). In such patients, VEP test results show a prolongation of latency and thinning of the vessels in the papilla, consistent with optic atrophy (1). Patients with horizontal nystagmus accompanying optic atrophy have low visual acuity, and the course of the disease is relatively slow and stable (2).

Leber’s hereditary optic neuropathy with mitochondrial DNA mutation and autosomal dominant optic atrophy should be among the differential diagnoses (5). Behr syndrome is the neurodegenerative disease most often confused with Costeff syndrome. OPA1 mutation is observed in Behr syndrome; however, unlike in Costeff syndrome, no extrapyramidal dysfunction is observed. In the literature, Anikster et al. (6) identified the c.143-1G > C mutation in DNA samples, and Nystuen et al. (7) showed a relation to chromosome 19q13.2-q13.3 for Costeff syndrome (8). Additionally, differential diagnosis is made by urine organic acid analysis (2).

Since there is no specific treatment for Costeff syndrome, treatment comprises multidisciplinary support and symptomatic therapy. Tobacco, alcohol, and some drugs that impair mitochondrial function should be avoided. Prenatal genetic counseling is recommended for all affected individuals and their families.

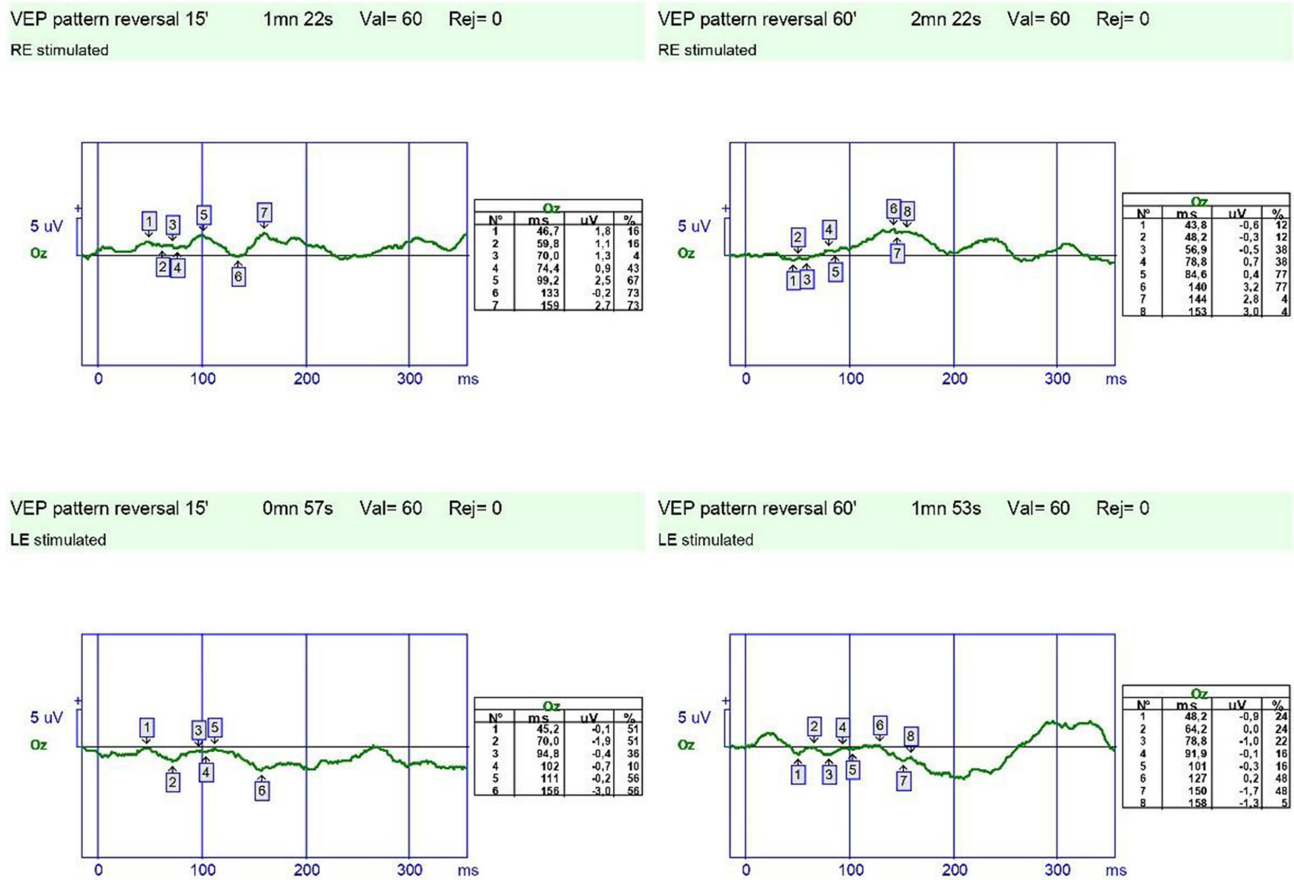


Figure 3. 15' and 60' model visual evoked potentials test image showing decreased amplitudes (P100 wave R15': 2.5 µV,R60': 3.2 µV and L15': faint signal, L60': 0.2 µV) and prolonged latency (P100 wave R15': 99 ms, R60': 140 ms and L15' faint signal, L60': 127 ms)

Ethics

Informed Consent: Written consent was obtained.

Peer-review: Externally peer-reviewed.

Authorship Contributions

Concept: M.Ü., Design: M.G., Data Collection or Processing:

Ö.T., Analysis or Interpretation: Ö.T., H.Ş, Literature Search:

Ö.T., Writing: Ö.T., H.Ş.

Conflict of Interest: No conflict of interest was declared by the authors.

Financial Disclosure: The authors declared that this study received no financial support.

References

1. Elpeleg ON, Costeff H, Joseph A, et al. 3-methylglutaconic aciduria in the Iraqi-Jewish 'optic atrophy plus' (Costeff) syndrome. *Dev Med Child Neurol* 1994;36:167-172.
2. Anikster Y. Costeff syndrome synonyms: 3-methylglutaconic aciduria type 3, OPA3 defect. <https://www.ncbi.nlm.nih.gov/books/NBK1473/>

3. Anikster Y, Kleta R, Shaag A, Gahl WA, Elpeleg O. Type III 3-methylglutaconic aciduria (optic atrophy plus syndrome, or Costeff optic atrophy syndrome): identification of the OPA3 gene and its founder mutation in Iraqi Jews. *Am J Hum Genet* 2001;69:1218-1224.
4. Pei W, Kratz LE, Bernardini I, et al. A model of Costeff syndrome reveals metabolic and protective functions of mitochondrial OPA3. *Development* 2010;137:2587-2596.
5. Carelli V, La Morgia C, Valentino ML, et al. Retinal ganglion cell neurodegeneration in mitochondrial inherited disorders. *Biochim Biophys Acta* 2009;1787:518-528.
6. Anikster Y, Kleta R, Shaag A, Gahl WA, Elpeleg O. Type III 3-methylglutaconic aciduria (optic atrophy plus syndrome, or Costeff optic atrophy syndrome): identification of the OPA3 gene and its founder mutation in Iraqi Jews. *Am J Hum Genet* 2001;69:1218-1224.
7. Nystuen A, Costeff H, Elpeleg ON, et al. Iraqi-Jewish kindreds with optic atrophy plus (3-methylglutaconic aciduria type 3) demonstrate linkage disequilibrium with the CTG repeat in the 3' untranslated region of the myotonic dystrophy protein kinase gene. *Hum Mol Genet* 1997;6:563-569.
8. Huna-Baron R, Yahalom G, Anikster Y, et al. Neuro-ophthalmic phenotype of OPA3. *J Neuroophthalmol* 2022;42:147-152.