



Raeder's Syndrome "Paratrigeminal Neuralgia" Beyond Headache: A Case Report

Baş Ağrısının Ötesinde Raeder's Sendromu "Paratrigeminal Nevralji": Olgu Sunumu

Gülnur Tekgöl Uzuner, Yasemin Dinç, Nevzat Uzuner

Eskişehir Osmangazi University Faculty of Medicine, Department of Neurology, Eskişehir, Turkey

Abstract

Raeder's syndrome (paratrigeminal neuralgia), which sometimes radiates to the maxillary section, is defined as a constant and unilateral pain in the distribution area of the ophthalmic branch of the trigeminal nerve accompanied by Horner's syndrome and caused by a defect in the carotid artery or in the middle cranial fossa. Although Raeder's syndrome is accompanied with the irritation of the trigeminal nerve, it can be easily confused with Horner's syndrome and mistakenly called "painful Horner's syndrome". This picture, which contains incomplete Horner's syndrome with orbital pain and without anhidrosis, is an important clinical entity because it shows the location of the lesion and is different from the etiologic and prognostic perspective. Due to these reasons, we wanted to present a patient who was diagnosed as having paratrigeminal oculosympathetic Raeder syndrome in our clinical department of neurology to draw attention to differences in underlying resemblance to Horner's syndrome.

Keywords: Raeder's syndrome (paratrigeminal neuralgia), Horner's syndrome, headache

Öz

Raeder's sendromu (paratrigeminal nevralsi) trigeminal sinirin oftalmik dalının dağılım alanında, bazen maksiller bölüme yayılan, Horner sendromunun eşlik ettiği ve orta kraniyal fossa veya karotis arterdeki bir bozukluğun neden olduğu, sabit, tek yanlı ağrı olarak tanımlanmaktadır. Raeder's sendromuna trigeminal sinir irritasyonu eşlik etmesine rağmen, kolaylıkla Horner sendromu ile karıştırılabilir ve ağrılı Horner sendromu olarak yanlış adlandırılabilir. Orbital ağrı ile birlikte inkomplet Horner sendromunu içeren bu tablo (anhidrozmadan), lezyonun yerini göstermesi, etiyolojik ve prognostik açıdan farklı olduğu için önemli klinik bir antitedir. Bu nedenle biz, nöroloji kliniğimizde paratrigeminal okülosempatik (Raeder) sendromu tanısı koyduğumuz bir olguyu, Horner sendromuna olan benzerliğinin altında yatan farklılıklarına dikkat çekmek amacıyla sunuyoruz.

Anahtar Kelimeler: Raeder's sendromu (paratrigeminal nevralsi), Horner sendromu, baş ağrısı

Introduction

Raeder reported five cases of ipsilateral headache and incomplete Horner's syndrome (without anhidrosis) in 1918 and 1924. The clinical picture was accompanied by parasellar cranial nerve involvement in these cases (1,2). Additionally, headache characteristics conformed to the distribution of the trigeminal nerve. Raeder attempted to localize the lesion at the paratrigeminal distribution or middle cranial fossa, and later the disease was called 'Raeder's syndrome' (2).

According to the International Classification of Headache Disorders 3 (ICHD-3) beta version diagnostic criteria released by the International Headache Society, Raeder's syndrome, which is caused by an impairment in the middle cranial fossa or carotid artery, is described as a constant, unilateral pain in the distribution area of ophthalmic branch of the trigeminal nerve, sometimes radiating to the maxillary region, and accompanied by Horner's syndrome (3).

Address for Correspondence/Yazışma Adresi: Gülnur Tekgöl Uzuner MD, Eskişehir Osmangazi University Faculty of Medicine, Department of Neurology, Eskişehir, Turkey
Phone: +90 530 884 95 27 E-mail: uzunergulnur@gmail.com

Received/Geliş Tarihi: 24.12.2015 **Accepted/Kabul Tarihi:** 08.05.2016

©Copyright 2017 by Turkish Neurological Society
Turkish Journal of Neurology published by Galenos Publishing House.

Horner's syndrome is characterized with ptosis, miosis and anhidrosis. The syndrome results from any damage to the sympathetic pathway on its course from the hypothalamus to the eye (4).

Although Raeder's syndrome is associated with trigeminal nerve irritation, it might easily be confused with Horner's syndrome and misinterpreted as painful Horner's syndrome (1).

We present a rare case of paratrigeminal oculosympathetic (Raeder's) syndrome to emphasize its differences from Horner's syndrome despite apparent similarities.

Case Report

A man aged 56 years presented with a unilateral, throbbing headache localized to the right orbital and frontal regions, which he had had for 3 months, that persisted for about half an hour, repeating 20-25 times during the day, and woke him from sleep. The patient reported no accompanying autonomic symptoms. A neurologic examination revealed right pupillary miosis, right ocular ptosis, and enophthalmos, which are signs of Horner's syndrome, in the right eye. Contrast-enhanced cranial magnetic resonance (MR) imaging was performed to exclude secondary causes of headache because the patient's headache started acutely after 50 years of age and was accompanied by focal neurologic signs and proved normal. Treatment with indomethacin was initiated after we diagnosed possible cluster headache and possible paroxysmal hemicrania continua in accordance with the diagnostic criteria of ICHD-3 beta, and switched to prednisolone upon unresponsiveness; however, the patient did not respond to the latter treatment either. Sphenopalatine ganglion blockade was performed, but no improvement was observed. Cervical MR and thorax computed tomography (CT) was planned for the etiologic investigation of Horner's syndrome. These tests also provided normal. In follow-up, the patient presented with neuralgiform pain radiating from the tragus to maxilla and mandibula on the right side of the face, pain radiating from the right mandibula angular region to the face, sensitivity to palpation, and swollen cheeks. Neck ultrasonography (USG) was planned with suspicion of parotiditis after consulting otolaryngology, which revealed multiple, conglomerated, heterogeneous lymph nodes without hilum in the right cervical region, the largest being 12x8 mm. Additionally, a reactive lymph node of 22x4.5 mm was observed in the submental region. Neck CT with contrast revealed contrast-enhanced pathologic lymph nodes in the right retropharyngeal area obliterating the right carotid artery (Figure 1). The patient was then diagnosed as having Raeder's syndrome in view of the clinical and radiologic findings. Lymph node biopsy was recommended by an otolaryngology specialist. Pathologic examination of the tissue samples resulted as squamous cell carcinoma with invasion of vascular and neural structures. The patient was diagnosed as having neck metastasis with unknown primary considered inoperable due to carotid invasion, and followed up by the clinic of otolaryngology. The patient died while the radiotherapy was being planned.

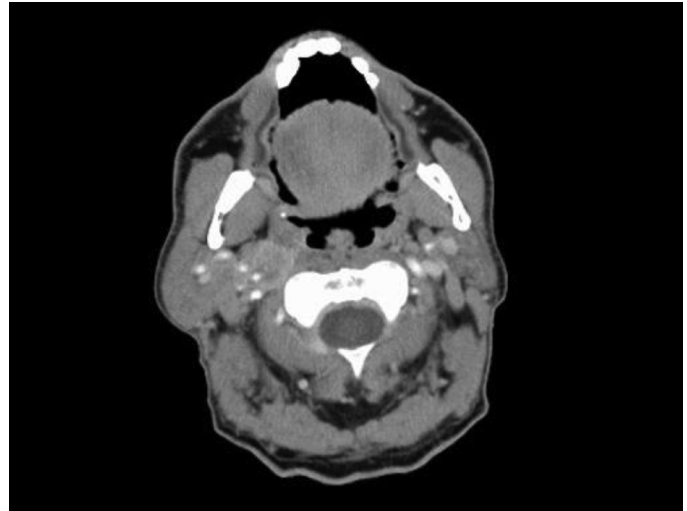


Figure 1. Cervical computed tomography with contrast shows contrast-enhanced pathologic lymph nodes in the right retropharyngeal area obliterating the right carotid artery.

Discussion

Our patient presented with unilateral headache and incomplete Horner's syndrome in the absence of anhidrosis. No clinical response could be obtained with standard cluster or paroxysmal hemicrania headache treatments. Neck USG and MR revealed lymph nodes obliterating the right carotid artery. The case conformed to the diagnostic criteria of Raeder's syndrome (3).

The exact incidence of Raeder's syndrome is not known (5). There is a limited number of cases reported in the literature. The syndrome has been associated with head trauma, hypertension, vasculitis, migrainous headaches, parasellar mass lesions, nasopharyngeal tumors, meningiomas, internal carotid artery dissection, and infections (6).

The majority of Raeder's syndrome cases are due to carotid artery dissection (2,5,6,7,8). Only one of the 5 cases reported by Raeder himself was associated with a middle cranial fossa tumor (endothelioma) (2). In 2010, Kirkova et al. (9) reported a case of paratrigeminal oculosymphathetic Raeder's syndrome secondary to cavernous segment invasion of a maxillary sinus tumor. With this case, the authors emphasized that paratrigeminal oculosympathetic Raeder's syndrome is not specific to carotid dissection (9).

In our case, the underlying etiology was found to be carotid artery invasion by a malignancy of unknown primary. Pathologic examination of the tumor revealed vascular and perineural invasion.

The pathophysiologic processes involved in the formation of Raeder's syndrome might be explained by cluster-type headache and oculosympathetic dysfunction resulting from pericarotid sterile neurogenic inflammation due to alteration in the venous drainage of the cavernous sinus upon triggering the trigeminovascular system (associated with the lateral sellar plexus inside the cavernous sinus) (10).

Pathologic lymph nodes surrounding the carotid lodge were considered to compress the sympathetic nerves on the internal carotid artery against the bony wall of the carotid canal, to cause

sympathetic dysfunction, and activation of the nociceptive nerve terminals via the trigeminal system.

This is an important clinical picture that encompasses orbital pain plus incomplete Horner's syndrome (without anhidrosis); it indicates lesion localization, and differs in terms of prognosis (1).

Third-line sympathetic neurons branch from the superior cervical ganglion and ascending carotid artery. Nerve fibers associated with facial perspiration branch from the main branches and course along the external carotid artery, and other third-line sympathetic fibers course along the internal carotid artery after the bifurcation. Therefore, preservation of facial perspiration in the presence of facial pain differentiates Raeder's syndrome from Horner's syndrome. These signs and symptoms of Raeder's syndrome allow localization of the lesion above the carotid bifurcation. Clinical pictures resulting from parasellar cranial nerve involvement enable localization of the lesion more specifically at the middle cranial fossa (11).

Pain in the trigeminal region indicates absence of sensory deficit because trigeminal fibers of the ophthalmic area are not influenced by the pathologic process. Parasympathetic function is also thought to be preserved, considering the course of intact pupillary visceral efferents along the oculomotor nerve. Pain radiating to the deep facial region, inferior of the orbital fossa, and nasal fossa might be associated with connections between the lateral sellar plexus and pterygopalatine ganglion (12).

Raeder's neuralgia might be a clinical presentation of dysfunction of the trigeminovascular system containing multiple connections within the lateral sellar plexus in the cavernous sinus and internal carotid artery (13).

Consequently, we suggest that more rapid diagnosis might be possible by starting imaging with the carotid artery and its surroundings in patients who present with partial Horner's syndrome and ipsilateral headache.

Ethics

Informed Consent: Consent form was filled out by all participants.

Peer-review: Externally and internally peer-reviewed.

Authorship Contributions

Surgical and Medical Practices: G.T.U., Y.D., N.U., Concept: G.T.U., Y.D., N.U., Design: G.T.U., Y.D., N.U., Data Collection or Processing: G.T.U., Y.D., N.U., Analysis or Interpretation: G.T.U., Y.D., N.U., Literature Search: G.T.U., Y.D., N.U., Writing: G.T.U., Y.D., N.U.

Conflict of Interest: No conflict of interest was declared by the authors.

Financial Disclosure: The authors declared that this study received no financial support.

References

- Goadsby PJ. Raeder's Syndrome: paratrigeminal paralysis of the oculopillary sympathetic system. *J Neurol Neurosurg Psychiatry* 2002;72:297-299.
- Reader JG. Paratrigeminal paralysis of the oculopupillary sympathetics. *Brain* 1924;126-138.
- Headache classification committee of the international headache society. The international classification of the headache disorders 3rd edition (beta version) *Cephalalgia* 2013;33:629-808.
- Jaffe NS. Localization of lesions causing Horner's syndrome. *Arch Ophthalmol* 1950;44:710-728.
- Grimson BS, Thomson HS. Raeder's syndrome; a clinical review. *Surv Ophthalmol* 1980;24:199-210.
- Murnane M, Proano L. Raeder's paratrigeminal syndrome: A case report. *Academic Emergency Medicine* 1996;3:864-867.
- Kashihara K, Ito H, Yamamoto S, Yamano K. Raeder's syndrome associated with intracranial internal carotid artery aneurysm. *Neurosurgery* 1987;20:49-51.
- Tatsui CE, Prevedello DM, Koerbel A, Cordeiro JG, Ditzel LF, Araujo JC. Raeder's syndrome after embolization of a giant intracavernous carotid artery aneurysm. *Arq Neuropsiquiatr* 2005;63:676-680.
- Kirkova V, Andreeva A, Cherninkova S, Tournev I, Dimitrov I, Oscar A. Raeder paratrigeminal syndrome in a patient with a mass lesion in the maxillary sinus. *Journal of IMAB-Annual Proceeding (Scientific Papers)* 2010;16:38-39.
- Dodick DW, Rozen TD, Goadsby PJ, Silberstein SD. Cluster headache. *Cephalalgia* 2000;20:787-803.
- Auer D, Karnath HO, Nagele T, Dichgans J. Noninvasive investigation of the pericarotid syndrome: role of magnetic resonance angiography in the diagnosis of internal carotid dissection. *Headache* 1995;35:163-168.
- Bleys RLAW, Janssen LM, Groen GJ. The lateral sellar nerve plexus and its connections in humans. *J Neurosurg* 2001;95:102-110.
- Maizels M, Geiger AM. Intranasal lidocaine for migraine: a random-ized trial and open-label follow-up. *Headache* 1999;39:543-551.