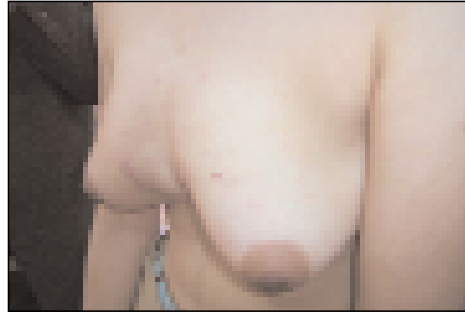
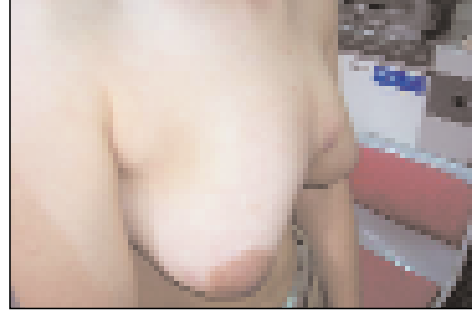
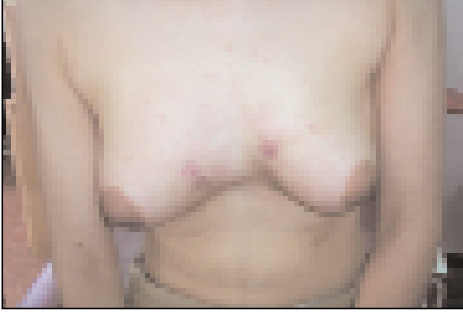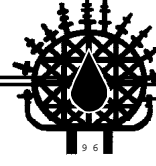


Images in Haematology

Edited by: Hamdi Akan M.D.



A 26 years old female was admitted to the hospital with masses in both breasts. Physical examination revealed a mass overlying the sternum involving the medial quadrants of both breasts. There were also lymphadenopathies in the right and left axillary regions. She was diagnosed as Hodgkin's lymphoma and received chemotherapy at that time. She had not received any treatment in the following two years. She became aware of the enlarging lesions 5 months ago. Laboratory examinations revealed a WBC: 17800/mm³, Hb: 8.6 g/dL, biochemical tests showed an albumin of 4.4 g/dL (4.5-5.5) and, LDH: 245 IU/L (98-192).

Thoracic CT showed a lobulary lesion in the anterior mediastin, destroying the sternum and compressing the heart with the longest diameter of 15 cm. There were multiple lymphadenopathies in the right axillary region of 4-5 cm in diameter. Abdominal CT was normal. The biopsy of the mass revealed nodulary sclerosing Hodgkin's disease. Bone marrow biopsy was found to be normal. She had B symptoms and received ABVD (adriamycin, bleomycin, vinblastine, dacarbazine) followed by the rapid resolution of the mass.

Turgay FEN¹, Başak GÖREN²

¹ Department of Hematology

Ankara Oncology Research and Education Hospital,

² Department of Internal Medicine

Ankara Oncology Research and Education Hospital,
Ankara, TURKEY