

OLGU SUNUMU**CASE REPORT****SPONTANEOUS CERVICAL CAROTID VASOSPASM IS A CAUSE FOR STROKE IN YOUNG ADULTS: NON-INVASIVE IMAGING**

Aylin AKÇALI, Ayhan ÖZKUR, Münife NEYAL, Abdurrahman NEYAL

Gaziantep Üniversitesi Tıp Fakültesi Nöroloji Anabilim Dalı, GAZİANTEP

ABSTRACT

We report a 21-year-old female who was admitted for right-hemiparesis. The first color Doppler ultrasonography (CDU) performed on the second day of admission revealed preocclusive stenosis in the proximal part of the left internal carotid artery (ICA). The magnetic resonance angiography (MRA) that was carried out on the same day couldn't visualize the left ICA. Magnetic resonance imaging (MRI) on the third day of admission revealed acute parenchymal ischemic lesion in the left hemisphere. Pulse methylprednisolone treatment was administered. On the third day of the treatment a second CDU and MRA showed a normal left ICA. The patient admitted for three more times with very similar clinical and radiological findings.

The clinical and radiological findings of the patient confirmed that vasospasms of cervical carotid arteries may be left unrecognized if the imaging studies are not performed promptly, and may cause ischemic stroke in young adults. MRA and CDU are non-invasive and relevant imaging techniques for immediate and follow-up evaluations in such cases.

Key Words: Recurrent, carotid artery, vasospasm, stroke, color Doppler ultrasonography, magnetic resonance angiography.

GENÇ YETİŞKİNLERDE SPONTAN SERVİKAL KAROTİD VAZOSPAZMI BİR STROK NEDENİDİR: NON-İNVAZİV GÖRÜNTÜLEME**ÖZET**

Makalede, sağ hemiparezi ile gelen 21 yaşındaki hasta sunulmaktadır. Başvurunun ikinci gününde yapılan renkli Doppler ultrasonografi incelemesinde (RDU), sol internal karotis arterin (IKA) proksimal kesiminde preokluziv stenoz gözlemlendi. Aynı gün yapılan manyetik rezonans anjiyografide (MRA) sol IKA gözlenemedi. Üçüncü günde yapılan manyetik rezonans görüntüleme (MRG), sol hemisfer parenkiminde akut iskemik lezyon görüldü. Pulse metilprednisolon tedavisi başlandı. Tedavinin 3. gününde ikinci bir RDU ve MRA'de sol IKA'nın normal olduğu görüldü. Hasta aynı klinik ve radyolojik bulgularla toplam 3 kez daha kliniğimize başvurdu.

Sunulan hastanın klinik ve radyolojik bulguları genç erişkinlerde iskemik inme sebebi olabilecek ve görüntüleme yöntemleri hemen yapılmazsa fark edilmeyecek servikal karotis arterlerinin vazospazmını göstermektedir. MRA ve RDU bu tür olgularda acil uygulanabilen ve takipte kullanılabilen invaziv olmayan uygun bir görüntüleme tekniğidir.

Anahtar Sözcükler: Tekrarlayan karotis arter vazospazmı, inme, renkli Doppler ultrasonografi, manyetik rezonans anjiyografi.

INTRODUCTION

Vasospasm of the cervical arteries is one of the causes for ischemia in young stroke cases. It frequently occurs due to mechanical manipulations and to some drugs such as ergo compounds. Cervical carotid artery vasospasms may also occur and resolve spontaneously without any trigger (1). Immediate and accurate imaging of the cervical arteries is vital in such cases. Recent imaging techniques such as magnetic resonance angiography (MRA) and color Doppler ultrasonography (CDU), improved the detection of vasospasms in the cervical arteries.

In the present paper we report uncommon clinical and radiological findings of a young female, followed for recurrent cerebral ischemic episodes

due to attacks of spontaneous vasoconstriction of internal carotid arteries that had been revealed by color Doppler ultrasonography (CDU) and MR angiography (MRA).

CASE REPORT

A 21-year-old female admitted to the emergency room for progressive motor aphasia and right hemiparesis. Her complaints commenced 36 hours prior to the referral. Past medical history was unremarkable except four suspected transient ischemic attacks in the last 6 months. The transient ischemic attacks were apparent with dysphasia and right arm paralysis lasting for a few minutes, which were previously diagnosed as psychogenic.

There was no positive history for neck or head trauma, migraine, hypertension, cardiac or other systemic diseases, pregnancy, obesity, smoking, alcohol abuse or oral contraceptives. Family history was positive for ischemic vascular events with an ischemic stroke in her grandfather and a coronary artery occlusion in her 29-year-old sister who went under a coronary artery by-pass operation a few months ago. Her physical examination was normal; there was no hyper-hypotension, cardiac arrhythmia, nor vascular murmur in the neck. Neurological examination on admission revealed motor aphasia and central facial paralysis, severe hemiparesis, hemihypoesthesia and extensor plantar response on the right side. Low molecular weighted heparin and antithrombotic medication were started.

Laboratory findings

Results of the routine blood tests, electrocardiography and chest X-ray were normal. Complete blood cell count was normal except a slight hypochromic microcytic anemia. Erythrocyte sedimentation rate was 4 mm/hr. Echocardiography was reported to be normal. Thyroid function studies revealed mildly elevated TSH and decreased T3 without any clinical significance. Further investigations of thyroid USG and thyroid syntigraphy were normal. The tests of cryoglobulin, cryofibrinogen, rheumatoid factor, anti-dsDNA, protein S, protein C, anti-trombin III, anti-cardiolipin IgM and IgG were normal. Skin test (patch test) of Behçet's disease was negative. However, repeated tests for ANA, anti Tg and anti-cardiolipin antibody IgM in the following months found to be slightly positive in the third examination.

Radiological findings and progress

A cranial MRI that was previously performed in another hospital on the same day of admission was normal except a chronic parenchymal lacunar infarct in the neighborhood of frontal horn of the left lateral ventricle. The first CDU was performed on the second day of admission. It revealed preocclusive stenosis on the proximal part of the left internal carotid artery (ICA) as is also documented in the following attacks. The MRA that was carried out on the same day could not visualize the left ICA, this finding raised the suspicion of occlusion of the left internal carotid artery (Figure 1). There were not any positive

signs for arterial dissection neither in CDU nor in MRA. A control MRI revealed wide acute ischemic lesions in the left caudate nucleus and left frontal white matter (Figure 2). IV DSA was planned, but following the explanation of potential risks of the procedure she did not consent for it.

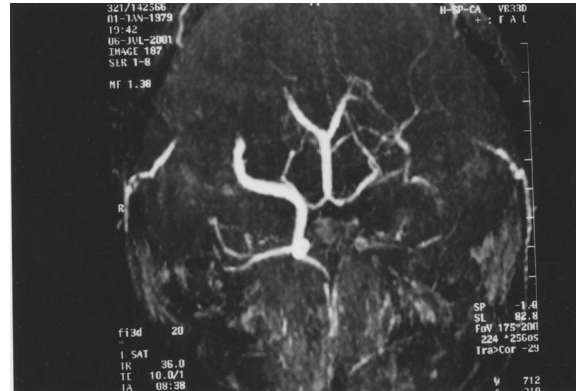

Figure 1: The occluded left ICA on MR angiography (2D TOF sequences) in the first admission.

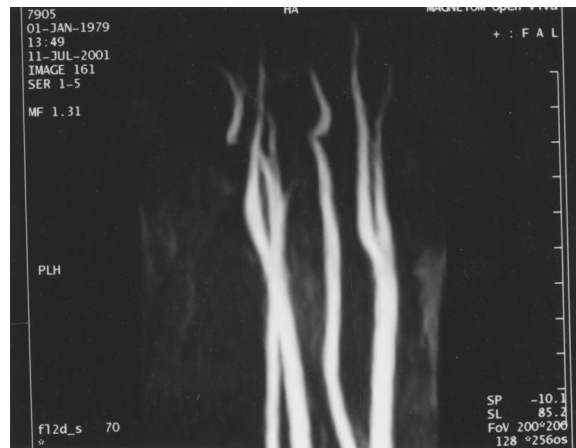


Figure 2: Normal flow in the left ICA on MR Angiography, six days later in the first admission.

Neither improvement nor deterioration was observed in her neurological examination for the first four days of admission. Despite of negative physical and laboratory findings, pulse methylprednisolone treatment was administered with a possible diagnosis of vasculitis on the basis of her age, gender, and radiological findings. Her neurological status improved rapidly following the initiation of steroid treatment. On the third day of the treatment we performed a second CDU. It showed normal waveform in the left ICA, as also documented in the following attacks and this finding was confirmed by MRA on the same day (Figure 3). In the following days her strength on her right arm and leg recovered totally. Two

weeks later she was discharged with a slight motor dysphasia and a slightly increased tonus and deep tendon reflexes in the right limbs. Rheumatology consultation was recommended but the patient did not consent to. She also did not consent for a lumbar puncture. She was discharged with antithrombotic medication.

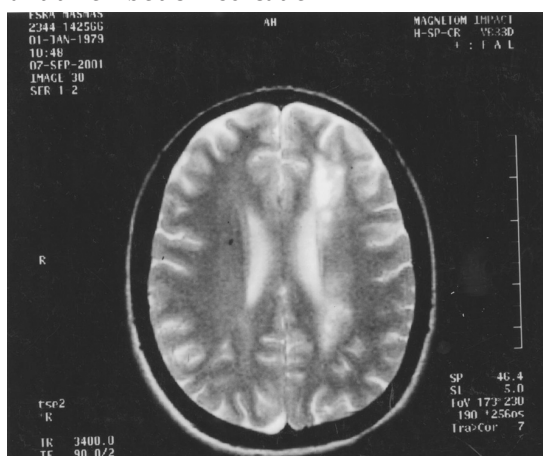


Figure 3: T2-weighted axial cranial MRI shows the acute infarct lesions in left corona radiata in the first admission.

In the later 5 months she was hospitalized two more times for new attacks with very similar clinical and radiological findings that responded very well to steroid treatment again. The patient consented to have a rheumatology consultation in another hospital following the third hospitalization and 150mg/day azathioprine was added to 300mg/day acetyl salicylic acid. A fourth attack have been documented by CDU after a 12 months of attack-free period (Figure 4 and 5). Follow-up examinations did not reveal any more attacks for the last 3 years.

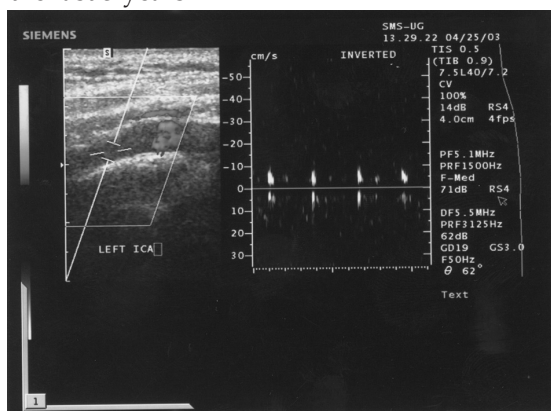


Figure 4: Color Doppler ultrasonography in the fourth attack show preocclusive stenosis of the left proximal internal carotid artery (system Siemens elegra advanced, linear 7.5 MHz transducer). Note the considerable reduction in flow rate in the proximal section.

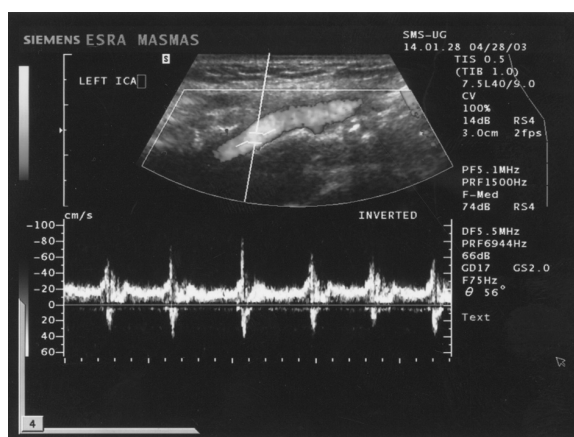


Figure 5: Color Doppler ultrasonography in the fourth attack showing normal findings, three days later. The pick systolic velocity of the left ICA is normal.

DISCUSSION

We documented four episodes of spontaneous occurrence of cervical carotid spasms in the present case. Dramatic changes of CDU and MRA findings were unusual and intriguing in this patient.

The rapid regression of the stenosis within less than 24 hours excluded the possibility of vascular stenosis due to arteriosclerosis. Clinical follow up and imaging studies excluded also the possibility of arterial dissection.

Non-atherosclerotic vasculopathy is one of the most frequent causes in young stroke cases, especially in women (2). Our patient had no migraine history. She had never used oral contraceptives or any other drugs that could cause vasospasm.

Due to her positive family history for ischemic events, in her sister and her grandfather, the possibility of having cerebral autosomal dominant arteriopathy with subcortical infarcts and leukoencephalopathy (CADASIL) or cerebral autosomal recessive arteriopathy with subcortical infarcts and leukoencephalopathy (CARASIL) was also considered. However the clinical and radiological findings were apart from this diagnosis and we didn't find an opportunity to clarify it genetically.

Initial clinical and laboratory findings were negative for vasculitis. The prompt and recurrent responses to steroid treatment in all three episodes with similar clinical and radiological findings gave the impression that the carotid vasoconstriction might be responsive to steroid treatment in this patient. However, it may also be improved

spontaneously. Similarly, we can not state clearly the explanation of symptom-free 12 months following azathioprine and acetyl salicylic acid. All these clinical observations in addition to slightly positive ANA, anti-Tg and anti-cardiolipin antibody Ig M in the third examination in the following months raised the suspicion of a vasculitic process, that we could not reveal.

Idiopathic reversible cerebral vasoconstriction was also strongly considered in differential diagnosis. It was identified as spontaneous vasoconstriction lasting about 7 days to 6 months without any risk factors for stroke (3,4). This syndrome is more common in white women and some patients may have a history of migraine.

More recently, Arning et al. reported that severe bilateral vascular stenosis of the ICAs could be detected by immediate sonography only during the ninth attack in a case with recurrent episodes of ischemia (1). They concluded that, cervical carotid artery vasospasms can occur spontaneously and may remain undetected, which we believe, would be the same in our patient if the CDU and MRA were not performed immediately.

In the present case, serious and relapsing vasospasms were the probable reason for the wide parenchymal infarcts. Angiography was not performed during the attacks in the present case. Although it is the "gold standard" to demonstrate intra and extracranial arteries, its availability is

limited in the vasospasmic patients (5). Although we could not perform IV DSA, we obtained sufficient data quickly by CDU and cranial MR angiography.

As conclusion, vasospasms of cervical carotid arteries may occur without any trigger and may cause ischemic stroke in young adults. They may be left unrecognized if the imaging studies are not performed promptly. MRA and CDU should be preferred for immediate and follow-up evaluations of cerebral arterial spasms, particularly in the patients with a potential risk for vasospasmic reaction.

REFERENCES:

- 1- Arning C, Schrattenholzer A, Lachenmayer L. Cervical carotid artery vasospasms causing cerebral ischemia. Detection by immediate vascular ultrasonographic investigation. *Stroke*.1998;29: 1063-1066.
- 2- Barinagarrementeria F, Gonzalez-Duarte A, Miranda L, et al. Cerebral infarction in young women: analysis of 130 cases. *Eur Neurol* 1998;40:228-33.
- 3- Bleic S, Bogousslavsky. Stroke in young adults. In: *Stroke Pathophysiology, diagnosis, and management*. Barnett HJM, Mohr JP, Stein BM, Yatsu FM. 3rd edition. Pennsylvania 1998. 1001-1003.
- 4- Mosso M, Jung HH, Baumgartner RW. Recurrent spontaneous vasospasm of cervical carotid, ophthalmic and retinal arteries causing repeated retinal infarcts: a case report. *Cerebrovasc Dis*. 2007;24:381-384.
- 5- Alhalabi M, Moore PM. Serial angiography in isolated angitis of the central nervous system. *Neurology*.1994;44:1221-1226