

Dumbbell-Shaped Neurofibroma of the Upper Cervical Spine: A Case Report

Feyzi Birol SARICA, Kadir TUFAN, Melih ÇEKİNMEZ, Bülent ERDOĞAN, Orhan ŞEN

Başkent University Medical Faculty, Department and Neurosurgery, Ankara

✓ Spinal neurofibromas are the most prevalent group of spinal tumors. They occur sporadically or in association with Neurofibromatosis type-1 (NF1, von Recklinghausen disease). A neurofibroma's developing a "dumbbell tumor" is a situation which is quite often seen. Surgical intervention is indicated when myelopathy and motor deficits develop in the case of paraspinal neurofibromas. The goal of surgery is total removal of the tumor. However, in selected cases partial removal of the tumor with adequate spinal cord decompression can be preferred to prevent severe complications such as vertebral artery injury. We present a case of neurofibroma with neck and shoulder pain and dumbbell tumor formation at the level of C1 that was in close relation with the vertebral artery. Possible surgical interventions are discussed.

Key words: Dumbbell formation, spinal neurofibroma, surgical treatment, upper servikal area

J Nervous Sys Surgery 2008; 1(3):190-194

Üst Servikal Omurilik Bölgesinde Gözlenen Kum Saati Şeklinde Nörofibroma: Olgu Sunumu

✓ Spinal nörofibromlar spinal tümörlerin önemli bir kısmını oluşturur. Sporadik yada Nörofibromatozis tip-1 (NF1, von Recklinghausen hastalığı) ile birlikte görülür. Nörofibroma'nın "Dumbbell tümör" şeklinde gelişim göstermesi oldukça sık görülen bir durumdur. Paraspinal nörofibroma olgularında myelopati veya motor defisit geliştiği durumlarda cerrahi endikasyon doğar. Cerrahide amaç tümörün total çıkarımıdır. Ancak seçilmiş vakalarda, vertabral arter yaralanması gibi ağır komplikasyonlardan kaçınmak amacıyla, yeterli spinal kord dekompresyonu sağlayacak şekilde parsiyel çıkarım seçilebilir. Bu makalede, C1 düzeyinde vertabral arter ile yakın ilişkide olan, boyun ve omuz ağrısı ile prezente olan dumbbell nörofibroma olgusu sunulmuştur. Secilebilecek cerrahi girişim şekilleri tartışılmıştır.

Anahtar kelimeler: Cerrahi tedavi, kum saati formasyonu, spinal nörofibroma, üst servikal bölge

J Nervous Sys Surgery 2008; 1(3):190-194

Nodular neurofibromas may occur anywhere on the peripheral nerves. They frequently originate from the dorsal roots and invade the sensorial branches. They are capsulated and have a round and flexible structure ^(3,5,7,8). No treatment is needed for asymptomatic neurofibroma cases. Symptomatic cases justify surgical treatment. Surgical treatment of neurofibromas is total removal. Posterior laminectomy with unilateral facetectomy allows

single-stage resection of dumbbell neurofibromas with significant intraspinal and paraspinal components. Best results are obtained from patients with minimal neurological deficits in the preoperative period ^(4,8,11,14).

CASE REPORT

A 61-year-female was admitted to the hospital with pain over the neck, left shoulder and arm.

Neurological examination revealed left-sided spastic hemiparesis, more pronounced distally hypoesthesia below C2 dermatome and hyperactive deep tendon reflexes. T₁-weighted magnetic resonance imaging (MRI) of the cervical spine showed a hypointense mass measuring 1.5x2x2.5 cm and occupying the left neural foramen and left half of the spinal canal. The lesion had a prominent hyperintense center with a hypointense periphery on T₂-weighted images. There was a marked contrast enhancement of the periphery of the lesion following gadolinium injection. Intradural component of the mass was found to compress the left side of the spinal cord while the extradural component was close to the vertebral artery (Figures 1A and 1B). Vertebral angiography was performed to determine the course of the vertebral artery (VA) and to plan the surgical procedure. Cranial diffusion-perfusion MRI performed to depict cerebral vascularization and collateral circulation was normal.

The patient was operated via a posterior exposure with posterior arc of C1 and C2 removed. During the partial resection, foraminal and extradural components were left in situ while the intradural component of the tumor which compressed the spinal cord at the levels of C1 and C2 and contained nerve rootlets was totally excised to achieve spinal cord decompression. Since the case was considered as a neurofibroma, there were possibilities of spinal cord compression by the intradural component and adhesions of the extradural component to the vertebral artery and venous structures around it. Therefore, care was taken not to cause traction during the dissection. Histopathological diagnosis of the resected specimen was neurofibroma.

Postoperative neurological examination revealed left hemiparesis (4/5 motor strength). Physical therapy and rehabilitation was given. At 4 months followed-up, neurological examination was normal and neck pain was comple-

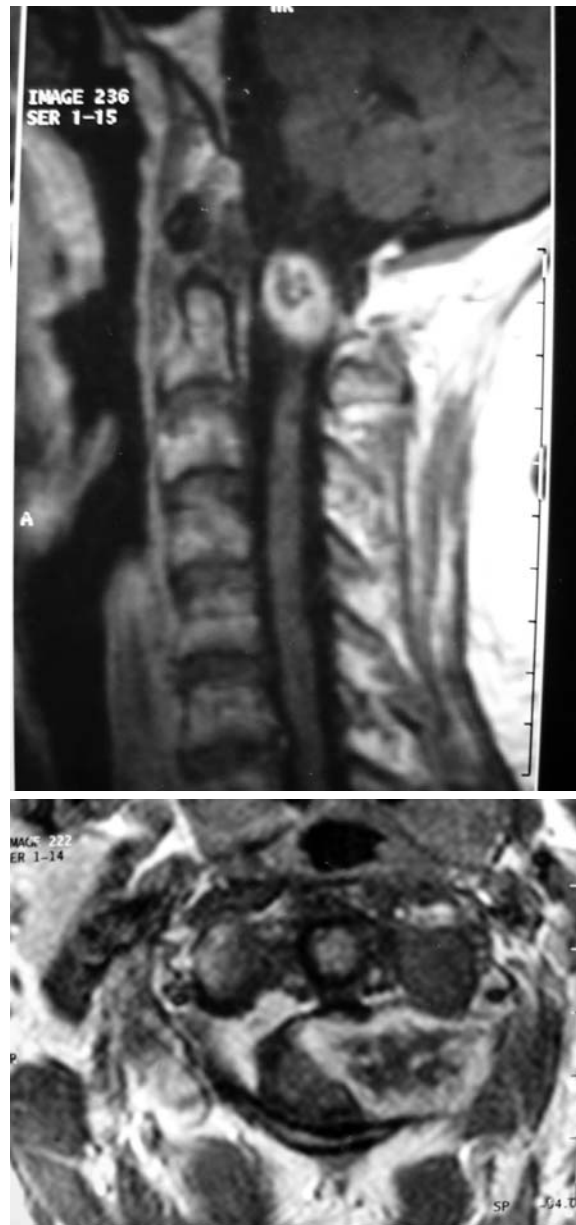


Figure 1. (A) A hyperintense mass overlying the left transverse process was observed on preoperative, sagittal, contrast-enhanced, T1-weighted magnetic resonance images of the spine. (B) On axial, contrast-enhanced T1-weighted magnetic resonance images of the patient performed preoperatively, a hyperintense mass, with intra and-extradural components, extending toward the left transverse process was observed.

tely resolved. Removal of intradural component of the neurofibroma and adequate decompression of the spinal cord was seen on postoperative cervical spine MRI (Figures 2A and 2B).

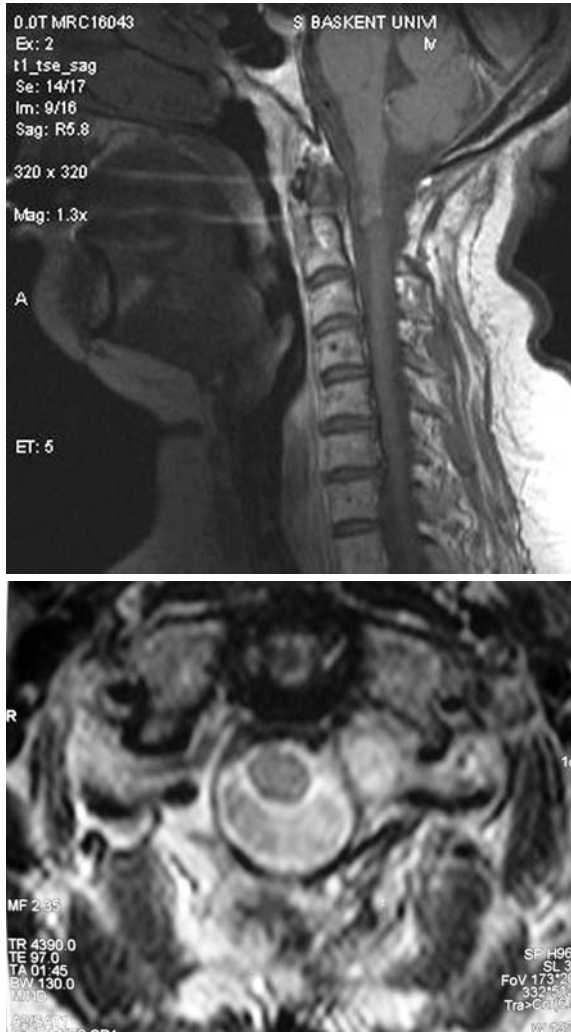

Figure 2. Sagittal (A) and axial (B) T2-weighted MR images of the cervical spine of the patient taken 2 months after the operation clearly show that the intradural component of the tumor at the level of C1-C2 was excised and there was no spinal cord compression.

DISCUSSION

Of the paraspinal neurofibromas; 72 % were with intradural extramedullary localization, where as 14 % were with extradural, 13 % were with dumbbell formation and 1 % was with intramedullary localizations^(5,7,16). A neurofibroma in the spinal canal, invading the peripheral segment of the nerve by extending out of the intervertebral foramen and presenting itself with a dumbbell tumor is quite common. In the series of cases presented by Seppala et al., 21 (66 %) of 32 neurofibromas demonstrated both intradural and extradural tumor components, and 17 tumors

extended laterally through the foramina. In these dumbbell neurofibromas, the extraspinal part is usually larger than the intraspinal part⁽¹⁴⁾. Tumor with may reach massive dimensions, be lobulated and exhibit cystic degeneration. Dumbbell formation is important due to the attachment of, especially, the extramedullary part to the surrounding tissues. Its vicinity to the VA is critical^(10,13,14).

Clinical findings develop as a result of local compression of the ventral or motor nerve roots. While root symptoms develop during the early period, long-tract findings develop later. Cervical and lumbar regions are more frequently invaded. Radicular pain and disesthesia were present in 80 % cases. Motor weakness that we detected in our case is seen in some 10 % of the cases^(5,8,11).

Direct radiographs are sufficient to establish diagnosis in 50 % of the cases. Pedicle erosion and vertebral body scalloping are the most frequent findings on direct radiograph. Regular expansion of the interpedicular distance and intervertebral foramen may directly indicate the presence of the dumbbell tumor. Thanks to its sensitivity and specificity, MRI is quite important in detecting the disease, determining the accompanying pathologies and following the development of the complications in NF1 cases. Neurofibromas appear as iso- or hyperintense to the spinal cord on T₁-weighted images while they give hyperintense signal on T₂-weighted images. Dumbbell neurofibromas enhance regularly upon gadolinium administration^(5,6,15).

No treatment is needed for asymptomatic neurofibroma cases. Symptomatic cases justify surgical treatment. Majority of the nerve fibers are entrapped within tumoral tissue in dumbbell neurofibroma cases, as in our case. It is impossible to remove the tumor without sacrificing the nerve root and aggressive surgery may result in severe neurological deficits^(8,10). Thus, partial

resection should be preferred in dumbbell neurofibroma cases that cause compression of the spinal cord. As the aim of partial resection is to resolve the symptoms, the extent of surgical treatment is shaped according to the clinical picture of the patient. Our patient presented with myelopathic findings and, therefore, decompressive excision of the tumor was planned. In decompression surgery, intradural component of the tumor that compressed the spinal cord was excised but foraminal and extradural components were left. Decompressive surgery is a partial resection that carries with itself the risk of recurrence and surgery may be needed (5,8,9,10,11).

Dumbbell tumors with significant dissemination into the paraspinal region may require complex spinal exposure. Although two-stage operations may be performed to manage the intraspinal and paraspinal components separately, a single-stage procedure is preferable. For cervical tumors, the VA is another issue to be considered. In most instances, meningiomas and nerve sheath tumors receive little blood from the spinal cord and are attached by few adhesions to the spinal cord. Most cervical dumbbell tumors can be adequately accessed through a standard laminectomy and complete unilateral facetectomy. As in our case, this allows paraspinal access up to 3 cm from the lateral dural margin. A second-stage anterior procedure may be required if further tumor extension is present (2,4,10,12).

The VA is consistently displaced anteromedially by dumbbell neurofibromas of the cervical spine. The artery is neither encased nor invaded by these tumors but is separated from the tumor capsule by a thin layer of periosteum and perivertebral veins. These tissues serve as an effective and easily developed plane of dissection that is rarely associated with VA injury. Thus, because of the low risk of either VA injury or its potential ischemic consequences, preoperative angiography and/or test occlusion or early intra-

operative control and mobilization do not seem warranted (4,10,13).

The incidence of cervical spine instability after unilateral facetectomy and varying degrees of laminectomy is unknown. In an experimental study by Cusick et al., isolated unilateral cervical facetectomy resulted in an average loss of strength of 31.6 % in response to a constant flexion/compression load, as compared with an intact motion segment (1). Although acute spinal instability did not occur in the clinical study by McCormick et al., the significant loss of mechanical integrity associated with unilateral facetectomy presented a continued risk of delayed instability from repetitive loading (11). This risk probably increases in proportion to the amount of concomitant laminar ant ligamentous disruption. Independent factors, such as patient age, spinal mobility, individualized loading patterns, and spinal level, might also be relevant. Contralateral facet fusion prevents delayed instability.

Prognosis is excellent after the surgical resection. While pain is diminished in 80 % of the cases, total remission occurs in 60 % of the cases. Recurrence is very rare subsequent to total excision. Recurrence after 3 years was noted in one of 66 paraspinal neurofibroma patients who were treated by Levy et al. (8). However, upper cervical neurofibroma cases characterized by dumbbell formation, as in our case, are treated by partial resection, thus they have the risk of recurrence. It is crucial to screen cervical spine in these patients by advanced imaging modalities such as MRI to detect recurrence (5,10,11,14).

CONCLUSION

The most significant feature of dumbbell neurofibromas is the adhesion of the tumor to the environment by enlarging the foramen and projecting outward from the spinal canal (8,10,11). The

goal of surgery is total removal of the tumor. Although a variety of surgical approaches for these lesions is available, most cervical spine dumbbell tumors can be effectively managed with a single-stage posterior exposure with partial laminectomy and unilateral facetectomy^(4,8,10,13,14). However, in selected cases partial removal of the tumor with adequate spinal cord decompression can be preferred to prevent vertebral artery injury.

REFERENCES

1. **Cusick JF, Yoganandan N, Pintar F, Myklebust J, Hussain H.** Biomechanics of cervical spine facetectomy and fixation techniques. *Spine* 1988; 13:808-12.
2. **Hakuba A, Komiyama M, Tsujimoto T, Ahn S, Nishimura S, Ohta T, Kitano H.** Transuncodiscal approach to dumbbell tumors of the cervical spinal canal. *J Neurosurg* 1984; 61:1100-6.
3. **Hirsch NP, Murphy A, Radcliffe JJ.** Neurofibromatosis: Clinical presentations and anaesthetic implications. *Br J Anaesth* 2001; 86:555-64.
4. **Jung MH, Lee SK, Song KY, Kang DS.** Staged Operation of a Dumbbell-Shaped Schwannoma in High Cervical Region. *JKNS* 2003; 33(2):204-47
5. **Keles E, Ozer AF.** Intrameduller ve ekstrameduller omurilik tumorleri. In: Zileli M, Ozer AF, eds. *Omurilik ve Omurga Cerrahisi*, 2nd. Izmir, 2002: 1113-9.
6. **Khong PL, Goh WH, Wong VC, Fung CW, Ooi GC.** MR imaging of spinal tumors in children with neurofibromatosis 1. *AJR Am J Roentgenol* 2003; 180:413-7.
7. **Lee M, Rezaei AR, Freed D, Epstein FJ.** Intramedullary spinal cord tumours in neurofibromatosis. *Neurosurgery* 1996; 38:32-7.
8. **Levy WJ Jr, Latchaw J, Hahn JF.** Spinal neurofibromas: a report of 66 cases and a comparison with meningiomas. *Neurosurgery* 1986; 18:331-4.
9. **McCormick PC.** Anatomic principles of intradural spinal surgery. *Clin Neurosurg* 1994; 41:204-23.
10. **McCormick PC.** Surgical management of dumbbell tumors of the cervical spine. *Neurosurgery* 1996; 38(2):294-300.
11. **McCormick PC, Post KD, Stein BM.** Intradural extramedullary tumors in adults. *Neurosurg Clin North Am* 1990; 1:591-608.
12. **Schultheiss R, Gulotta G.** Resection of relevant nerve roots in surgery of spinal neurinomas without persisting neurological deficit. *Acta Neurochir (Wien)* 1993; 122:91-6.
13. **Sen C, Eisenberg M, Casden AM, Sundaresan N, Catalano PJ.** Management of the vertebral artery in excision of extradural tumors of the cervical spine. *Neurosurgery* 1995; 36:106-16.
14. **Seppala MT, Laltia MJ, Sankila RJ, Jaaskelainen JE, Heiskanen O.** Long-term outcome after removal of spinal neurofibroma. *J Neurosurg* 1995; 82:572-7.
15. **Shu HH, Mirowitz SA, Wippold II FJ.** Neurofibromatosis: MR imaging findings involving the head and spine. *AJR Am J Roentgenol* 1993; 160:159-64.
16. **Yagi T, Ohata K, Haque M, Hakuba A.** Intramedullary spinal cord tumour associated with neurofibromatosis type 1. *Acta Neurochir (Wien)* 1997; 139:1055-60.