



## Original Research

# The Presence and Severity of Inferior Turbinate Hypertrophy in Patients with Hypertrophic Scars

Duygu Erdil,<sup>1</sup> Ozan Ozdemir,<sup>2</sup> Vildan Manav<sup>1</sup>

<sup>1</sup>Department of Dermatology, University of Health Sciences Türkiye, Istanbul Training and Research Hospital, Istanbul, Türkiye

<sup>2</sup>Department of Otorhinolaryngology/Head and Neck Surgery, University of Health Sciences Türkiye, Istanbul Training and Research Hospital, Istanbul, Türkiye

### Abstract

**Objectives:** This study aimed to investigate the presence and severity of inferior turbinate hypertrophy (ITH) in patients with hypertrophic scars (HTS).

**Methods:** This case-control study was conducted with patients diagnosed with HTS during dermatologic examination and a control group without HTS. An otolaryngologist evaluated the presence and severity of inferior turbinate hypertrophy by anterior rhinoscopy.

**Results:** ITH was more common in patients with HTS compared to the control group (64%, and 34%, respectively) ( $p=0.014$ ). In the HTS group, 48% of patients had grade 2, and 16% had grade 3 ITH; in the control group, 24% had grade 2, and 10% had grade 3 ITH ( $p=0.046$ ). Also, ITH was higher in patients who complained of pruritus or pain (83%, and 80%, respectively) in the HTS than in asymptomatic HTS patients ( $p=0.020$ ).

**Conclusion:** A higher number of patients with HTS had ITH compared to the control group, especially those who reported pruritus or pain associated with scar. Given the limited understanding of the full pathogenesis and treatment of HTS and ITH, their association potentially provides new insights into these related conditions.

**Keywords:** Cicatrix, hypertrophic, mast cells, rhinitis, turbinates, wound healing

Please cite this article as "Erdil D, Ozdemir O, Manav V. The Presence and Severity of Inferior Turbinate Hypertrophy in Patients with Hypertrophic Scars. Med Bull Sisli Etfal Hosp 2024;58(2):226–232".

Scar formation results from tissue injury that initiates the wound-healing process. Hypertrophic scars (HTS) result from abnormal responses to trauma and can cause pruritus, pain, and even severe functional and cosmetic disability. Inferior turbinate hypertrophy (ITH) is a common cause of chronic nasal obstruction. ITH develops due to inflammation caused by allergic or nonallergic rhinitis.<sup>[1]</sup>

Mast cells (MCs) in the skin and nasopharynx are alike and may act through similar mechanisms. MCs increase acute inflammation, stimulate reepithelialization and angiogen-

esis, and promote scar formation. The number of MCs increases in chronic wounds, HTSs, and keloids.<sup>[2]</sup> Besides, increased MCs in the lower turbinates have been detected in allergic and nonallergic rhinitis.<sup>[3]</sup> TGF- $\beta$ , SMAD pathways, periostin and thymic stromal lymphopoietin also play a common role in chronic rhinitis and HTS pathogenesis.<sup>[4-11]</sup>

Recently studies suggest that mast cell stabilizers could reduce excessive wound construction and fibrosis. Several studies have indicated that a mast cell stabilizer, montelukast may inhibit the healing contraction process in cutane-

**Address for correspondence:** Ozan Ozdemir, MD. Department of Otorhinolaryngology/Head and Neck Surgery, University of Health Sciences Türkiye, Istanbul Training and Research Hospital, Istanbul, Türkiye

**Phone:** +90 530 569 43 97 **E-mail:** opdrozanzozdemir@gmail.com

**Submitted Date:** December 11, 2023 **Revised Date:** February 26, 2024 **Accepted Date:** March 10, 2024 **Available Online Date:** June 28, 2024

©Copyright 2024 by The Medical Bulletin of Sisli Etfal Hospital - Available online at [www.sislietfaltip.org](http://www.sislietfaltip.org)

**OPEN ACCESS** This is an open access article under the CC BY-NC license (<http://creativecommons.org/licenses/by-nc/4.0/>).



ous wounds.<sup>[12,13]</sup> Montelukast is already an effective treatment for allergic rhinitis.<sup>[14]</sup> Another anti-allergic agent and mast cell stabilizer, tranilast inhibits the formation of keloid scarring.<sup>[15-16]</sup> Also, studies revealed that tranilast could have therapeutic effects on allergic rhinitis.<sup>[17]</sup>

HTS and ITH share common mechanisms in their pathogenesis and treatments, particularly through MCs. However, there has been no previous research into the link between these two diseases. This study aimed to investigate the presence and severity of ITH in patients with HTS.

## Methods

### Ethical Approval

The Institutional Ethics Committee approved the study (No: 2543-02.10.2020). All procedures were performed in accordance with the ethical standards set forth by the World Medical Association Declaration of Helsinki (Brazil 2013). In addition, written informed consent was obtained from the patients.

### Patients and Study Design

This prospective case-control study was conducted with patients who applied to the dermatology clinic in a tertiary hospital between September 2020 and March 2021. Patients admitted to the dermatology outpatient clinic diagnosed with HTS were included in the HTS group, and 50 patients without HTS were included in the control group. All patients were referred to the otolaryngology outpatient clinic and evaluated for the presence and severity of ITH by a single experienced otolaryngologist. Clinical data including allergic rhinitis symptoms such as nasal congestion, itching, runny nose and sneezing were also recorded.

Patients using antihistamines or intranasal corticosteroids in the last 14 days, with an inferior turbinate radiofrequency operation in the last six months, and significant septum deviation on contralateral compensatory ITH were excluded from the study.

Sociodemographic information, including the age, gender, and occupation of the patients, was recorded. In patients with HTS, the location, and duration of the scar, the number of the lesion (single or multiple), accompanying symptoms (pruritus or pain), and Vancouver Scar Scores were calculated and recorded.<sup>[18]</sup> Vancouver Scar Scale is calculated by the sum of the scores obtained according to the vascularity (normal: 0, pink: 1, red: 2, purple: 3), pigmentation (normal: 0, hypopigmentation: 1, hyperpigmentation: 2), pliability (normal: 0, supple: 1, yielding: 2, firm 3, ropes: 4, contracture: 5) and height of the scar (mm) (flat: 0, <2 mm: 1, 2-5 mm: 2, >5 mm: 3).

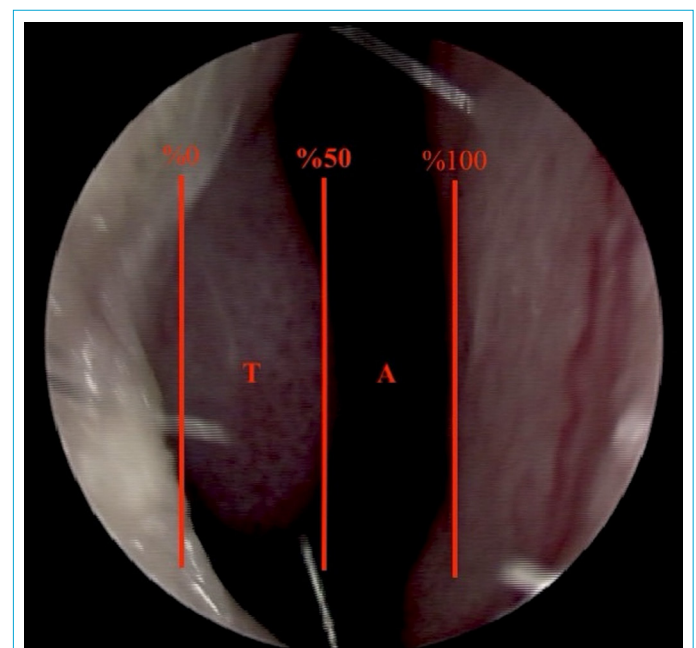
### Rhinoscopic Evaluation

All participants were evaluated for inferior turbinate hypertrophy through anterior rhinoscopy. Additionally, to enhance the objectivity of measurements, photographic images were obtained using an endoscope. ITH can be categorized as grade 1 to 3 on anterior rhinoscopic examination as defined by Deenadayal et al.<sup>[19]</sup> Grade 1 is a 25% enlargement without obvious obstruction; grade 2 is between 25-50% occlusion, and grade 3 is over 50% occlusion of the nasal cavity. The horizontal percentage of airway space can be determined by estimating the percentage of distance the anterior aspect of the inferior turbinate occupied in the lateral to medial dimension (Fig. 1).

This study evaluated all patients anterior rhinoscopically by a single senior surgeon at the otolaryngology outpatient clinic, without knowing whether they had been diagnosed with HTS. A 4 mm diameter, 0-degree rigid endoscope (Karl Storz, Germany) was used for photographic recording. The presence and degree of ITH were evaluated according to the method determined by Deenadayal et al.<sup>[19]</sup>

### Statistical Analysis

The SPSS Statistics 25.0 package program (Armonk, New York: IBM Corp.) for Windows was used for statistical analysis. The suitability of variables with normal distribution was examined using histogram graphics and the Kolmogorov-Smirnov test. Mean, standard deviation and median values were used while presenting descriptive analysis. Categorical variables were compared using the Pearson Chi-Square



**Figure 1.** Endoscopic view of the horizontal percentage of the airway space. A: airway, T: turbinate.

Test. The Mann-Whitney U test was used when evaluating non-parametric variables between two groups. The Kruskal-Wallis Test was used when evaluating non-parametric variables between more than two groups. Statistical significance was defined as a p-value of less than 0.05.

## Results

Twenty-five patients with HTS and 50 control patients at the dermatology outpatient clinic were included in the study. All patients included in this study were Caucasian. There was no significant difference in descriptive variables such as age, gender, and occupation between the HTS and the control group (Table 1).

HTSs were located on the chest in 11 patients, on the shoulder in nine patients, retro-auricular in four patients, on the back in three patients, on the hips in two patients, on the ab-

domen in two patients and on legs in one patient. HTS was detected in one region in 11 patients and more than one region in 14 patients. The duration of HTS was 0-6 months in three patients, 6-12 months in three patients, 1-5 years in 12 patients, and longer than five years in seven patients. The mean Vancouver scar score for HTS patients was  $6.68 \pm 1.84$ .

When the symptoms of allergic rhinitis were compared between the groups, there was no significant difference ( $p=0.285$ ). 36% ( $n=9/25$ ) of the patients in the HTS group described one or more symptoms and 38% ( $n=19/50$ ) in the control group.

ITH was more common in patients with HTS than in the control group (64% and 34%, respectively) ( $p=0.014$ ). Furthermore, in the HTS group, 48% of patients were grade 2, and 16% of patients had grade 3 ITH, and in the control group, 24% of patients were grade 2, and 10% of patients had grade 3 ITH ( $p=0.046$ ) (Table 2). There was no statisti-

**Table 1.** Demographic characteristics of HTS and control group

	HTS group		Control group		p <sup>1</sup>
	n	%	n	%	
Age	32.24±12.43	29.00	34.52±10.88	34.50	0.306 <sup>2</sup>
Sex					
Male	12	(48.00)	19	(38.00)	0.407
Female	13	(52.00)	31	(62.00)	
Education					
Primary school	11	(44.00)	23	(46.00)	0.005
Highschool	3	(12.00)	20	(40.00)	
University	11	(44.00)	7	(14.00)	
Occupation					
Not working/ retired	4	(16.00)	20	(40.00)	0.092
Student	6	(24.00)	9	(18.00)	
White collar	4	(16.00)	2	(4.00)	
Blue collar	11	(44.00)	19	(38.00)	

<sup>1</sup>Chi-Square Test <sup>2</sup>Mann Whitney U Test; HTS, hypertrophic scar.

**Table 2.** Evaluation of the relationship between the presence and severity of ITH and HTS

	Hypertrophic scar (HTS) group		Control group		p
	n	%	n	%	
Inferior Turbinate Hypertrophy (ITH)					
No	9	(36.00)	33	(66.00)	0.014
Yes	16	(64.00)	17	(34.00)	
ITH grade					
Grade 1	9	(36.00)	33	(66.00)	0.046
Grade 2	12	(48.00)	12	(24.00)	
Grade 3	4	(16.00)	5	(10.00)	

Chi-Square Test.

cally significant difference between the presence or severity of ITH and the Vancouver Scar Scale scores (Table 3).

In the HTS group, eight patients were asymptomatic, 12 patients had pruritus, and five had pain in their scars. ITH was higher in patients who complained of pruritus or pain in the HTS than in asymptomatic patients. In the HTS group, 83% of the patients complained of itching (n=10), and 80% of pain (n=4) was assessed as ITH (p=0.020). (Fig. 2). In the presence of HTS-related symptoms, the sensitivity was 87.50, and the specificity was 66.67 for ITH (Fig. 2).

In the HTS group, the mean age of the patients with ITH was 30.6 (SD±10.21, Median:28.50), while the mean age of the patients who did not have ITH was 36.11 (SD±15.54, Median: 30.00) years, and there was no statistically significant difference (p=0.357).

The relationship between ITH and the number and the location of the lesions in HTS patients were also assessed. ITH was detected in nine patients (81.82%) with a single HTS and in seven patients (50%) with multiple HTSs. There is no significant relationship between single or multiple HTSs and ITH (p=0.100). The rate of ITH is lower in patients with

HTS localized in the abdomen compared to those without localized in the abdomen (p=0.049) (Table 4).

The relationship between the duration of HTS and ITH was evaluated. In the HTS group, ITH was detected in two (66.67%) of the patients with scar duration of 0-6 months, in two (66.67%) of the patients with scar duration of 7-12 months, eight (66.67%) patients with scar duration of 1-5 years and four (57.14%) patients with scar duration of more than five years. There was no significant relationship between the duration of HTS and ITH (p=0.978) (Table 5).

## Discussion

Mast cells (MCs) play an essential role in wound healing.[20] They activate fibroblasts, which are responsible for collagen accumulation and remodeling. Cutaneous wounds heal without leaving scars in the early stages of fetal development. This is because fetal tissues have a low number of MCs, which indicates the importance of MCs in excessive wound healing.[7] Studies have shown that mast cell stabilizers can help reduce excessive wound construction and fibrosis without affecting the normal healing process.[21, 22] MCs increase in systemic fibrotic conditions such as rheumatoid arthritis, pulmonary fibrosis, liver fibrosis, and HTS.[6, 23]

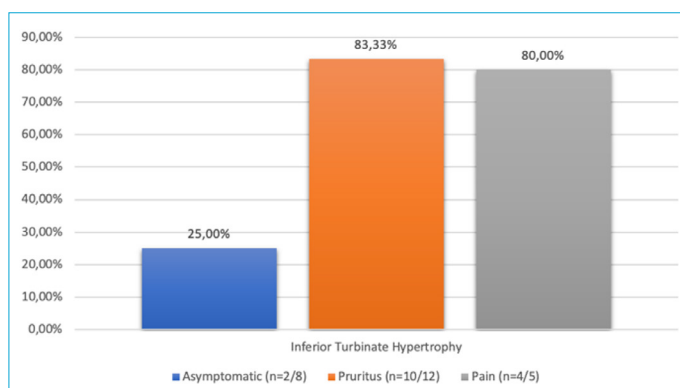
Rhinitis can lead to structural changes in the nasal mucosa. Chemical or physical stimuli to the nasal epithelium initiate the stimulation of the trigeminal nerves, which further leads to neurogenic inflammation via inflammatory mediators. MCs are sensitive to mechanical stimulation, and mechanical changes can cause increased degranulation in MCs. A response to repeated inflammation leads to a reconstruction of the damaged tissue.[21] Increased mucosal collagen deposition, mucosal myofibroblast transformation, and increased matrix protein deposition have been reported in rhinitis.[19] These structural changes in tissue remodeling lead to ITH. Both chronic rhinitis and HTS share similarities in pathogenesis, with MCs, TGF-B, SMAD pathways, and periostin and thymic stromal lymphopoietin being involved.[4, 5, 9] Mast cell stabilizers are already an effective treatment for allergic rhinitis.[14]

In addition to studies on mast cell stabilizers, recent studies have reported that botulinum toxin injections could treat both HTS and rhinitis. A systematic review and meta-analysis showed that injection of intralesional botulinum toxin type A was an effective treatment option for HTS.[24] On the other hand, it has been reported that botulinum toxin injection into the inferior turbinates of patients with allergic and idiopathic rhinitis may be a treatment option by reducing the symptoms of sneezing, itching, nasal congestion, and runny nose.[25] Recent studies also revealed that botulinum toxin reduced MC activity.[26] Notably, rhinitis and HTS

**Table 3.** Evaluation of the relationship between the Vancouver scar scale scores and ITH

	Vancouver scar scale score Mean (±SD), Median	p
ITH		
None	6.89±1.76, 7.00	0.760 <sup>1</sup>
Present	6.56±1.93, 6.50	
ITH grade		
Grade 1	6.89±1.76, 7.00	0.282 <sup>2</sup>
Grade 2	6.17±1.95, 6.00	
Grade 3	7.75±1.50, 8.00	

<sup>1</sup>Mann Whitney U Test <sup>2</sup>Kruskal Wallis Test; ITH, inferior turbinate hypertrophy.



**Figure 2.** The relationship between HTS-associated symptoms and ITH (p=0.020).

**Table 4.** Evaluation of the relationship between scar localisations and ITH

	ITH				p
	Present		None		
	n	%	n	%	
Retro-auricular					
Present	4	(100.00)	0	(.00)	0.102
None	12	(57.14)	9	(42.86)	
Shoulder					
Present	4	(44.44)	5	(55.56)	0.127
None	12	(75.00)	4	(25.00)	
Chest					
Present	8	(72.73)	3	(27.27)	0.420
None	8	(57.14)	6	(42.86)	
Back					
Present	2	(66.67)	1	(33.33)	0.918
None	14	(63.64)	8	(36.36)	
Hips					
Present	1	(50.00)	1	(50.00)	0.667
None	15	(65.22)	8	(34.78)	
Legs					
Present	0	(.00)	1	(100.00)	0.174
None	16	(66.67)	8	(33.33)	
Abdomen					
Present	0	(.00)	2	(100.00)	0.049
None	16	(69.57)	7	(30.43)	

Chi-Square Test.

**Table 5.** Evaluation of the relationship between the duration of HTS and ITH

	ITH				p
	Present		None		
	n	%	n	%	
Duration of HTS					
0-6 months	2	(66.67)	1	(33.33)	0.978
7-12 months	2	(66.67)	1	(33.33)	
1-5 years	8	(66.67)	4	(33.33)	
More than five years	4	(57.14)	3	(42.86)	

Chi-Square Test; HTS: hypertrophic scar; ITS: inferior turbinate hypertrophy.

could be treated by the same treatment modality, and this effect may be MC-related. Since ITH is considered a result of remodeling in chronic rhinitis and because of the common features in their pathogenesis and treatment modalities, we investigated the association of ITH and HTS in patients. Interestingly and as we expected, the HTS group presented more with grade 2 and 3 ITH than the control group.

In 1987, Smith et al.<sup>[27]</sup> investigated the coexistence of ke-

loids or HTSs with allergic symptoms by surveying 1206 adolescents. A statistically significant increase in allergic symptoms was found in patients with keloid and HTS compared to control patients. Patients with HTS were 12% more likely to possess allergic reactions. They also stated that MCs' products might play a role in HTS and keloid development. After this publication, we found no other publication investigating the relationship between allergy and

HTS. Our study found no significant difference in allergic rhinitis symptoms (nasal congestion, runny nose, nasal itching, and sneezing) between HTS and controls. Still, ITH was statistically more common in patients with HTS than in the control group.

In a review of studies on symptoms within scar tissue, Kwak et al.<sup>[28]</sup> investigated the clinical and histopathological features of burn wounds. The patients were divided on whether they had a sensation of pruritus or not. In the pruritus group, they observed more prominent MC deposition than in the control group. Our study revealed that ITH is statistically more common if there is a complaint of pruritus or pain in HTS. According to these findings, if pruritus or pain accompanies HTS, evaluating the patient in terms of ITH and chronic rhinitis may be recommended.

In the literature, the presence of MCs demonstrated a significant association with the duration of scars, with a notable increase in MCs in scars of longer duration.<sup>[29]</sup> Our study examined the relationship between the duration of the HTS and ITH; however, there was no correlation. Therefore, our study suggests that symptoms such as pruritus and pain could be more related to ITH than the duration of the HTS.

The main limitation of this study was that more accurate results could be obtained with rhinomanometry measurements while evaluating ITH. Based on their common pathogenesis, this study investigated the relationship between HTS and ITH, two conditions that result in remodeling and exaggerated healing in response to trauma. The coexistence of HTS and ITH is remarkable. As we expected, the number of patients with ITH and the severity of ITH were higher in patients with HTS. The presence of concomitant ITH is more likely, especially with symptoms such as pruritus or pain in HTS.

## Conclusion

HTS can cause significant cosmetic problems, while inferior ITH may result in notable nasal obstruction. Both conditions involve tissue remodeling, sharing common pathogenic factors and treatment approaches. A higher number of patients with HTS had ITH compared to the control group, especially those who reported pruritus or pain associated with scar. Given the limited understanding of the full pathogenesis and treatment of HTS and ITH, their coexistence represents an exciting area for further investigation, potentially providing new insights into these related conditions.

## Disclosures

**Ethics Committee Approval:** The study was approved by the Istanbul Training and Research Hospital Clinical Research Ethics Committee (Date of approval: 02/10/2020, Protocol No: 2543).

**Peer-review:** Externally peer-reviewed.

**Conflict of Interest:** The authors declare no conflicts of interest.

**Funding:** There was no funding from public, private, or third sector sources.

**Acknowledgment:** We sincerely thank İsmail Kaygısız, MD for contributing to the study by taking the endoscopic records of the participants.

**Authorship Contributions:** Concept – D.E., O.O.; Design – D.E., O.O., V.M.; Supervision - V.M.; Fundings - D.E.; Materials - D.E., V.M.; Data Collection and/or Processing – D.E., O.O.; Analysis and/or Interpretation - D.E., V.M.; Literature Search - O.O., V.M.; Writing – D.E., O.O.; Critical Reviews - O.O., V.M.

**Use of AI for Writing Assistance:** None declared.

## References

- Rifki D, Cebeci D, Karasel S, Akcay NI. Efficacy of erb-laser on inferior turbinate hypertrophy: a retrospective and cohort study. *Sisli Etfal Hastan Tip Bul* 2022;56:381–5. [\[CrossRef\]](#)
- Scott JR, Muangman PR, Tamura RN, Zhu KQ, Liang Z, Anthony J, et al. Substance P levels and neutral endopeptidase activity in acute burn wounds and hypertrophic scar. *Plast Reconstr Surg* 2005;115:1095–102. [\[CrossRef\]](#)
- Wulff BC, Wilgus TA. Mast cell activity in the healing wound: more than meets the eye? *Exp Dermatol* 2013;22:507–10. [\[CrossRef\]](#)
- Aksoy B, Aksoy HM, Tatlıparmak A, Koç E. Cutaneous Scars: Biology, Clinics and Management. New York: Nova Science Publishers; 2019. p. 39–48.
- Bunyavanich S, Melen E, Wilk JB, Granada M, Soto-Quiros ME, Avila L, et al. Thymic stromal lymphopoietin (TSLP) is associated with allergic rhinitis in children with asthma. *Clin Mol Allergy* 2011;9:1.
- Chen H, Xu Y, Yang G, Zhang Q, Huang X, Yu L, et al. Mast cell chymase promotes hypertrophic scar fibroblast proliferation and collagen synthesis by activating TGF- $\beta$ 1/Smads signaling pathway. *Exp Ther Med* 2017;14:4438–42. [\[CrossRef\]](#)
- Cowin AJ, Holmes TM, Brosnan P, Ferguson MW. Expression of TGF- $\beta$  and its receptors in murine fetal and adult dermal wounds. *Eur J Dermatol* 2001;11:424–31.
- Adkinson NF, Bochner BS, Burks AW, Busse WW, Holgate ST, Lemanske RF, et al. *Middleton's Allergy: Principles and Practice*: 8th ed. Amsterdam: Elsevier Inc.; 2013. p. 1764.
- Lehmann AE, Scangas GA, Bergmark RW, El Rassi E, Stankovic KM, Metson R. Periostin and inflammatory disease: implications for chronic rhinosinusitis. *Otolaryngol Head Neck Surg* 2019;160:965–73. [\[CrossRef\]](#)
- Ouyang Y, Nakao A, Han D, Zhang L. Transforming growth factor- $\beta$ 1 promotes nasal mucosal mast cell chemotaxis in murine experimental allergic rhinitis. *ORL J Otorhinolaryngol Relat Spec* 2012;74:117–23. [\[CrossRef\]](#)
- Roy S, Chompunud Na Ayudhya C, Thapaliya M, Deepak V, Ali H. Multifaceted MRGPRX2: new insight into the role of mast cells in health and disease. *J Allergy Clin Immunol* 2021;148:293–308.

12. Tolazzi AR, Tolazzi KD, Garcia M, Graf RM, Freitas RS, Baretta GA, et al. Influence of leukotriene inhibitor montelukast on wound contraction and cutaneous healing process in rats. *Aesthetic Plast Surg* 2009;33:84–9. [\[CrossRef\]](#)
13. Turtay MG, Firat C, Samdanci E, Oguzturk H, Erbatur S, Colak C. Effects of montelukast on burn wound healing in a rat model. *Clin Invest Med* 2010;33:E413–21. [\[CrossRef\]](#)
14. Platt M. Pharmacotherapy for allergic rhinitis. *Int Forum Allergy Rhinol* 2014;4 Suppl 2:S35–40. [\[CrossRef\]](#)
15. Shimizu T, Kanai K, Kyo Y, Asano K, Hisamitsu T, Suzaki H. Effect of tranilast on matrix metalloproteinase production from neutrophils in-vitro. *J Pharm Pharmacol* 2006;58:91–9. [\[CrossRef\]](#)
16. Suzawa H, Kikuchi S, Arai N, Koda A. The mechanism involved in the inhibitory action of tranilast on collagen biosynthesis of keloid fibroblasts. *Jpn J Pharmacol* 1992;60:91–6. [\[CrossRef\]](#)
17. Shimizu T, Kanai K, Asano K, Hisamitsu T, Suzaki H. Suppression of matrix metalloproteinase production in nasal fibroblasts by tranilast, an antiallergic agent, in vitro. *Mediators Inflamm* 2005;3:150–9. [\[CrossRef\]](#)
18. Baryza MJ, Baryza GA. The Vancouver Scar Scale: an administration tool and its interrater reliability. *J Burn Care Rehabil* 1995;16:535–8. [\[CrossRef\]](#)
19. Deenadayal DS, Kumar MN, Sudhakshin P, Hameed S. Radiofrequency reduction of inferior turbinates in allergic and non allergic rhinitis. *Indian J Otolaryngol Head Neck Surg* 2014;66 Suppl 1:231–6. [\[CrossRef\]](#)
20. Ud-Din S, Wilgus TA, Bayat A. Mast cells in skin scarring: a review of animal and human research. *Front Immunol* 2020;11:552205.
21. Gallant-Behm CL, Hildebrand KA, Hart DA. The mast cell stabilizer ketotifen prevents development of excessive skin wound contraction and fibrosis in red Duroc pigs. *Wound Repair Regen* 2008;16:226–33. [\[CrossRef\]](#)
22. Chen L, Schrementi ME, Ranzer MJ, Wilgus TA, DiPietro LA. Blockade of mast cell activation reduces cutaneous scar formation. *PLoS One* 2014;9:e85226. [\[CrossRef\]](#)
23. Hiromatsu Y, Toda S. Mast cells and angiogenesis. *Microsc Res Tech* 2003;60:64–9. [\[CrossRef\]](#)
24. Bi M, Sun P, Li D, Dong Z, Chen Z. Intralesional injection of botulinum toxin type a compared with intralesional injection of corticosteroid for the treatment of hypertrophic scar and keloid: a systematic review and meta-analysis. *Med Sci Monit* 2019;25:2950–8.
25. Carvalho T, Salgado DC, Mion OG, de Mello JF, Voegels RL. The effect of turbinate injection of botulinum toxin a on the symptoms of idiopathic rhinitis. *Int Arch Otorhinolaryngol* 2021;26:e191–8.
26. Piroonchai P, Pornumnouy W, Saeseow P, Chainansamit S. The minimum effective dose of abobotulinum toxin A injection for allergic rhinitis: a dose-escalation randomized controlled trial. *Laryngoscope Investig Otolaryngol* 2020;6:6–12. [\[CrossRef\]](#)
27. Smith CJ, Smith JC, Finn MC. The possible role of mast cells (allergy) in the production of keloid and hypertrophic scarring. *J Burn Care Rehabil* 1987;8:126–31. [\[CrossRef\]](#)
28. Kwak IS, Park SY, Choi YH, Cho SI, Yang YS, Cho YS, et al. Clinical and histopathological features of post burn pruritus. *J Burn Care Res* 2016;37:343–9. [\[CrossRef\]](#)
29. Wilgus TA, Ud-Din S, Bayat A. A review of the evidence for and against a role for mast cells in cutaneous scarring and fibrosis. *Int J Mol Sci* 2020;21:9673. [\[CrossRef\]](#)