



DOI: 10.14744/SEMB.2020.25986

Med Bull Sisli Etfal Hosp 2021;55(1):81–85

## Original Research

# Effective of Pre-operative 2-Deoxy-2-[fluorine-18] fluoro-d-glucose/Positron Emission Tomography/Computed Tomography in the Determination of Boost Volume in Adjuvant Radiotherapy after Breast-conserving Surgery

Berrin Inanc,<sup>1</sup> Kubilay Inanc,<sup>2</sup> Begum Okten,<sup>1</sup> Ozlem Mermut<sup>1</sup>

<sup>1</sup>Department of Radiation Oncology, University of Health Sciences, Istanbul Training and Research Hospital, Istanbul, Turkey

<sup>2</sup>Department of Radiation Oncology, University of Health Sciences Turkey, Sisli Hamidiye Etfal Teaching and Research Hospital, Istanbul, Turkey

### Abstract

**Objectives:** Determining boost volume (BV) during breast radiotherapy can be challenging at times. Therefore, surgical clips are now being widely used. At times, when surgical clips are inadequate in determining the BV, other additional imaging methods are required. In the present study, we aimed to demonstrate that pre-operative positron emission tomography/computed tomography (PET-CT) can be used to determine the BV after a breast-conserving surgery.

**Methods:** We selected thirty patients who underwent breast-conserving surgery with surgical clips and had preoperative Fluorine-18-Fluorodeoxyglucose PET (18 FDG PET/CT). The BV in planning tomography (CT) and primary tumor volume (TV) in pre-operative F-18 FDG PET/CT was contoured by a radiation oncologist. These two volumes were superposed using rigid image fusion. In every patient, two BVs were measured. The mean shift between the two volumes by the calculation of the center of mass and percentage of the PET-CT TV (PET-CT TV) in planning the BV (planning target volume [PTV]-BV) was calculated.

**Results:** The median age was 52 years (range 25–72 years). The pre-operative PET-CT TV median was 8.89 cm<sup>3</sup> (range 1.00–64.30 cm<sup>3</sup>). The median PTV-BV was 62.92 cm<sup>3</sup> (12.57–123.07 cm<sup>3</sup>). The median shifts between the center of volumes were 1.76 cm (range 0.90–3.50) in X(coronal), 1.73 cm (range 0.60–3.60) in the Y(axial), and 1.20 cm (0.40–2.80) in the Z(sagittal) directions, respectively. The shifts in these three planes were determined to be statistically significant ( $p < 0.001$ ). The percent volume of PET-CT TV included PTV TV, ranging from 35% to 100% (mean 54%, standard deviation 29.53) and 100% in two out of 31 patients.

**Conclusion:** Our study has shown that pre-operative PET-CT cannot be used to determine the BV in patients who replaced surgical clips and had undergone breast-conserving surgery. To define a more accurate BV, surgical clips should be placed in four planes, and more PTV margins should be given in treatment planning.

**Keywords:** Boost volume; breast cancer; positron emission tomography/computed tomography; radiotherapy; surgical clips.

Please cite this article as "Inanc B, Inanc K, Okten B, Mermut O. Effective of Pre-operative 2-Deoxy-2-[fluorine-18] fluoro-d-glucose/Positron Emission Tomography/Computed Tomography in the Determination of Boost Volume in Adjuvant Radiotherapy after Breast-conserving Surgery. Med Bull Sisli Etfal Hosp 2021;55(1):81–85".

**Address for correspondence:** Berrin Inanc, MD. Saglik Bilimleri Universitesi, Istanbul Egitim ve Arastirma Hastanesi, Radyasyon Onkolojisi Klinigi, Istanbul, Turkey

**Phone:** +90 532 704 79 50 **E-mail:** byalcin77@hotmail.com

**Submitted Date:** December 30, 2019 **Accepted Date:** April 02, 2020 **Available Online Date:** March 17, 2021

©Copyright 2021 by The Medical Bulletin of Sisli Etfal Hospital - Available online at [www.sislietfaltip.org](http://www.sislietfaltip.org)

**OPEN ACCESS** This is an open access article under the CC BY-NC license (<http://creativecommons.org/licenses/by-nc/4.0/>).



Accurate localization of the boost volume (BV) in breast cancer patients is crucial. Because of the success of breast radiation therapy and improvement, local control rates depend on proper target localization.<sup>[1]</sup> Radiation oncologists delineate the BV referenced by the scar on the breast, localization of surgical clips, and imaging by breast ultrasound (USG) and magnetic resonance imaging (MRI).<sup>[2,3]</sup> Clips provide more precise information on BV. Some clinics place surgical clips in the prepectoral region, while some clinics place them in the 4 cardinal areas of the lumpectomy cavity. When surgical clips implanted only prepectoral region, there may be a geographic miss in defining BV. Therefore, pre-operative imaging studies are critical.

The most centers where BV can be most accurately detected include 3D-breast USG (3D-USG) and breast MRI. Another imaging modality for identifying the BV is F-18 FDG positron emission tomography/computed tomography (PET/CT). The primary tumor is well visualized with PET-CT. This imaging modality, the use of which has been increasing, may provide more accurate information in terms of tumor placement. There are limited data with the use of this imaging technique to detect BV.

Rigid fusion image was obtained by superposing pre-operative PET-CT and planning tomography images based on manual matching different types of anatomical structures. Then, we evaluated that the suitability of using preoperative PET-CT to determine the BV of patients who have surgical clips implanted prepectoral area.

## Methods

This study was conducted at Istanbul Training and Research Hospital of Radiation Oncology Department between January 2017 and June 2018, among breast cancer patients treated with radiation therapy, we selected thirty who had a pre-operative PET-CT performed and were the placement of surgical clips at prepectoral area. Ethics committee approval was received for this study from the Ethics Committee of Istanbul Training and Research Hospital (Date: April 12, 2019, No: 1793).

Pre-operative Fluorine-18-Fluorodeoxyglucose positron emission tomography (F-18 FDG PET/CT) was obtained while patients were lying in the supine position, and their arms were raised above the thorax. Patients who had metastasis after PET-CT were not included in the study.

For post-operative radiotherapy, planning tomography was taken with the breast board before treatment. The clinical breast borders and the lumpectomy scar were defined with radio-opaque wires. The planning tomography images covered from the mandible to the upper abdomen in 3-mm thick slices. Slices were sent to the treatment planning sys-

tem and merged using the available software (Eclipse 10.0). Then, breast irradiation volume and BV were contoured by a radiation oncologist. Planning target volumes (PTV) for BV were calculated by expanding the margin 1 cm beyond the surgical clips, maintaining a 5-mm margin from skin and chest wall. The same radiation oncologist contoured tumor volume (TV) on the pre-operative PET-CT. In defining TV in PET-CT, the cutoff of SUVmax value was defined as 6.20.<sup>[4]</sup> Two volumes defined as follows:

1. **PTV BV:** Target volume based on surgical clips with a margin of 1 cm
2. **PET-CT TV:** The target volume based on pre-operative PET-CT.

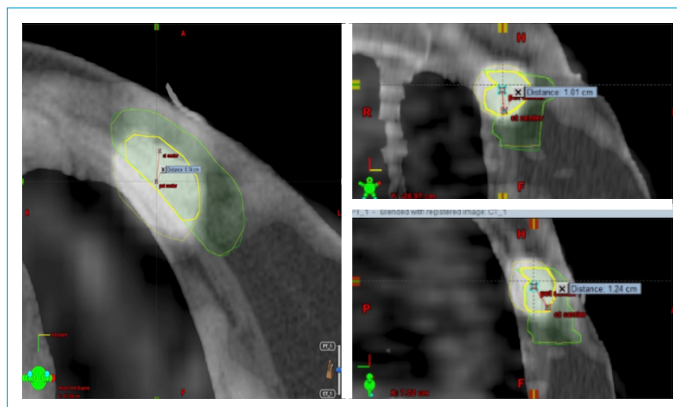
BV and primary TV in PET-CT were superimposed using rigid image fusion methods. During fusion, sternum and chest wall were taken as anatomical points. Both images were fused regarding these anatomical points. After then, breast tissue images were added by the manual fusion method. We calculated and compared these volumes in every patient.

The center of mass for volumes was determined (Fig. 1). Using coronal, axial, and sagittal CT slices of the planning treatment system, the mean shift of the center of volumes was calculated in terms of X, Y, and Z coordinates. Then, we calculated that inclusion percent volume of PET-CT TV included in PTV BV (total amount of PTV TV/included volume of PET-CT TV in PTV BV)

We analyzed 1-Variability of PTV-BV and PET-CT TV (cm<sup>3</sup>), 2-Mean shift between PTV-BV and PET-CT TV by calculation of the center of mass, and 3-PTV BV contains what percentage of PET-CT TV.

## Statistical Analysis

Nominal and ordinal data were described with frequency analysis, whereas scale parameters were described with



**Figure 1.** Rigid image fusion process between planning computed tomography (CT) and positron emission tomography-CT images. The center of mass volumes was determined.

mean and standard deviations. All statistical analyses were performed with SPSS software, version 18.0 (SPSS, Inc., Chicago, IL, USA). The mean shift calculated paired-sample t-test.  $P \leq 0.05$  was considered statistically significant.

## Results

Patient and treatment characteristics are shown in Table 1. The median age for patients was 52.83 (range 25–72) years. Almost all patients had invasive ductal carcinoma histology ( $n=27$ , 90%). The median tumor diameter was  $2.57 \pm 0.737$  (range 2–4) cm. The tumor was located in the right breast in 20 (66.7%) patients and the left breast in 10 (33.3%) patients. The number of patients with Stage I was 6 (26.7%), the number of patients with Stage II was 15 (50%), and the number of patients with Stage III was 7 (23.3%). After breast-conserving surgery, 6 (20%) patients received four cycles, 7 (23.3%) patients received six cycles, and 17 (56.7%) patients received eight cycles of chemotherapy.

Table 1. Patient and treatment characteristics		
	No of patient	%
Age, Mean $\pm$ SD	52.83 $\pm$ 12.30 (25–72)	
Histology		
Invasive ductal carcinoma	27	90
Invasive lobular carcinoma	1	3.3
Mucinöz carcinoma	2	6.7
Tumor diameter	2.57 $\pm$ 0.737 (2–4) cm	
Location		
Right	20	66.7
Left	10	33.3
Stage		
I	6	26.7
II	15	50.0
III	7	23.3
III	7	23.3
Regimen of chemotherapy		
4 (AC)	6	20.0
6 (FEC)	7	23.3
8 (4 AC+4 Taxol)	17	56.7
8 (4 AC+4 Taxol)	17	56.7
Radiation doses		
50+10 Gy	28	93.3
50+16 Gy	2	6.7
Interval between PET-CT and surgery (month)	3.43 $\pm$ 1.77 (1–8)	
Interval between surgery and radiotherapy (month)	4.22 $\pm$ 2.66 (2–7)	
Follow-up	25.63 $\pm$ 4.71 (14–34)	

AC: Adriablastina, cyclophosphamide; FEC: Flurourasil, epirubicine, cyclophosphamide.

As the radiotherapy dose, the majority of patients received 60 Gy radiotherapy, and only 2 (6.7%) patients received 66 Gy due to the positive surgical margin. The mean time between pre-operative PET-CT and breast-conserving surgery was the average  $3.43 \pm 1.77$  (1–8) months. The period between surgery and radiotherapy was  $4.22 \pm 2.66$  (2–7) months. The median follow-up period for 30 patients was 25.63 months.

The pre-operative PET-CT TV median was  $8.89 \text{ cm}^3$  (range 1.00–64.30  $\text{cm}^3$ ). The median PTVBV was  $62.92 \text{ cm}^3$  (12.57–123.07  $\text{cm}^3$ ). The median shifts between the center of volumes were 1.76 cm (range 0.90–3.50) in X (coronal), 1.73 cm (range 0.60–3.60) in the Y (axial), and 1.20 cm (0.40–2.80) in the Z (sagittal) directions. The shifts in every three planes were found statistically significant ( $p < 0.001$ ). In terms of axial, coronal, and sagittal planes, both volumes were different locations. All mean shifts between PET-CT TV and PTV BV were  $> 1$  cm. The percent volume of PET-CT TV included PTV BV ranged from 35% to 100% (mean 54%, standard deviation 29.53), and 100% in two out of 30 patients (Table 2). Pre-operative PET-CT TV was found completely outside of PTV BV in four of 30 patients, and particularly outside in 24 of the 30 patients. In the remaining two patients, the PET-CT TV was inside the PTV BV field.

## Discussion

Breast conservation surgery, followed by adjuvant irradiation of breast, has been used as a standard treatment for breast cancer.<sup>[4]</sup> The importance of adding a boost to radiotherapy treatment was shown by EORTC as Phase III study, especially in young breast cancer patients.<sup>[1]</sup> In randomized trials, the use of boost was associated with low local recurrence.<sup>[5]</sup> Therefore, it is very important in terms of radiation oncologists to accurately detect the BV. The surgical removal of breast tissue and the long time interval between surgery and radiotherapy may affect the correct definition of BV. Besides, surgical techniques, chemotherapy-induced

**Table 2.** Two volumes, mean shift three dimensions and intersections

	Mean	Min-Max	Std. Deviation	p
PET-CT TV ( $\text{cm}^3$ )	8.89	1.00–64.30	12.42	-
PTV-BV ( $\text{cm}^3$ )	62.92	12.57–123.07	27.80	-
X (cm)	1.76	0.90–3.50	0.75	0.000
Y (cm)	1.73	0.60–3.60	0.85	0.000
Z (cm)	1.20	0.40–2.80	0.40	0.000
Intersection % (PET-TV and PTV BV)	54.03	-	29.53	0.000

PET: Positron emission tomography; CT: Computed tomography; PTV: Planning target volume; BV: Boost volume; TV: Tumor volume.

weight loss may change the shape of the tumor bed. There are different approaches to define BV. Some clinics consider seroma with surgical clips, while some clinics consider mammography, breast USG, or breast MRI taken during the pre-operative period.

The surgical clips are one of the most reliable methods for identifying breast BV.<sup>[6]</sup> How many surgical clips are placed, and their locations have been defined in many studies during breast-conserving surgery.<sup>[7,8]</sup> Sometimes, surgical clips do not correctly identify the tumor bed. In some cases, they may have migrated elsewhere after the operation from their original location,<sup>[9]</sup> or they can be placed in the prepectoral area just like our study. To overcome these uncertainties, additional imaging modalities should be considered. The planning MRI, 3D USG, and PET-CT would be useful in defining the BV. In 2008, Whipp et al. suggested that an MRI scan may be better than a CT scan in determining the BV.<sup>[10]</sup> However, Smitt et al. found MRI detected a considerably lower conformity index and their study found that MRI was insufficient in operation bed locations in low adjustment cavity visualization scoring (Smitt et al., 1=no visible cavity, 2–4=heterogeneous cavity with indistinct, distinct, or clearly defined margins, and 5=homogenous cavity clearly defined margins).<sup>[11]</sup> Besides, breast MRI is not very appropriate, defining the BV due to the position. Breast MRI is performed in a prone position, while radiotherapy is performed in the supine position.<sup>[12,13]</sup> Wong et al. found that breast USG (both 3D and 2D) demonstrated a smaller surgical operation cavity than surgical clips.<sup>[14]</sup> If surgical clips on planning tomography are not available, 3D USG could be used. Further addition evaluations needed to clearly define the role of either 3D-USG, MRI in contouring BV.

In 2008, Ford et al.<sup>[15]</sup> first used PET-CT imaging technique for BV definition. They took PET-CT after surgery. They found the operation cavity was visualized well on PET-CT, but the PET-CT volumes larger than the planning tomography volumes. The reason for this was thought to be due to increased inflammation after surgery. In the our study, PET-CT was taken before surgery. Therefore, our PET-CT TV was smaller than PTV-TV (mean 8.89 cm<sup>3</sup> and 62.92 cm<sup>3</sup>, respectively). A Korean study by Cho et al. used an initial diagnostic PET-CT fusion with a post-operative CT scan for deformable image registration.<sup>[16]</sup> They found pre-operative and post-operative volumes were high level concordance (mean 94.8%, range 60.9–100%).

In contrast, the Korean study, we found that PET-CT TV inside PTV TV was revealed to be 54.03% (range 35–100%). This ratio is low in our study may be the reason we used rigid fusion. The deformable image fusion technique provides

better BV definitions in cases where the tissue is removed, relocated, and altered due to surgical procedures.<sup>[17]</sup>

Another controversial issue is the mean shift in three dimensions. We found that displacement in axial, coronal, and sagittal planes was >1 cm. Therefore, our results are similar to the results of Alço et al. They applied the latissimus dorsi muscle mini-flap to determining the BV after breast-conserving surgery.<sup>[18]</sup> Large displacement may be due to the placement clips in the prepectoral area, not only four cardinal points. The placement of surgical clips at superior, inferior, medial, and lateral points of the surgical cavity and large PTV margins maybe resolve this issue. These results suggest that the use of pre-operative PET-CT TV can not be very accurate for determining the BV.

### Limitations

The most important limitation of this study, we are not done breast remodeling after surgery. When defining the accurate BV in breast cancer patients, a multidisciplinary team should be used, not surgical clips and additional imaging modalities. A multidisciplinary team involving breast surgery, radiotherapists, radiologist, and medical physics. We see a need further studies and guides for better define BV after breast-conserving surgery.

### Conclusion

The present study has demonstrated that boost volume is noticeably replaced between pre-operative PET-CT and planning CT. Therefore, pre-operative PET-CT cannot be very accurate in determining breast BV in patients who have surgical clips on prepectoral area.

### Disclosures

**Ethics Committee Approval:** Ethics committee approval was received for this study from the Ethics Committee of Istanbul Training and Research Hospital (Date: April 12, 2019, No: 1793).

**Peer-review:** Externally peer-reviewed.

**Conflict of Interest:** None declared.

**Authorship Contributions:** Concept – B.I., B.O.; Design – B.I., B.O.; Supervision – O.M., K.I.; Materials – B.I., B.O., O.M.; Data collection &/or processing – B.I., B.O., O.M.; Analysis and/or interpretation – B.I., K.I.; Literature search – K.I., O.M.; Writing – B.I.; Critical review – K.I., B.O., O.M.

### References

1. Bartelink H, Horiot JC, Poortmans PM, Struikmans H, Van den Boogaert W, Fourquet A, et al. Impact of a higher radiation dose on local control and survival in breast-conserving therapy of early breast cancer: 10-year results of the randomized boost versus no boost EORTC 22881-10882 trial. *J Clin Oncol* 2007;25:3259–65.
2. Ebner F, de Gregorio N, Rempen A, Mohr P, de Gregorio A, Wöckel

- A, et al. To clip or not to clip the breast tumor bed? A retrospective look at the geographic miss index and normal tissue index of 110 patients with breast cancer. *J Turk Ger Gynecol Assoc* 2017;18:67–71. [\[CrossRef\]](#)
3. Giezen M, Kouwenhoven E, Scholten AN, Coerkamp EG, Heijbroek M, Jansen WP, et al. MRI- versus CT-based volume delineation of lumpectomy cavity in supine position in breast-conserving therapy: an exploratory study. *Int J Radiat Oncol Biol Phys* 2012;82:1332–40. [\[CrossRef\]](#)
  4. Kitajima K, Yamano T, Miyoshi Y, Katsuura T, Enoki T, Yamakado K. Prognostic value of 18F-FDG PET/CT prior to breast cancer treatment. Comparison with magnetic resonance spectroscopy and diffusion weighted imaging. *Hell J Nucl Med* 2019;22:25–35.
  5. Early Breast Cancer Trialists' Collaborative Group (EBCTCG), Darby S, McGale P, Correa C, Taylor C, Arriagada R, Clarke M, et al. Effect of radiotherapy after breast-conserving surgery on 10-year recurrence and 15-year breast cancer death: meta-analysis of individual patient data for 10,801 women in 17 randomised trials. *Lancet* 2011;378:1707–16. [\[CrossRef\]](#)
  6. Bartelink H, Maingon P, Poortmans P, Weltens C, Fourquet A, Jager J, et al; European Organisation for Research and Treatment of Cancer Radiation Oncology and Breast Cancer Groups. Whole-breast irradiation with or without a boost for patients treated with breast-conserving surgery for early breast cancer: 20-year follow-up of a randomised phase 3 trial. *Lancet Oncol* 2015;16:47–56. [\[CrossRef\]](#)
  7. Kirova YM, Castro Pena P, Hijal T, Fournier-Bidoz N, Laki F, Sigal-Zafarani B, et al. Improving the definition of tumor bed boost with the use of surgical clips and image registration in breast cancer patients. *Int J Radiat Oncol Biol Phys* 2010;78:1352–5. [\[CrossRef\]](#)
  8. Strnad V, Hannoun-Levi JM, Guinot JL, Lössl K, Kauer-Dorner D, Resch A, et al; Working Group Breast Cancer of GEC-ESTRO. Recommendations from GEC ESTRO Breast Cancer Working Group (I): Target definition and target delineation for accelerated or boost Partial Breast Irradiation using multicatheter interstitial brachytherapy after breast conserving closed cavity surgery. *Radiother Oncol* 2015;115:342–8. [\[CrossRef\]](#)
  9. Major T, Gutiérrez C, Guix B, van Limbergen E, Strnad V, Polgár C; Breast Cancer Working Group of GEC-ESTRO. Recommendations from GEC ESTRO Breast Cancer Working Group (II): Target definition and target delineation for accelerated or boost partial breast irradiation using multicatheter interstitial brachytherapy after breast conserving open cavity surgery. *Radiother Oncol* 2016;118:199–204. [\[CrossRef\]](#)
  10. Yang Z, Chen J, Hu W, Pan Z, Cai G, Yu X, et al. Planning the breast boost: how accurately do surgical clips represent the CT seroma? *Radiother Oncol* 2010;97:530–4. [\[CrossRef\]](#)
  11. Whipp EC, Halliwell M. Magnetic resonance imaging appearances in the postoperative breast: the clinical target volume-tumor and its relationship to the chest wall. *Int J Radiat Oncol Biol Phys* 2008;72:49–57. [\[CrossRef\]](#)
  12. Smitt MC, Birdwell RL, Goffinet DR. Breast electron boost planning: comparison of CT and US. *Radiology* 2001;219:203–6. [\[CrossRef\]](#)
  13. Kirby AM, Yarnold JR, Evans PM, Morgan VA, Schmidt MA, Scurr ED, et al. Tumor bed delineation for partial breast and breast boost radiotherapy planned in the prone position: what does MRI add to X-ray CT localization of titanium clips placed in the excision cavity wall? *Int J Radiat Oncol Biol Phys* 2009;74:1276–82. [\[CrossRef\]](#)
  14. Wong P, Muanza T, Reynard E, Robert K, Barker J, Sultanem K Use of three-dimensional ultrasound in the detection of breast tumor bed displacement during radiotherapy. *Int J Radiat Oncol Biol Phys*. 2011;79:39–45. [\[CrossRef\]](#)
  15. Ford EC, Lavelly WC, Frassica DA, Myers LT, Asrari F, Wahl RL, et al. Comparison of FDG-PET/CT and CT for delineation of lumpectomy cavity for partial breast irradiation. *Int J Radiat Oncol Biol Phys* 2008;71:595–602. [\[CrossRef\]](#)
  16. Cho O, Chun M, Oh YT, Kim MH, Park HJ, Heo JS, et al. Can initial diagnostic PET-CT aid to localize tumor bed in breast cancer radiotherapy: feasibility study using deformable image registration. *Radiat Oncol* 2013;8:163. [\[CrossRef\]](#)
  17. Kirova YM, Servois V, Reyat F, Peurien D, Fourquet A, Fournier-Bidoz N. Use of deformable image fusion to allow better definition of tumor bed boost volume after oncoplastic breast surgery. *Surg Oncol* 2011;20:e123–5. [\[CrossRef\]](#)
  18. Alço G, Igdem S, Okkan S, Dincer M, Sarsenov D, Ilgun AS, et al. Replacement of the tumor bed following oncoplastic breast-conserving surgery with immediate latissimus dorsi mini-flap. *Mol Clin Oncol* 2016;5:365–71. [\[CrossRef\]](#)