

# Lung Adenocarcinoma's Rare Metastasis: Tongue Metastasis

 Saibe Fulya Elmastaş Akkuş

Department of Pulmonology,  
University of Health Sciences  
Kartal Dr. Lütfi Kırdar City Hospital,  
İstanbul, Türkiye

Submitted: 22.07.2024  
Revised: 03.08.2024  
Accepted: 05.08.2024

Correspondence: Saibe Fulya  
Elmastaş Akkuş,  
Department of Pulmonology,  
University of Health Sciences  
Kartal Dr. Lütfi Kırdar City Hospital,  
İstanbul, Türkiye  
E-mail: flyelmastas@hotmail.com



## Keywords:

Adenocarcinoma; lung;  
metastasis; tongue.



This work is licensed under a Creative Commons  
Attribution-NonCommercial 4.0 International License.

## ABSTRACT

When examining oral cavity tumors, the incidence of metastatic tumors is quite low. Most of these metastases occur in the mandible, with only a small portion involving soft tissues. Generally, the most common sites for metastases from lung cancer are the brain, adrenal glands, bones, and the contralateral lung, while the incidence of metastases to the tongue is reported to be approximately 0.2% to 1.6%. Patients with tongue metastases from lung cancer usually have a poor prognosis, making early diagnosis important. This case presentation aims to discuss a 62-year-old male patient with lung adenocarcinoma who presented with dysphagia and was found to have tongue metastasis. No distant metastases were detected apart from the tongue and cervical lymph node metastases. Systemic treatment was initiated for the patient diagnosed with stage 4 lung adenocarcinoma.

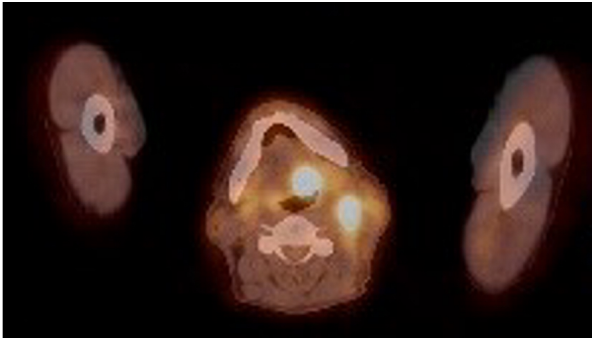
## INTRODUCTION

Lung cancer ranks first among cancer-related deaths worldwide.<sup>[1]</sup> Symptoms, diagnosis, treatment approach, and survival in lung cancer vary depending on the location, invasion, and local or distant metastasis of the tumor. While the brain, liver, adrenal glands, bone, bone marrow, contralateral lung, and kidneys are the most common sites of metastasis in lung cancer, it can metastasize to any part of the body, though this is rare.<sup>[2]</sup> Metastasis to the oral cavity is very rare and accounts for approximately 1% of all oral malignancies.<sup>[3]</sup> Among metastatic oral cavity tumors, primary lung malignancy accounts for 0.1%.<sup>[4]</sup> Metastases in the oral cavity are most commonly seen in the mandible, with soft tissue metastases being rarer.<sup>[5]</sup> Although metastasis to the tongue is rare, advanced investigations should be planned when a lesion is detected on the tongue due to the generally poor prognosis and alteration of disease stage in patients with lung cancer.<sup>[6]</sup>

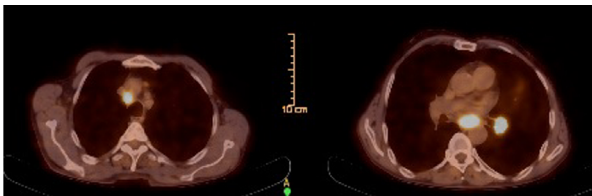
## CASE REPORT

A 62-year-old male patient with a history of known peripheral artery disease presented to our Ear, Nose, and Throat clinic with unintentional weight loss and swelling in the left cervical area. The patient, who had a smoking history of 55 pack-years, was found to be an active smoker. On physical examination, a fixed, hard, painless lymph node approximately 2x1 cm in size was palpated in the left cervical area, and another lymph node approximately 1x1 cm in size was palpated in front of the sternocleidomastoid muscle on the right side. Laboratory tests revealed no abnormalities in complete blood count and biochemistry values.

Ultrasonography revealed multiple spherical-shaped pathological lymph nodes without fatty hilum in bilateral submandibular and cervical chains, with the largest being 12x11 mm in size in the upper cervical chain on the left side. Fine-needle aspiration biopsy taken from the left cervical lymph node supported a malignant epithelial tumor, with the thyroid and lung considered as the primary focus, prompting a Positron Emission Tomography-Computer



**Figure 1.** Lesion on the posterior segment of the left lateral tongue and cervical lymph nodes on PET-CT.



**Figure 2.** Lesion in the left hilum, right upper paratracheal and subcarinal lymphadenopathy on PET-CT.

Tomography (PET-CT) scan (Figure 1). The PET-CT scan revealed a lesion measuring 15x20 mm with maximum standardized uptake value (SUVmax):11.1 in the posterior segment of the left lateral tongue, conglomerate lymph nodes with SUVmax:9.6 at cervical levels 2, 3, and 5A, with the largest being approximately 18x12 mm, and lymph nodes with a diameter of 1 cm and SUVmax:3.6 at level 4 on the right side (Figure 2). In the thoracic and mediastinal sections, a lesion measuring 2 cm with SUVmax:10.5 in the left lung hilum was observed, and nodules with significant fluorodeoxyglucose uptake in the left lower lobe and lymphadenopathies in the right upper paratracheal, subcarinal, and left hilar areas, with the largest measuring 25x15 mm with SUVmax:11.2, were observed. Diagnostic endobronchial ultrasound (EBUS) was planned for the lesions described in the lung and mediastinum.

During the EBUS procedure, transbronchial needle aspiration was performed three times from oval, well-defined hypoechoic lymphadenomegaly (LAM) with a short axis of 1.3 cm seen in the right lower paratracheal area and oval, heterogeneous LAM with a well-defined border and a short axis of 1.4 cm seen in the left hilar area. Pathological examination revealed lung adenocarcinoma. Since the patient also experienced swelling in the tongue and impairment in articulation and swallowing functions, multiple deep punch biopsies were taken from the mass seen on the left lateral aspect of the tongue during simultaneous endolaryngeal microsurgery and direct laryngoscopy. Pathological examination supported the diagnosis of lung adenocarcinoma metastasis. Treatment was initiated for stage 4 lung adenocarcinoma, and the patient was found to be deceased approximately 3 months after diagnosis during follow-up.

## DISCUSSION

Symptoms of primary lung cancer often include cough, sputum, and hemoptysis due to irritation of the respiratory mucosa. However, when tongue metastasis occurs, it typically results in dysphagia.<sup>[7]</sup> In our case, the patient presented primarily with swelling in the neck, and a biopsy of the lesion in the tongue was performed when dysphagia developed during follow-up, leading to the diagnosis of lung adenocarcinoma metastasis. Similarly, in the case presented by Cheng et al.,<sup>[8]</sup> the patient's admission to the hospital was due to hemoptysis and chronic cough, and the diagnosis of metastasis was made when the patient noticed swelling and pain in the tongue. Therefore, when investigating patients for lung cancer, dysphagia should also be considered. According to the literature, the rates of tongue metastasis in patients diagnosed with lung cancer are approximately 0.2% to 1.6%.<sup>[9]</sup> In a study by Zegarelli et al.,<sup>[6]</sup> 12 cases of tongue metastasis were detected in autopsies of 6,881 malignant patients, with a rate of 0.2%. Among all malignancies, 579 were primary lung cancer, and tongue metastasis was detected in only 2 cases (0.3%). In the study by Baden et al.,<sup>[10]</sup> it was reported that the metastases to the tongue were 21% lung, 21% kidney, and 17% skin-derived. Tongue metastases are usually located in the base of the tongue. The reason for this is thought to be the richness of the base of the tongue in vascular and lymphatic structures and its relative immobility.<sup>[11]</sup> As in our case and in the case presented by Cheng et al.,<sup>[8]</sup> metastasis was observed at the base of the tongue. Additionally, since metastasis was also detected in the cervical lymph nodes in our case, the metastasis at the base of the tongue suggests that lymphatic spread may be the primary route. However, there are also case presentations in the literature showing metastasis to the anterior part of the tongue.<sup>[11,12]</sup> This indicates that advanced investigations should be planned when a suspicious lesion of metastasis is detected regardless of its location in the oral cavity. Regarding treatment, surgery can be performed for patients with oligometastatic disease only if metastasis is limited to the tongue, but systemic treatment is more appropriate if metastasis occurs elsewhere. As in our case and in the case presented by Güven et al.,<sup>[13]</sup> systemic treatment was administered to patients due to metastases to the cervical lymph nodes and the base of the tongue. According to the study by Baden et al.,<sup>[10]</sup> the prognosis is poor in patients with tongue metastasis, with an average estimated survival time of six months. This is presumed to be due to the fact that metastasis to other sites usually occurs until the disease has metastasized to the head and neck region, indicating an advanced stage. Similarly, during follow-up of our case, the patient was found to be deceased approximately 3 months after diagnosis.

## Conclusion

In conclusion, with this case presentation, we aimed to emphasize that tongue metastases in lung cancers should be taken into consideration due to their rarity and poor

prognosis. And although it is rare, it should be noted that dysphagia may be a signal of tongue metastasis.

#### Informed Consent

Retrospective study.

Peer-review

Externally peer-reviewed.

#### Conflict of Interest

The authors declare that there is no conflict of interest.

## REFERENCES

1. Torre LA, Bray F, Siegel RL, Ferlay J, Lortet-Tieulent J, Jemal A. Global cancer statistics, 2012. *CA Cancer J Clin* 2015;65:87–108. [CrossRef]
2. Savaş R, Alper H. Akciğer kanserlerinde radyolojik görüntüleme. In: Haydaroğlu A, editor. Akciğer Kanseri: Tanı ve Tedavi. İzmir: Ege Üniversitesi Basımevi; 2000. p. 121–37.
3. Zachariades N. Neoplasms metastatic to the mouth, jaws and surrounding tissues. *J Craniomaxillofac Surg* 1989;17:283–90. [CrossRef]
4. Hirshberg A, Buchner A. Metastatic tumours to the oral region. An overview. *Eur J Cancer B Oral Oncol* 1995;31B:355–60. [CrossRef]
5. Yoshii T, Muraoka S, Sano N, Furudoi S, Komori T. Large cell carcinoma of the lung metastatic to the mandibular gingiva. *J Periodontol* 2002;73:571–4. [CrossRef]
6. Zegarelli DJ, Tsukada Y, Pickren JW, Greene GW Jr. Metastatic tumor to the tongue. Report of twelve cases. *Oral Surg Oral Med Oral Pathol* 1973;35:202–11. [CrossRef]
7. Majumder KR, Karmakar R, Alam MM, Rahman T. Carcinoma tongue Clinicopathological presentation. *Mymensingh Med J* 2015;24:787–93.
8. Cheng X, Hu Z, Han YP, Bai C. A case report of tongue metastasis from lung squamous cell carcinoma and literature review. *Medicine (Baltimore)* 2017;96:e8208. [CrossRef]
9. Terashima T, Matsuzaki T, Kawada I, Nishida J, Tanaka Y, Morishita T, et al. Tongue metastasis as an initial presentation of a lung cancer. *Intern Med* 2004;43:727–30. [CrossRef]
10. Baden E, Duvillard P, Micheau C. Metastatic papillary endometrial carcinoma of the tongue. Case report and review of the literature. *Arch Pathol Lab Med* 1992;116:965–8.
11. Mavili E, Oztürk M, Yücel T, Yüce I, Çağlı S. Tongue metastasis mimicking an abscess. *Diagn Interv Radiol* 2010;16:27–9.
12. Jeba J, Backianathan S, Ishitha G, Singh A. Oral and gastrointestinal symptomatic metastases as initial presentation of lung cancer. *BMJ Case Rep* 2016;2016:bcr2016217539. [CrossRef]
13. Güven M, Öcal S, Eyibilen A, Aladağ İ, Köseoğlu D. Lung adenocarcinoma: A rare metastasis to the tongue. *Balkan Med J* 2010;2010:218–20.

### Akciğer Adenokarsinomunun Nadir Metastazı: Dil Metastazı

Oral kavite tümörleri incelendiğinde metastatik tümör görülme oranı oldukça düşüktür. Bu metastazların çoğu mandibulaya olmakla beraber az bir kısmı yumuşak dokuya olmaktadır. Genel olarak akciğer kanserinin metastazlarına bakıldığında ise en sık beyin, sürrenal, kemik, karşı akciğer metastazı görülürken dile metastaz oranları yaklaşık olarak %0.2-1.6 olarak bildirilmiştir. Dilde metastaz saptanan akciğer kanseri tanılı hastaların genellikle prognozu kötü seyretmektedir. Bu sebeple erken tanı konulması önemlidir. Bu olgu sunumunda tarafımıza disfaji ile başvuran dil metastazı saptanan akciğer adenokarsinomlu 62 yaşında erkek hasta sunulması amaçlandı. Hastada dil ve servikal lenf nodu metastazları dışında uzak metastazı saptanmadı. Evre 4 akciğer adenokarsinomu tanısı konulan hastaya sistemik tedavi başlandı.

**Anahtar Sözcükler:** Akciğer adenokarsinom; dil; metastaz.