

Rare Manifestation of Epithelioid Type Malignant Pleural Mesothelioma: Recurrent Pneumothorax

Epiteloid Tip Malign Plevral Mezotelyoma'nın Nadir Prezantasyonu: Tekrarlayan Pnömotoraks

İrmak Akarsu¹, Elgun Valiyev¹, Tuğba Körpeoğlu², Şevki Mustafa Demiröz¹, Nalan Akyürek²

Abstract

Malignant pleural mesothelioma (MPM) is a rare and aggressive tumor that leads to approximately 20,000 deaths per year. The most common symptoms are chest pain, shortness of breath, cough and weight loss. Radiologic studies usually reveal pleural thickening and pleural effusion, although the disease can also rarely present with spontaneous pneumothorax or hydropneumothorax. We present here a case of a 57-year-old male diagnosed with occult epithelioid type MPM based on video thoracoscopic (VATS) exploration and biopsy who experienced recurrent pneumothorax attacks and prolonged air leakage. Although there are few symptoms or imaging findings specific to MPM, elderly patients with recurrent pneumothorax attacks should be questioned for asbestos exposure, and MPM should be kept in mind in the differential diagnosis.

Keywords: Pneumothorax, malignant mesothelioma, thoracic injuries.

Öz

Malign plevral mezotelyoma (MPM), yılda yaklaşık 20.000 ölüme neden olan nadir ve agresif bir tümördür. En sık görülen semptomlar göğüs ağrısı, nefes darlığı, öksürük ve kilo kaybıdır. Radyolojik incelemeler genellikle plevral kalınlaşma ve plevral efüzyonu ortaya koyar ancak hastalık nadiren spontan pnömotoraks veya hidropnömotoraks ile de ortaya çıkabilir. Bu olgu sunumunda tekrarlayan pnömotoraks atakları ve uzamış hava kaçağı olan 57 yaşındaki erkek hastada video torakoskopik (VATS) inceleme ve biyopsi ile tanı alan epiteloid tip MPM sunulmaktadır. MPM'ye özgü herhangi bir semptom veya görüntüleme bulgusu olmasa da tekrarlayan pnömotoraks atağı geçiren yaşlı hastalar asbest maruziyeti açısından sorgulanmalı ve ayırıcı tanıda MPM akılda tutulmalıdır.

Anahtar Kelimeler: Pnömotoraks, malign mezotelyoma, göğüs yaralanmaları.

¹Department of Thoracic Surgery, Gazi University of Medical School, Ankara, Türkiye

²Department of Pathology, Gazi University of Medical School, Ankara, Türkiye

¹Gazi Üniversitesi Tıp Fakültesi, Göğüs Cerrahisi Anabilim Dalı, Ankara

²Gazi Üniversitesi Tıp Fakültesi, Patoloji Anabilim Dalı, Ankara

Submitted (Başvuru tarihi): 29.11.2023 Accepted (Kabul tarihi): 14.12.2023

Correspondence (İletişim): İrmak Akarsu, Department of Thoracic Surgery, Gazi University of Medical School, Ankara, Türkiye

e-mail: irmaksh@gmail.com



Mesothelioma occurs as a result of the neoplastic transformation of mesothelial cells on serosal surfaces, including the pleura, pericardium, peritoneum and tunica vaginalis. Chronic asbestos exposure is the most common cause of MPM. The average survival time is one year, and can be extended only with early diagnosis (1). The latency period following asbestos exposure can last 30–40 years. The disease usually manifests with chest pain, shortness of breath, cough and weight loss (2,3). The most common imaging findings are pleural effusion and thickening, although it may rarely present with pneumothorax and hydropneumothorax (3). Many previous studies have reported spontaneous pneumothorax accompanying malignancies (4). Here, we present a rare case with an epithelioid-type malignant mesothelioma who presented with recurrent pneumothorax as the first sign of the disease.

CASE

A 57-year-old male patient presented to the emergency room with shortness of breath and chest pain following a traffic accident. While no significant fractures were noted in the bony structures of the chest wall, a large left-sided pneumothorax was detected, and a tube thoracostomy was performed. The patient had no additional problems during follow-up and complete lung expansion was achieved, and the tube thoracostomy was subsequently terminated. The patient was discharged on the 3rd day, but was readmitted with chest pain 2 days later with recurrent pneumothorax on the left side (Figure 1), and a further tube thoracostomy was performed. Despite the chest tube treatment, the patient developed subcutaneous emphysema and massive prolonged air leakage that persisted even after autologous blood pleurodesis. The patient was transferred to our clinic on the 10th day of follow-up when a renewed thorax CT revealed subcutaneous emphysema, pleural effusion, and pneumothorax on the left hemithorax. Although not mentioned in the report, pleural thickening and hematoma-like appearances were seen on the diaphragm, pericardium, and costophrenic sinus (Figure 2). It was thought that previously performed autologous blood pleurodesis could have led to this tomography image.

The patient had no accompanying disease, although a detailed medical history revealed environmental asbestos exposure. VATS exploration was planned for the treatment of prolonged air leaks. Although no apparent bullous areas were observed on exploration, multiple nodular lesions on both the visceral and parietal pleura were accompanied by a small amount of pleural fluid (Figure 3). Multiple biopsies were taken from the nodular areas on the parietal pleura, a fistula seen on the surface of the

apical visceral upon inflation was resected with a wedge resection, and pleural fluid was sampled.

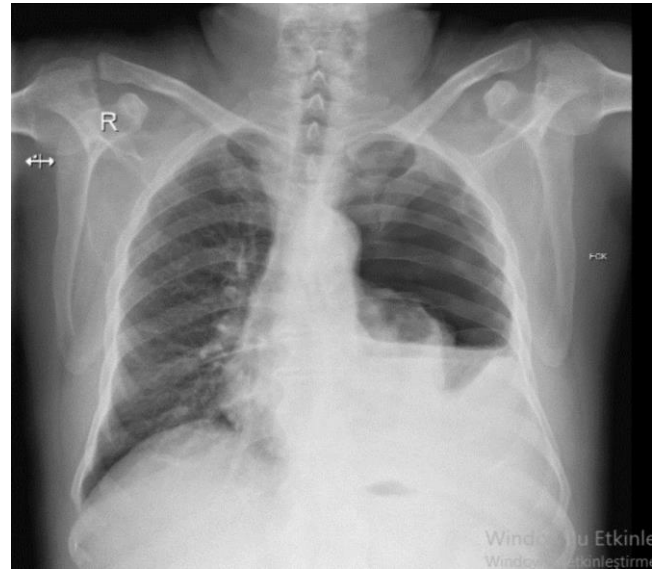


Figure 1: Preoperative left hydropneumothorax seen on chest X-ray

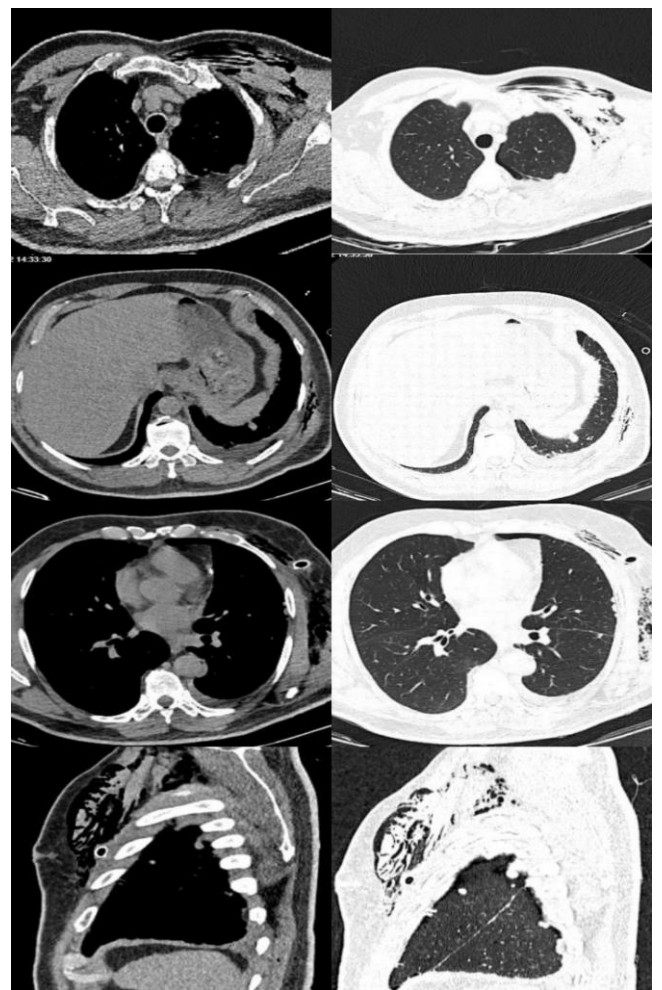


Figure 2: Thorax CT sections, showing pleural nodulation, pleural effusion, pneumothorax and subcutaneous emphysema in the left hemithorax

Table 1: Series of epithelioid MPM presenting with pneumothorax

Author	Number of patients	Age of Patients	Clinic presentation	Side	Histopathologic subtype
Nakazawa	1		Pneumothorax	Left	Mixed
Ohkado	1		Pneumothorax		UD
Tanaka	8		Hydropneumothorax (8)		Epithelioid
Gotoh	1		Pneumothorax	Right	UD
Katayam	1		Hydropneumothorax	Right	Mixed
Makidono	1	44	Pneumothorax	Right	Epithelioid
Takeuchi	1		Pneumothorax	left	UD
Mitsui	2	57 / 63	Pneumothorax (1)/ Hydropneumothorax (1)	right	Epithelioid
Sheard	5		Pneumothorax (5)	Left (3)/Right (2)	Epithelioid (2) Mixed (3)
Alkhuja	4	81/81/56/70	Pneumothorax (2)/ Hydropneumothorax(2)	Left (2)/ Right (2)	Epithelioid (3) Sarcomatoid (1)
Saleh	2	70 / 71	Pneumothorax	Right(2)	Epithelioid (2)
Fukui	1	62	Pneumothorax	Bilaterally	Biphasic
Sattar	1	79	Pneumothorax	Right	Epithelioid
Delapp	1	67	Hydropneumothorax	Right	Epithelioid
Fayed	1	69	Hydropneumothorax	Bilaterally	Epithelioid
Wu	1	69	Hydropneumothorax	Right	UD
Guha	1	73	Hydropneumothorax	Right	Epithelioid
Prasad	1	69	Pneumothorax	Right	UD (low grade)
Situnayake	1	54	Pneumothorax	Right	UD
Ema	1	61	Hydropneumothorax	Right	Epithelioid

A histopathological examination of the wedge resection material and the pleural biopsy revealed a malignant epithelial tumor. Tumor cells were positive for immunohistochemical (IHC) markers CK5/6, calretinin and WT1, and negative for TTF-1, and a loss of the BAP-1 protein was identified (Figure 4). No atypical cells were observed in pleural fluid. The final pathology was reported as "Epithelioid type MPM".

Postoperative follow-up was uneventful, and complete lung expansion was achieved on the second day, after which the chest tube was removed, and the patient was discharged on the 3rd postoperative day. Due to an unexpected diagnosis of MPM, a PET-CT was planned for staging and distant metastasis. No pathologic 18 F-FDG uptake was noted on the pleural surfaces, lymph nodes or extrathoracic regions (Figure 5). An extrapleural pneumonectomy was planned, and the patient was referred to the oncology clinic for neoadjuvant treatment.

DISCUSSION

MPM is a rare and aggressive tumor that has been linked to approximately 20,000 deaths a year (2). It can manifest with non-specific symptoms such as loss of appetite and weight, in addition to the most common symptoms

associated with the pleural neoplasia itself, such as pleural thickening, effusion and pain due to thoracic wall invasion. Cases of spontaneous pneumothorax and hydropneumothorax have been rarely reported in literature (1,3). The most common symptoms of MPM and pneumothorax are chest pain and shortness of breath (3,4). In our case, the symptoms at the time of admission were chest pain and shortness of breath following a traffic accident, and recurrent pneumothorax was the manifestation type.

Mitsui et al. (3) reported male dominance and a mean age of 58 years in their study of 16 cases with MPM presenting with pneumothorax. In our case, the patient was a 57-year-old male.

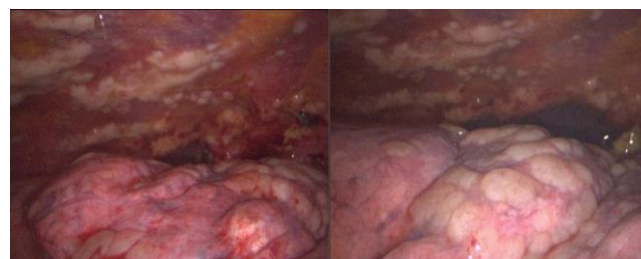


Figure 3: Nodular formation seen on video thoracoscopic imaging

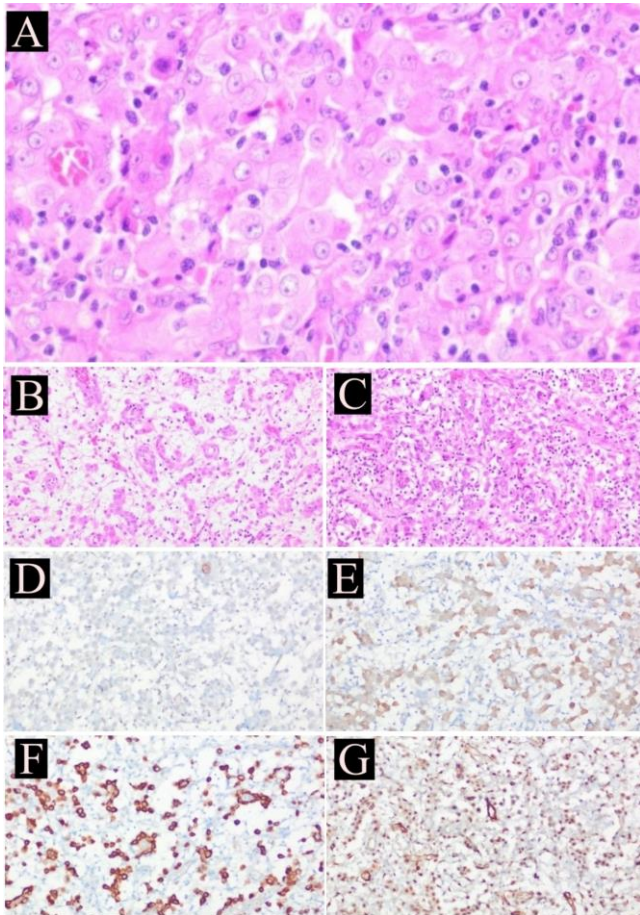


Figure 4: Epithelioid mesothelioma. Tumor cells with eosinophilic cytoplasm, vesicular nuclei and prominent nucleoli (H&E x400) (A), Tubulopapillary pattern. Tumor cells form tubules and papillae. (H&E x200) (B), Lymphohistiocytic pattern. Polygonal tumor cells in lymphocytic infiltrate with a histiocytic morphology (H&E x200) (C), BAP1 loss from tumor cells x200 (D), Calretinin x200 (E), Ceratin 5-6 x200 (F), WT-1 x200 (G)

The first case of spontaneous pneumothorax secondary to MPM to be reported was published by Eisenstadt in 1956. Although the etiologic mechanism of pneumothorax development in MPM patients is uncertain, three mechanisms have been suggested: (i) rupture of necrotic tumor nodules, (ii) formation and rupture of subpleural bullae, developed by peripherally located tumor nodules and (iii) pleural spread of the tumor. Included in the study by Mitsui et al. (3) were 16 MPM patients with spontaneous pneumothorax, of which nine patients had right-sided, six patients had left-sided, and one patient had bilateral pneumothorax. Of the total, 11 of the patients developed recurrent pneumothorax, and nine had an accompanying pleural effusion. Similarly, the case in the present study had recurrent pneumothorax and an accompanying pleural effusion.

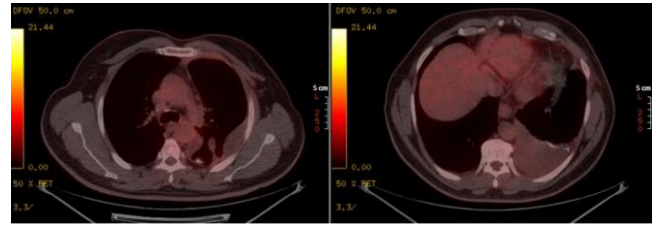


Figure 5: Pathological ^{18}F -FDG uptake observed in areas with pleural thickening and pleural effusion on PET-CT

Thorax CT is the most common imaging approach to the diagnosis and staging of MPM, given its ability to reveal pleural effusion, thickening and nodulation, mass appearances, mediastinal shifts and invasions of the surrounding tissues (3). In their study of 84 MPM patients, Sahin et al. (2) reported unilateral pleural thickening, nodulation or mass (100%), pleural effusion (73%), mediastinal pleural involvement (93%) and volume loss (22%) as the most common CT findings. However, especially in early-stage patients, no significant findings may be seen on CT (5).

A tissue biopsy is required for the definitive diagnosis of MPM, while a pathological diagnosis of MPM is difficult as its morphological patterns can mimic many epithelial and non-epithelial malignancies. IHC studies are necessary to rule out other malignancies, but as there is not highly sensitive or specific marker for MPM, at least two carcinoma markers (e.g., pCEA BER -EP4, MOC -31, Claudin 4, HEG1) and two mesothelial markers (WT1, calretinin, CK5/6, D2-40) are recommended (6). While the positivity of some IHCs such as pancreatin, CK5/6, calretinin and WT-1 can support a mesothelioma diagnosis, CEA, CD15 and TTF-1 are generally negative in MPM (7). Our case was positive for CK5/6, calretinin and WT-1, and negative for TTF-1, similar to previous studies in literature.

PET-CT is useful for staging MPM based on the evaluation of the pleural surface, lymph nodes, contralateral lung and distant metastases (6). In our case, the preoperative CT findings did not suggest MPM. Moreover, autologous blood pleurodesis complicated the evaluation of the pleural surfaces. Despite intraoperative explorations revealing multiple lesions on both the visceral and parietal pleura, there was no pathologic ^{18}F -FDG uptake on postoperative PET-CT which we attributed to the low-grade mesothelioma of our patient.

A multimodal approach is recommended for the treatment of MPM, including surgery, neoadjuvant and/or adjuvant chemotherapy, and radiotherapy. After the surgical removal of the tumor (pleurectomy/decortication,

extrapleural pneumonectomy), local recurrence can be controlled with radiotherapy, and distant metastases and micrometastases with chemotherapy (2,6). Our case is receiving neoadjuvant chemotherapy, and upon completion, extrapleural pneumonectomy is planned.

A review of literature related to cases of MPM presenting with pneumothorax suggests that all histological variants of MPM (epithelioid, sarcomatoid and mixed type) may be involved in the etiology, although it is worthy of note that most cases presenting with pneumothorax have an epithelioid-type MPM (1,3,7-11) (Table- 1). Ours is the 37th case to be presented to literature in English, in which six are undefined in terms of type, while 24 (64.86%) are the epithelioid type. Epithelioid-type MPM is the most common in all cases, with a slowly increasing prevalence (5). Some patients may present with such rare manifestations of the disease before the typical common symptoms of MPM occur.

CONCLUSION

MPM is an aggressive form of pleural neoplasia with a poor prognosis that can manifest alongside such rare conditions as spontaneous pneumothorax. A histopathological examination is necessary for the definitive diagnosis, and while thorax CT can support a diagnosis, trauma or previous autologous blood pleurodesis may mask CT findings. Patients of advanced age with recurrent pneumothorax attacks and challenging prolonged air leakage despite appropriate treatment should be questioned for risk factors of MPM, and surgical exploration should not be avoided, even if there are no apparent findings from imaging studies. Pneumothorax as the first sign is likely to point to the epithelioid subtype of the condition.

CONFLICTS OF INTEREST

None declared.

AUTHOR CONTRIBUTIONS

Concept - I.A., E.V., T.K., Ş.M.D., N.A.; Planning and Design - I.A., E.V., T.K., Ş.M.D., N.A.; Supervision - I.A., E.V., T.K., Ş.M.D., N.A.; Funding -; Materials - I.A., E.V., T.K.; Data Collection and/or Processing - I.A., Ş.M.D.; Analysis and/or Interpretation - I.A., E.V.; Literature Review - I.A., T.K.; Writing - I.A.; Critical Review - Ş.M.D., N.A.

REFERENCES

1. Hinkamp CA, Dalal SN, Butt Y, Cabo Chan AV. Diffuse epithelioid malignant mesothelioma of the pleura presenting as a hydropneumothorax and vertebral body invasion. *BMJ Case Rep* 2020; 13:e231987. [\[CrossRef\]](#)
2. Arpat AH, Bayulgen A, Tulay CM, Ciftci T, Tercan M. Tekrarlayan spontan pnömotoraks ile prezente olan malign mezotelyoma. *Causapedia* 2017; 6: 6-11.
3. Mitsui A, Saji H, Shimmyo T, Mochizuki A, Kurimoto N, Nakamura H. Malignant pleural mesothelioma presenting as a spontaneous pneumothorax. *Respirol Case Rep* 2015; 3:9-12. [\[CrossRef\]](#)
4. McKnight CL, Burns B. Pneumothorax. 2022 May 4. In: *StatPearls* [Internet]. Treasure Island (FL): StatPearls Publishing; 2022.
5. Rossi G, Davoli F, Poletti V, Cavazza A, Lococo F. When the diagnosis of mesothelioma challenges textbooks and guidelines. *J Clin Med* 2021; 10:2434. [\[CrossRef\]](#)
6. Hajji GNM, Cavarson CH, Pinto CAL, Venturi G, Navarro JR, Lima VCC. Malignant pleural mesothelioma: an update. *J Bras Pneumol* 2021; 47. e20210129. doi: 10.36416/1806-3756/e20210129. [\[CrossRef\]](#)
7. Prasad A, Olsen D, Sriram PS. Malignant mesothelioma presenting as a gradually enlarging pneumothorax. *Case Rep Pulmonol* 2013; 2013:374960. [\[CrossRef\]](#)
8. Saleh HZ, Fontaine E, Elsayed H. Malignant pleural mesothelioma presenting with a spontaneous hydropneumothorax: A report of 2 cases. *Rev Port Pneumol* 2012; 18:93-5. [\[CrossRef\]](#)
9. Fukui T, Okubo T, Tanimoto N, Okuma H, Shiina Y, Kohama M, et al. Malignant pleural mesothelioma in a patient with pneumothorax: A cumbersome subtype both clinically and pathologically. *Thorac Cancer* 2021; 12:974-7. [\[CrossRef\]](#)
10. Situnayake RD, Middleton WG. Recurrent pneumothorax and malignant pleural mesothelioma. *Respir Med* 1991; 85:255-6. [\[CrossRef\]](#)
11. Ema T, Funai K, Kawase A, Oiwa H, Iizuka S, Shiiya N. A case of malignant mesothelioma detected hydropneumothorax. *J Thorac Dis* 2018; 10:E281-E284. [\[CrossRef\]](#)