

A Case of Cerebro-pulmonary Mucormycosis Associated with COVID-19

COVID-19 ile İlişkili Serebropulmoner Mukormikoz Olgusu

 Burcu Özdemir¹,  Levent Özdemir¹,  Savaş Gegin¹,  Ömer Serdar Bekdemir²,  Hakan Polat²,  Seda Koç Şahin³

Abstract

Mucormycosis is a fungal infection that is common worldwide and has a high mortality rate after COVID-19 disease. We present here the case of a 55-year-old male who developed cerebral-pulmonary mucormycosis during voriconazole treatment. The patient presented with hemoptysis, and had a history of uncontrolled diabetes due to high-dose and long-term use of corticosteroids for the treatment of COVID-19. He was treated medically with liposomal amphotericin-B and oral posaconazole, and the lung lesion was subsequently removed surgically.

Keywords: COVID 19, cerebro-pulmonary, mucormycosis.

Öz

Mukormikoz COVID-19 hastalığı sonrası tüm dünyada yaygın olarak gözlenen ve yüksek ölüm oranına sahip fungal bir enfeksiyondür. Olgumuz 55 yaşında hemoptizi şikayeti olan, özgeçmişinde COVID 19 nedeni ile yüksek doz ve uzun süreli kortikosteroid kullanımına bağlı kontrolsüz diyabet öyküsü olan ve vorikanazol tedavisi kullanırken gelişen, lipozomal Amfoterisin-B ve oral posakonazol ile medikal tedavi uygulanan, sonrasında cerrahi olarak çıkarılan ilk serebro-pulmoner mukormikoz olgusudur.

Anahtar Kelimeler: COVID-19, serebro-pulmoner, mukormikoz.

¹Department of Chest Diseases, Samsun Education And Research Hospital, Samsun, Türkiye

²Department of Thoracic Surgery, Samsun Education And Research Hospital, Samsun, Türkiye

³Department of Pathology, Samsun Education And Research Hospital, Samsun, Türkiye

¹Samsun Eğitim Ve Araştırma Hastanesi, Göğüs Hastalıkları Anabilim Dalı, Samsun

²Samsun Eğitim Ve Araştırma Hastanesi, Göğüs Cerrahisi Anabilim Dalı, Samsun

³Samsun Eğitim Ve Araştırma Hastanesi, Patoloji Anabilim Dalı, Samsun

Submitted (Başvuru tarihi): 26.02.2023 **Accepted (Kabul tarihi):** 24.04.2023

Correspondence (İletişim): Levent Özdemir, Department of Chest Diseases, Samsun Education And Research Hospital, Samsun, Türkiye

e-mail: levent2408@myynet.com



COVID-19 disease, developing due to the SARS-CoV-2 virus, is highly prevalent worldwide. Although systemic steroid treatment reduces disease severity and mortality, immunologic and other factors lead to an increase in secondary bacterial and fungal infections (1). Of all the COVID-19-associated fungal infections, *Candida* and *Aspergillus* are the most common, although recent studies have identified an increase in COVID-19-associated mucormycosis patients (2). Mucormycosis is a rare, rapidly progressive, invasive opportunistic fungal infection that can be fatal if not diagnosed and treated promptly (3). The two most prominent risk factors for mucormycosis occurrence in COVID-19 patients are diabetes and corticosteroid use. Rhino-orbital-cerebral mucormycosis (ROCM) is the most common clinical form of infection (4). This is the first reported case of cerebral-pulmonary mucormycosis in a patient with uncontrolled diabetes due to long-term, high-dose corticosteroid use for COVID-19 that developed during voriconazole treatment.

CASE

A 55-year-old male patient who was hospitalized for hemoptysis had a history of diabetes and high-dose (250mg/day), long-term (1 month) methylprednisolone use for COVID-19 pneumonia during an intensive care unit (ICU) stay (Figure 1) 6 months ago, a history of tocilizumab (400mg) use for the treatment of cytokine storm, and a history of voriconazole use (5 months) due to an inverted halo image on chest tomography (Figure 2).

Laboratory tests revealed no abnormalities other than elevated levels of glucose (289 – normal range 74–106), HbA1c (11.2 –normal range 4–6) and ferritin (1776 – normal range 22–322). The patient underwent a series of tests, and was found negative for COVID-19 (SARS-CoV-2) in a reverse transcriptase PCR test, negative bronchial lavage ARB negative and aerobic culture normal. PET-Computerized Tomography (CT) revealed a mild hypermetabolic spiculated mass with an air bronchogram in the anterior segment of the right upper lung lobe measuring 37x28 mm in size (SUVmax: 2.1) (Figure 3). Cranial MRI revealed a mass lesion with contrast enhancement in the middle temporal gyrus of the right temporal lobe measuring approximately 9 mm in diameter, suggestive of metastasis, surrounded by vasogenic edema (Figure 4 a-b). The metastatic lesion identified on cranial MRI was not suggestive of metastasis or glial tumor on spectroscopy (Figure 5). White necrotic plaque was observed on bronchoscopy at the entrance to the anterior segment of the right upper lobe. Dense hyphal structures observed on a necrotic surface following biopsy and lavage suggested the presence of a fungal microorganism. The observed hyphal structures were predominantly unbranched, relatively thick hyphae without a septum, branching out at

90-degree angles, consistent with mucormycosis (Figure 6 a-b).

Eye and ear, nose and throat examinations were normal. Liposomal amphotericin-B 5 mg/kg was administered to the patient for 4 weeks, after which an oral posaconazole 1x300 mg loading dose was given followed by a 2x300 mg maintenance dose that continued for 6 months. At the 6th month follow-up the lung lesion was surgically removed as a result of the patient's persistent radiographic image (Figure 7), and the pathology was ascertained to be compatible with mucormycosis. The lesion was seen to regress on the cranial MR. The patient was discharged after surgery with complete recovery.

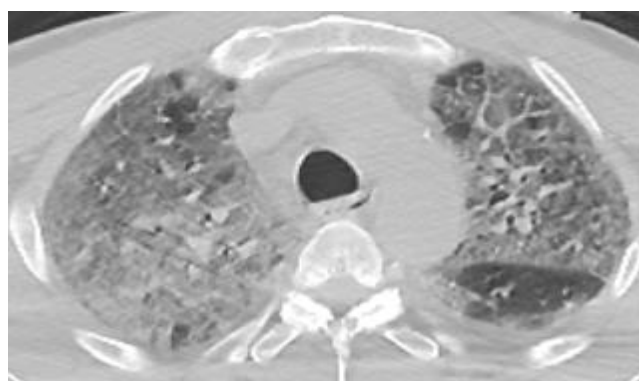


Figure 1: Chest tomography findings associated with COVID-19

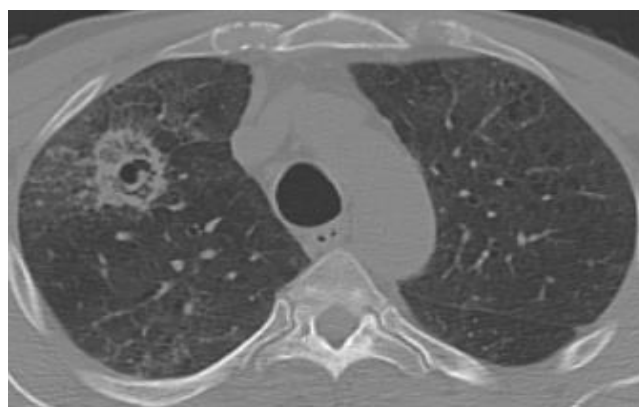


Figure 2: Inverted halo image on chest tomography

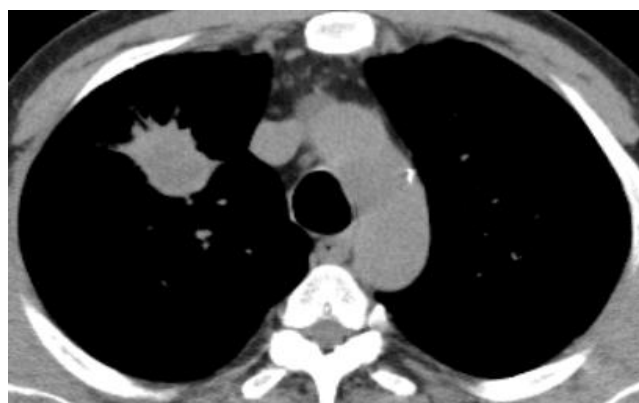

Figure 3: Spiculated mass in the anterior segment of the right upper lobe of the lung measuring 37x28 mm on chest tomography

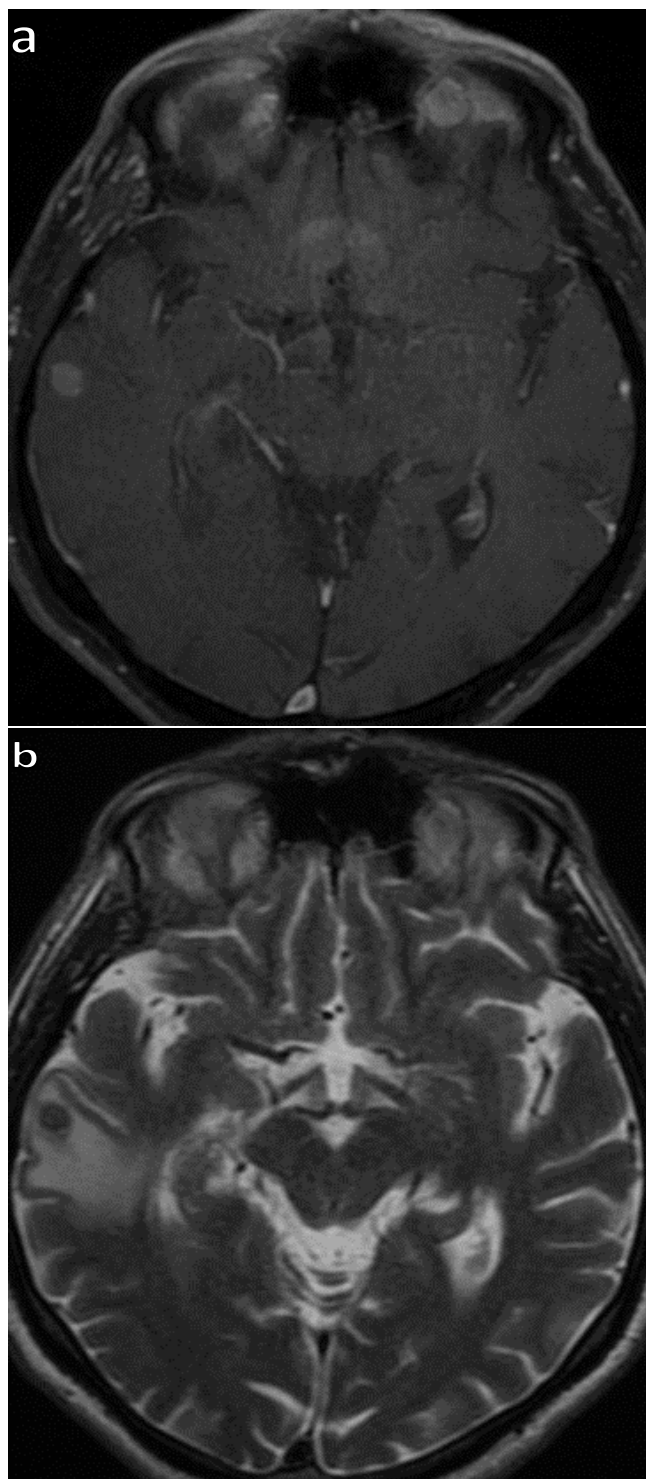


Figure 4a and b: Mass lesion with contrast enhancement in the middle temporal gyrus of the right temporal lobe measuring approximately 9 mm in diameter, suggestive of metastasis, surrounded by vasogenic edema on cranial MRI T1-2 scan

DISCUSSION

The COVID-19 pandemic has led to a global increase in cases of mucormycosis – a rare and opportunistic fungal infection associated with high mortality (5). Mucormycosis is extremely rare in healthy individuals, and the risk factors are fairly well-defined. Uncontrolled diabetes, diabetic ketoacidosis, corticosteroid treatment, organ transplan-

tation, hematopoietic stem cell transplantation, hematologic malignancies, excess iron, trauma and burns, AIDS, malnutrition and voriconazole use for the treatment of *Aspergillus* all increase susceptibility to mucormycosis. In severe COVID-19 patients, the suppression of cellular immunity, high-dose and long-term corticosteroid use during treatment, ICU stays, hypoxia, broad-spectrum antibiotics and the use of such immunomodulators as tocilizumab during cytokine storm are known to increase susceptibility to mucormycosis (6).

A review of case reports and case series on the subjects of COVID-19 and mucormycosis revealed that in 53% of cases, the mucormycosis occurred during COVID-19 infection, while the remaining 47% occurred in the post-COVID-19 period (7). In a meta-analysis evaluating 851 cases of mucormycosis, the underlying risk factors were identified as diabetes in 40% of patients, corticosteroid use in 33%, hematologic malignancy in 32%, organ transplantation in 14% and hematopoietic stem cell transplantation in 11% (6). In cases of COVID-19-associated mucormycosis, diabetes and corticosteroid use were identified as the most common risk factors (8-10).

The RECOVERY study showed that the use of corticosteroids for the suppression of hyperinflammation in COVID-19 patients increased survival and decreased the need for mechanical ventilation (11), and in a later study, an increase in the number of cases of mucormycosis was observed after corticosteroids were included in the standard COVID-19 treatment (12). In COVID-19 patients, diabetes decreases natural killer and T-cell activity and suppresses cellular immunity, while in contrast, corticosteroid use leads to new-onset hyperglycemia, impaired control of pre-existing diabetes, decreased phagocytic activity and impaired neutrophil activity, making patients susceptible to mucormycosis (8).

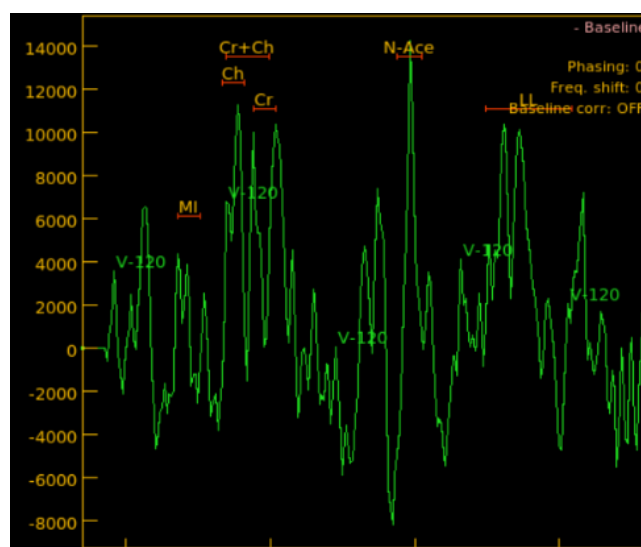


Figure 5: Cranial MRI spectroscopy

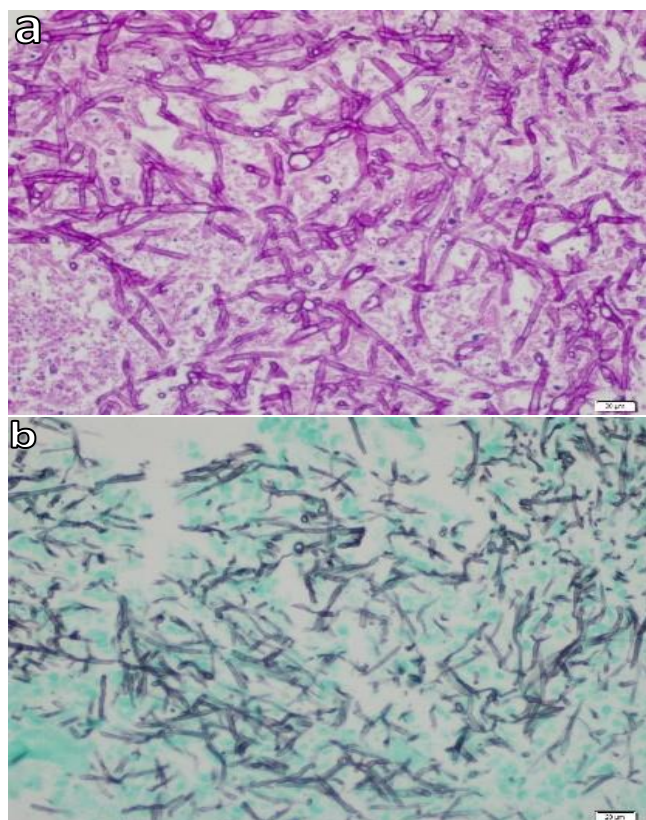


Figure 6a and b: Unbranched thick hyphal structures without a septum in the form of ramifications with 90 degrees, consistent with mucormycosis

In addition to the defined risk factors for mucormycosis in COVID-19 patients, ICU stay, hypoxia, high ferritin, broad-spectrum antibiotics and the use of such immunomodulators as tocilizumab during cytokine storm have all been shown to increase susceptibility to mucormycosis (6). In COVID-19 disease, tissue hypoxia deepens tissue damage while the widely used broad-spectrum antibiotics suppress normal bacterial flora, favoring fungal formation and angioinvasion. A systematic review article revealed hypoxia and broad-spectrum antibiotic use to be common in cases of COVID-19 mucormycosis (7).

Another study reported that high ferritin levels contribute to mucormycosis occurrence in immunocompromised patients (13).

Cytokine storm and ARDS are among the leading causes of multi-organ failure and mortality in COVID-19 patients, and so tocilizumab, an interleukin-6 inhibitor, was used together with corticosteroids to reduce the severity of cytokine storm associated with COVID-19 disease (14). Tocilizumab has been reported to decrease both the need for mechanical ventilation and the mortality rate in severe COVID-19 patients, but to increase the risk of secondary bacterial and fungal infections (15). Our case was also detected in the post-COVID-19 period, with risk factors of high-dose and long-term corticosteroid use and tocilizumab use during COVID-19 infection, high ferritin levels, uncontrolled diabetes and long-term voriconazole use after COVID-19 infection.

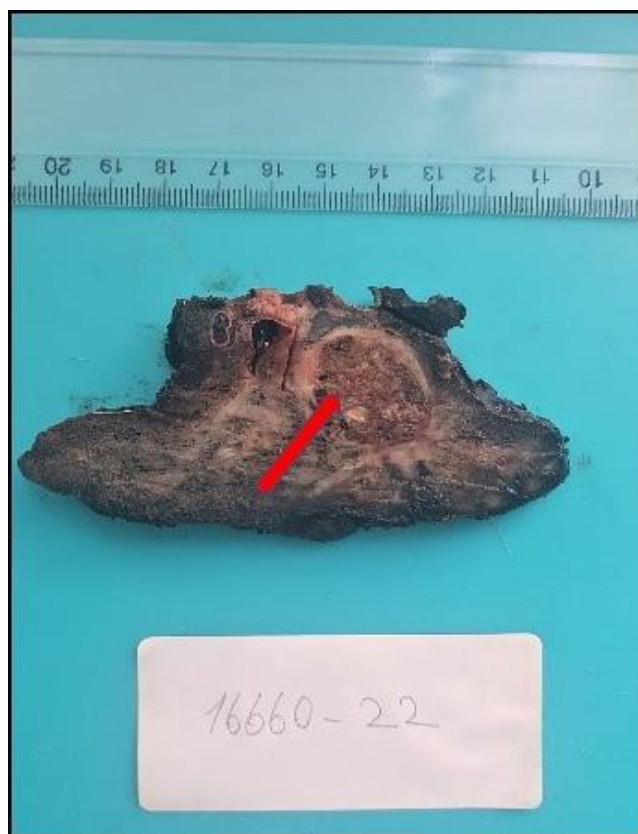

Figure 7: Surgical resection material

The most common form of mucormycosis associated with COVID-19 is the rhino-orbital-cerebral (ROCM) form, followed by the pulmonary and cutaneous, renal, gastrointestinal and disseminated forms. In a meta-analysis of 51 observational studies (n=2312), ROCM was found to be the most common clinical form in 97% of cases (2,242/2,312), followed by the pulmonary form in 2.7% (63/2,312) and others (cutaneous, renal, gastrointestinal, disseminated) (12). No cerebro-pulmonary clinical form was encountered in literature, making our case the first to be studied in this regard.

There are a few data on COVID-19-associated pulmonary mucormycosis (CAPM). Pulmonary mucormycosis is rare and the mortality rate is high. CT findings related to CAPM have yet to be subject to a systematic investigation, but are generally nonspecific and depend on infection severity. The disease generally presents in the beginning as a perivascular ground glass density and in the form of a solitary pulmonary nodule, a lobar consolidation or a cavitory lesion. As findings such as the inverted halo sign may be associated also with invasive aspergillosis and COVID-19 pneumonia, tomography findings alone cannot be used to make a definitive diagnosis (16). In our case, CT findings revealed extensive ground glass densities in the COVID-19 period, an inverted halo in the post-COVID-19 period and a mass thereafter.

Mortality in COVID-19-associated mucormycosis varies from 40–80%, depending on the underlying disease and

location, and so to reduce mortality, rapid diagnosis based on a multidisciplinary approach, control of underlying conditions and risk factors, and early initiation of antifungal treatment with appropriate and early surgery are required (17). Amphotericin B, posaconazole and isavuconazole are recommended for antifungal treatment by the European Conference on Infections in Leukemia (ECIL) (18). In our case, we initially controlled the underlying diabetes by regulating the patient's blood glucose levels with insulin while using liposomal amphotericin-B and oral posaconazole to maintain therapy. At the 6th month follow-up, when the patient's blood glucose and clinical appearance were stable and the patient's radiological appearance persisted, we surgically removed the lung lesion.

In conclusion, mucormycosis, which has a high mortality rate, should be kept in mind in patients with severe COVID-19 and risk factors.

CONFLICTS OF INTEREST

None declared.

AUTHOR CONTRIBUTIONS

Concept - B.O., L.Ö., S.G., Ö.S.B., H.P., S.K.Ş.; Planning and Design - B.O., L.Ö., S.G., Ö.S.B., H.P., S.K.Ş.; Supervision - B.O., L.Ö., S.G., Ö.S.B., H.P., S.K.Ş.; Funding - B.O., L.Ö.; Materials - B.O., L.Ö.; Data Collection and/or Processing - B.O., L.Ö.; Analysis and/or Interpretation - B.O., L.Ö.; Literature Review - B.O., L.Ö.; Writing - B.O., L.Ö.; Critical Review - B.O., L.Ö.

REFERENCES

1. Hoenigl M, Seidel D, Carvalho A, Rudramurthy SM, Arastehfar A, Gangneux JP, et al. The emergence of COVID-19 associated mucormycosis: a review of cases from 18 countries. *Lancet Microbe* 2022; 3:e543-e552. [\[CrossRef\]](#)
2. Krishna V, Bansal N, Morjaria J, Kaul S. COVID-19-Associated pulmonary mucormycosis. *J Fungi (Basel)* 2022; 8:711. [\[CrossRef\]](#)
3. Akyıldız Ö. Rinoserebral mukormikozlu bir olgu. *KSU Med J* 2020; 15:56-9. [\[CrossRef\]](#)
4. Balushi AA, Ajmi AA, Sinani QA, Menon V, Berieki ZA, Shezawi AA, et al. COVID-19-associated mucormycosis: an opportunistic fungal infection. a case series and review. *Int J Infect Dis* 2022; 121: 203-10. [\[CrossRef\]](#)
5. Garg D, Muthu V, Sehgal IS, Ramachandran R, Kaur H, Bhalla A, et al. Coronavirus disease (Covid-19) associated mucormycosis (CAM): case report and systematic review of literature. *Mycopathologia* 2021; 186:289-98. [\[CrossRef\]](#)
6. Jeong W, Keighley C, Wolfe R, Lee WL, Slavin MA, Kong DCM, et al. The epidemiology and clinical manifestations of mucormycosis: a systematic review and meta-analysis of case reports. *Clin Microbiol Infect* 2019; 25:26-34. [\[CrossRef\]](#)
7. Dilek A, Ozaras R, Ozkaya S, Sunbul M, Sen EI, Leblebiçioğlu H. COVID-19-associated mucormycosis: case report and systematic review. *Travel Med Infect Dis* 2021; 44: 102148. [\[CrossRef\]](#)
8. Gupta R, Kesavadev J, Krishnan G, Agarwal S, Saboo B, Shah M, et al. COVID-19 associated mucormycosis: a descriptive multisite study from India. *Diabetes Metab Syndr* 2021; 15:102322. [\[CrossRef\]](#)
9. John TM, Jacob CN, Kontoyiannis DP. When uncontrolled diabetes mellitus and severe COVID-19 converge: The perfect storm for mucormycosis. *J Fungi (Basel)* 2021; 7:298. [\[CrossRef\]](#)
10. Kumar M, Sarma DK, Shubham S, Kumawat M, Verma V, Singh B, et al. Mucormycosis in COVID-19 pandemic: Risk factors and linkages. *Curr Res Microb Sci* 2021; 2:100057. [\[CrossRef\]](#)
11. RECOVERY Collaborative Group; Horby P, Lim WS, Emberson JR, Mafham M, Bell JL, Linsell L, et al. Dexamethasone in Hospitalized Patients with Covid-19. *N Engl J Med* 2021; 384:693-704. [\[CrossRef\]](#)
12. Watanabe A, So M, Mitaka H, Ishisaka Y, Takagi H, Inokuchi R, et al. Clinical features and mortality of COVID-19-associated mucormycosis: a systematic review and meta-analysis. *Mycopathologia* 2022; 187:271-89. [\[CrossRef\]](#)
13. Pandit AK, Tangri P, Misra S, Srivastava MVP, Bhatnagar S, Thakar A, et al. Mucormycosis in COVID-19 patients: a case-control study. *Microorganisms* 2022; 10:1209. [\[CrossRef\]](#)
14. Abdoli A, Falahi S, Kenarkoobi A. COVID-19-associated opportunistic infections: a snapshot on the current reports. *Clin Exp Med* 2022; 22:327-46. [\[CrossRef\]](#)
15. Aziz M, Haghbin H, Abu Sitta E, Nawras Y, Fatima R, Sharma S, et al. Efficacy of tocilizumab in COVID-19: A systematic review and meta-analysis. *J Med Virol* 2021; 93:1620-30. [\[CrossRef\]](#)
16. Khan N, Gutierrez CG, Martinez DV, Proud KC. A case report of COVID-19 associated pulmonary mucormycosis. *Arch Clin Cases* 2021; 7:46-51. [\[CrossRef\]](#)
17. Demiroğlu YZ, Ödemiş İ, Oruç E, Özer F, Ulaş B, Canpolat ET ve ark. COVID-19 enfeksiyonu sonrası gelişen iki rino-orbito-serebral mukormikoz olgusu [Two case of rhino-orbito-cerebral mucormycosis developed after COVID-19 infection]. *Mikrobiyol Bul* 2021; 55:673-82. [\[CrossRef\]](#)
18. Tissot F, Agrawal S, Pagano L, Petrikos G, Groll AH, Skiada A, et al. ECIL-6 guidelines for the treatment of invasive candidiasis, aspergillosis and mucormycosis in leukemia and hematopoietic stem cell transplant patients. *Haematologica* 2017; 102:433-44. [\[CrossRef\]](#)