








A Case Report of Tuberculous Lymphadenitis and Tuberculous Pleural Effusion Accompanied by Splenic Tuberculosis

Splenik Tüberkülozun Eşlik Ettiği Tüberküloz Lenfadenit ve Tüberküloz Plörezi: Bir Olgu Sunumu

 Gamze Kayasuyu¹,  Ceyda Anar¹,  Süheyla Uygur¹,  Betül Doğan¹,  Muzaffer Onur Turan¹,  Bunyamin Sertogullarından¹,  Ebru Cakir²

Abstract

Spleen tuberculosis has occasionally been described in literature, mostly in immunocompromised patients with various risk factors. The presence of spleen involvement and splenomegaly makes this type of Mycobacterium tuberculosis infection difficult to diagnose. A 56-year-old woman who had mediastinal and abdominal lymphadenopathies with splenomegaly and was investigated with a pre-diagnosis of lymphoma, and with no significant medical history, presented with complaints of fever and malaise. Here, we present a case of tuberculous lymphadenitis and pleuritis accompanied by splenic tuberculosis with the appearance of granulomatous inflammation on pleural and spleen biopsy. Tuberculosis should be kept in mind as a differential diagnosis in diseases accompanied by a fever of unknown origin and lymphadenopathy.

Key words: Tuberculosis, lymphadenit, spleen, pleural effusion.

Öz

Dalak tüberkülozu, literatürde zaman zaman, çoğunlukla çeşitli risk faktörleri olan bağışıklığı baskılanmış bireylerde tanımlanmıştır. Dalak tutulumu ve splenomegalinin olması, bu tür Mycobacterium tuberculosis enfeksiyonunun teşhis edilmesini zorlaştırır. Splenomegali ile birlikte mediastinal ve abdominal lenfadenopatileri olan ve lenfoma ön tanısı ile araştırılan, önemli bir tıbbi öyküsü olmayan 56 yaşında kadın hasta ateş, halsizlik yakınması ile başvurdu. Alınan plevral ve dalak biyopsisinde granülatöz inflamasyonun ortaya çıktı. Burada, dalak tüberkülozunun eşlik ettiği tüberküloz lenfadenit ve plörit olgusunu sunuyoruz. Tüberküloz, nedeni bilinmeyen ateş ve lenfadenopatilerin eşlik ettiği hastalıklarda ayırıcı tanı olarak hala akılda tutulmalıdır.

Anahtar Sözcükler: Tüberküloz, lenfadenit, dalak, plevral effüzyon.

¹Department of Pulmonology, İzmir Katip Çelebi University Atatürk Training and Research Hospital, İzmir, Türkiye

²Department of Patology, İzmir Katip Çelebi University Atatürk Training and Research Hospital, İzmir, Türkiye

¹İzmir Katip Çelebi Üniversitesi Atatürk Eğitim ve Araştırma Hastanesi, Göğüs Hastalıkları Bölümü, İzmir

²İzmir Katip Çelebi Üniversitesi Atatürk Eğitim ve Araştırma Hastanesi, Patoloji Bölümü, İzmir

Submitted (Başvuru tarihi): 16.01.2022 **Accepted (Kabul tarihi):** 15.04.2022

Correspondence (İletişim): Ceyda Anar, Department of Pulmonology, İzmir Katip Çelebi University Atatürk Training and Research Hospital, İzmir, Türkiye

e-mail: drceydaanar@hotmail.com



Despite the medical advances in the diagnosis and treatment of infectious diseases, tuberculosis is still a health issue of concern in developing countries. In countries where cases of tuberculosis are common, all forms of the disease may frequently be detected, while in developed countries extrapulmonary cases represent a very small proportion of the total. Although the spleen is the third most affected organ in miliary or disseminated tuberculosis after the lungs and liver, isolated splenic tuberculosis is a rare manifestation of the disease (1). Symptoms of splenic tuberculosis are often nonspecific and misleading, and even asymptomatic cases can often complain of fever, stomachache and weight loss (2). The early diagnosis of splenic tuberculosis is not possible due to the unclear symptomatology of the disease, while *Mycobacterium tuberculosis* infections can be difficult to diagnose due to bacterial sequestrations in the spleen. Carcinoma, metastatic tumor, lymphoma, hemangioma and abscess of the spleen are among the differential diagnoses, and false diagnoses are also likely in high rates if there is no history of tuberculosis of other organs.

We present here the case of a 56-year-old woman with no significant medical history who had mediastinal and abdominal lymphadenopathies together with splenomegaly, and who had been investigated with a preliminary diagnosis of lymphoma. We present a case of pleural effusion with pleural and splenic biopsy results of granulomatous inflammation leading to splenic tuberculosis, with accompanying tuberculous lymphadenitis and pleurisy. Tuberculosis must be kept in mind as a differential diagnosis when presented with fever of unknown origin and diseases accompanied by lymphadenopathies.

CASE

A 56-year-old woman presented with a 4-month history of excessive sweating and weight loss. A thoracic-abdominal computed tomography (CT) revealed many lymph nodes with a short axis of 3 cm in the mediastinum and abdominal lymphadenopathies, together with splenomegaly. Considering the preliminary diagnosis of lymphoma, an inguinal lymph node excisional biopsy was carried out (Figure 1a and b), and the histopathological result of the biopsy revealed noncaseating granulomatous lymphadenitis. The patient was thus referred to our chest diseases unit with preliminary diagnoses of sarcoidosis and tuberculosis. A Mantoux test/tuberculin skin test (PPD skin test) was performed on the patient, whose histopathological diagnosis was granulomatous lymphadenitis, for the differential diagnosis of tuberculosis and sarcoido-

sis. A tuberculin skin test showed no induration, and EBUS was planned for culture material from the mediastinal lymph nodes. The patient did not attend the clinic at this time due to the pandemic, and applied to the chest diseases clinic due to shortness of breath approximately 2 months later. Pleural effusion had formed in the left lung approximately from the 2nd anterior rib on the posterior in an anterior Chest x-ray (Figure 2). The patient was hospitalized and a physical examination revealed a moderate and weak general condition. Multiple lymphadenopathies were detected bilaterally in the cervical, inguinal and axillary areas that were mobile, firm and painless, and with no signs of inflammation or induration on the skin. Tenderness and Traube's Space were evaluated as closed. Laboratory examinations revealed a hemoglobin level of 10.6 g/dl, hematocrit of 34%, leukocytes of $6590/\text{mm}^3$ and platelets of $336000/\text{mm}^3$. The erythrocyte sedimentation rate was determined as $12 \text{ mm}\cdot\text{h}^{-1}$. The biochemical parameters values were BUN of 13 mg/dl, Creatinine of 0.6 mg/dl, Na of 137 meq/L, K of 5.0 meq/L, Ca of 7.5 mg/L, Albumin of 2 g/dl, AST of 26 IU/L, ALT of 13 IU/L and LDH of 278 IU/L. The patient underwent thoracentesis, and the pleural fluid was an exudative effusion, the result of an acid-fast bacilli (ARB) test of which was negative. The adenosine deaminase (ADA) levels of the pleural effusion were 22 IU/L. A closed needle biopsy was performed on the patient. While there were many granuloma structures in lymphoplasmacytic inflammatory cell infiltrations, there was no observation of necrosis in the granuloma structures in the pathology results of the pleural biopsy. Schaumann bodies were observed in some of the giant cells, the presence of which indicated possible sarcoidosis as a clinical pre-diagnosis. Since these findings were not entity-specific in terms of causes of granulomatous inflammation (Figure 3), the case was evaluated from a clinical, microbiological, and serological point of view. Further examinations revealed noticeable symptoms of dyspnea in the foreground, and an evacuating thoracentesis was performed. Due to repetitive pleural fluid collections, a pleura can was attached. While lymphoma was ruled out by hematology, PET/CT revealed multiple low-to-moderate hypermetabolic lymph nodes with conglomeration and chain-like extension in the cervical-thoracic region, abdomen and pelvis. The spleen was also significantly increased in size, and in addition to a significant diffuse F-18 FDG uptake in the parenchyma of the spleen, a pathological F-18 FDG uptake compatible with the capsular millimetric hypodense area was detected at the level

of the inferior end of Segment 6 in the liver (Figure 4a and b). A spleen biopsy was performed on the patient, and a biopsy sample taken from the cervical lymph node was sent to the microbiology department for tuberculosis culture. There was no ARB identified in a direct examination of the lymph node. While waiting for the culture result, caseifying granulomas were observed in the spleen biopsy (Figure 5). The patient was started on antituberculous treatment with a diagnosis of splenic tuberculosis, tuberculous lymphadenitis and pleural tuberculosis. No growth was detected in the lymph node tuberculosis culture of the patient who was now in the 2nd month of treatment.

DISCUSSION

Tuberculosis is a multisystemic disease, the most common form of which is pulmonary tuberculosis. Extrapulmonary disease accounts for approximately 15–20% of all cases of tuberculosis (3). Splenic tuberculosis was first described in literature by Coley in 1846, but this unusual form is rarely reported as the primary involvement in literature. HIV-infected or immunocompromised patients are reported to be at high risk of splenic tuberculosis, and HIV infection has been found to underlie many reported cases of splenic tuberculosis abscesses (4). For this reason, spleen involvement was thought to occur only in immunocompromised individuals, although there have been a few case reports of splenic tuberculosis in immunocompetent patients (5). Sharma et al. (6) and Gupta et al. (7) reported rare cases of splenic abscess in an immunocompromised and immunocompetent patient. The case presented here is extremely rare. The patient had no history of tuberculosis, and no immunosuppressive conditions have been shown to cause such infections. The splenic involvement of tuberculosis is more common in men, and usually in the 19–53 years age group (8). In most cases, a fever of unknown origin is the typical presentation (9). The most common symptoms presented by patients are fever (82.3%), fatigue, weight loss (44.12%), and splenomegaly (13.2–100%) (10). There are no specific symptoms for a diagnosis of splenic tuberculosis. Tuberculosis of the spleen is very rare and difficult to diagnose in an immunocompetent individual. The main complaints in our case – a 56-year-old female – were fever, malaise, anorexia, abdominal pain and shortness of breath. Most cases present as a splenic abscess, but the presence of ascites (11) together with a splenic mass (12) has also been reported. Splenic TB may be associated with the presence of abdominal and medi-

astinal lymphadenopathy, psoas abscess and vertebral tuberculosis (13). In our case, pleural effusion accompanied the splenic tuberculosis, along with abdominal and mediastinal lymphadenopathies. Isolated cases of splenic tuberculosis have been reported in the literature (14–16). Despite their reliability, common methods such as Ultrasound and CT offer only limited success in distinguishing lesions from primary or metastatic tumors of the spleen. The rate of misdiagnosis is high if there is no history of tuberculosis in other organs. Although the presence of splenomegaly with abdominal lymph nodes in our case initially suggested lymphoma as a diagnosis, the granulomatous result of the biopsy taken from both the lymph node and spleen ruled this condition out. Although imaging methods are helpful in the diagnosis of tuberculosis, whether pulmonary or extrapulmonary, a definitive diagnosis is made histopathologically and/or microbiologically. Abdominal ultrasound is the first imaging modality of choice, as it is cost-effective and can aid in the characterization of the lesion. Lesions of the spleen typically present as multiple hypoechoic lesions that may be tuberculomas or abscesses. CT is the next best modality for the identification of lesions of the spleen, and also for the detection of concurrent lesions in the chest and other parts of the abdomen. Many patterns such as nodular, pseudotumor and oval appearances, have been identified in splenic tuberculosis on CT scans, and five types of splenic tuberculosis can be identified based on pathomorphological manifestations, including miliary tuberculosis, nodular tuberculosis, tuberculous splenic abscess, calcific tuberculosis and mixed type tuberculosis (17). Diagnosis is confirmed by a histopathological examination of the lesions. Fine-needle aspiration biopsy, laparoscopic or imaging-guided needle biopsy (CNB), or splenectomy specimens have been examined for diagnostic confirmation in different reports (18). In the abdominal USI performed in our case, the size of the spleen was measured at approximately 28 mm, and the parenchyma structure was observed as normal. There were, however, lymph nodes present in the abdomen. The patient, who was thought to have mostly lymphoma based on her splenomegaly, was found to have splenomegaly with abdominal lymphopathies in her abdominal CT. Imaging methods cannot contribute to a direct diagnosis, and so a histopathological diagnosis is required. In our case, an FDG uptake was also present in the spleen and mediastinal, and abdominal lymphadenopathies on PET-CT, however, these do not indicate a specific disease, and can only guide clinicians to the appropriate biopsy site.

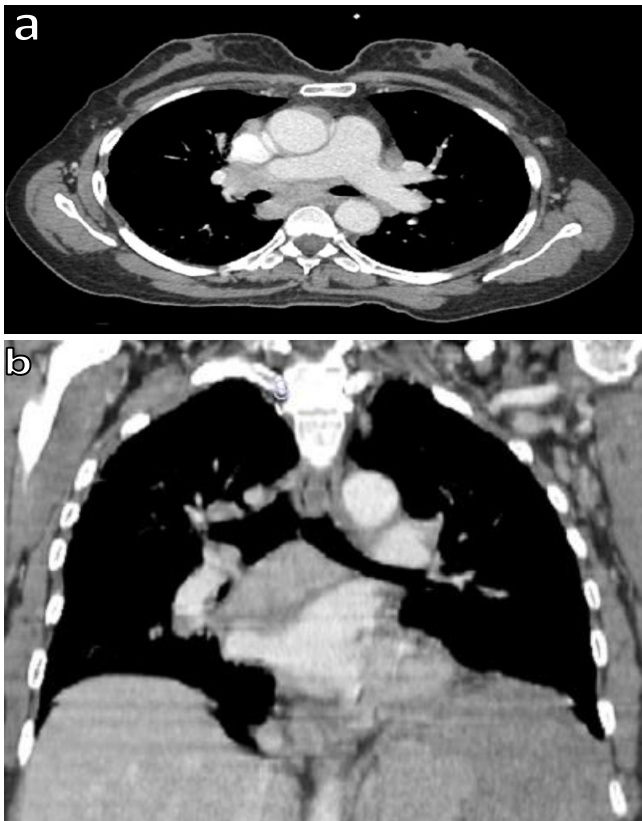


Figure 1a and b: Many lymph nodes with a short axis of 3 cm in the mediastinum

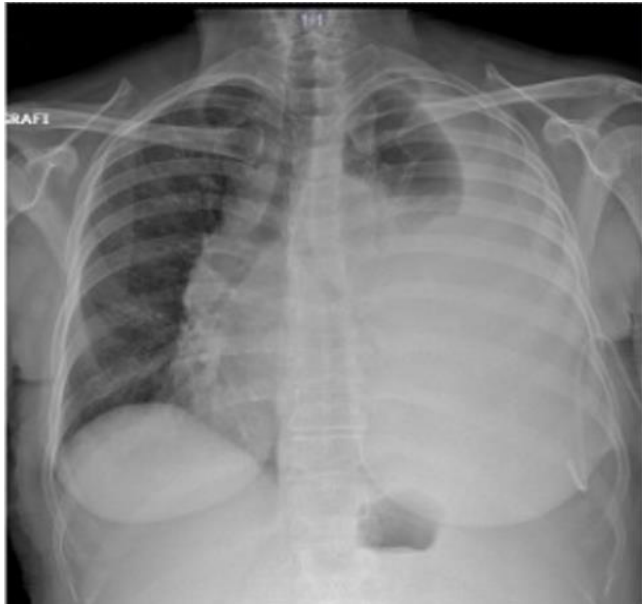


Figure 2: Pleural effusion on the left lung

One study in literature reported a case of isolated spleen TB in which a fever of unknown origin was examined, and was not detected in any other morphological image examination other than FDG-PET (19). In our case, biopsy samples taken from the lymph nodes, pleura and spleen were reported as granulomatous. Histopathologically, caseification was also observed in the spleen biopsy.

Since lymphoma was considered as a preliminary diagnosis, no culture was sent from the biopsies, and the presence of splenomegaly made it difficult for us to come to a diagnosis. A sample, however, was sent from the cervical lymph node for culture. As with pulmonary tuberculosis, antituberculous therapy is the primary treatment approach to spleen tuberculosis. Treatment regimens, which typically last six to nine months, are considered satisfactory, and a splenectomy can be applied to patients who do not respond to medical treatment or in the presence of an abscess in the spleen (17).

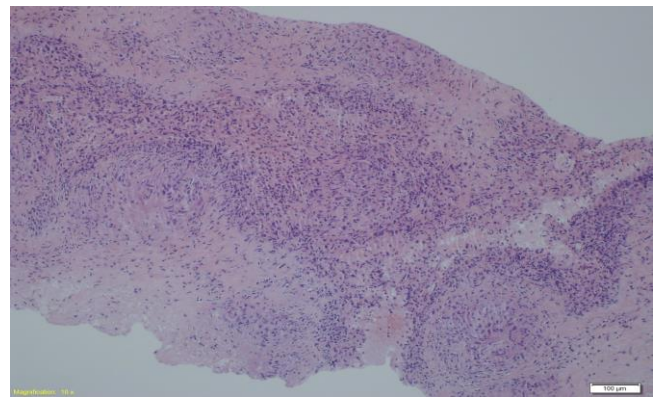


Figure 3: Granulomatous inflammation on pleural biopsy (H&E, X100)

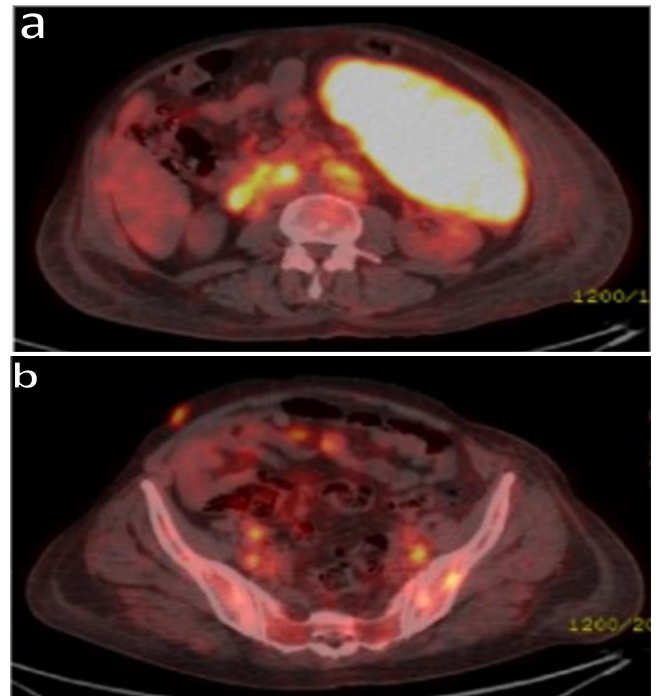


Figure 4a and b: PET/CT revealed multiple low-to-moderate hypermetabolic lymph nodes with conglomeration and chain-like extension in the cervical, thoracic region, abdomen and pelvis, and a significantly increased spleen size was detected in addition to significant diffuse F-18 FDG uptake in the parenchyma of the spleen

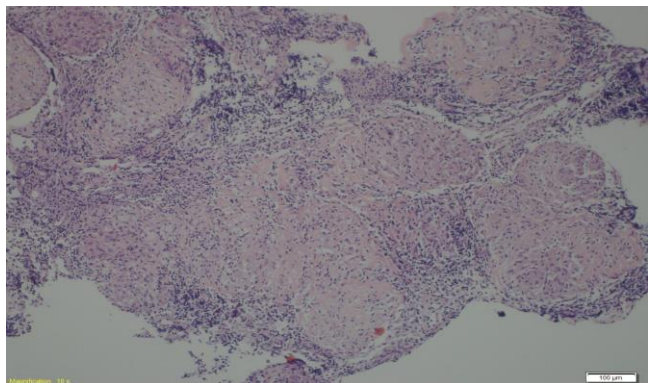


Figure 5: Caseative necrotizing granulomatous inflammation of the spleen parenchyma (H&E, X100)

In conclusion, although fever of unknown origin, weight loss, night sweats, and multiple lymphadenomegaly and lymphoma are considered in the differential diagnosis of splenomegaly, it should be kept in mind that there are unusual manifestations of tuberculosis that can mimic any disease, and that may create difficulties in the differential diagnosis. It is necessary to emphasize here that if clinical and radiological findings suggest tuberculosis, it will be useful to perform microbiological examinations to determine the causative agent from materials taken from the lymph node, pleura or any organ other than the lung.

CONFLICTS OF INTEREST

None declared.

AUTHOR CONTRIBUTIONS

Concept - G.K., C.A., S.U., B.D., M.O.T., B.S., E.C.; Planning and Design - G.K., C.A., S.U., B.D., M.O.T., B.S., E.C.; Supervision - G.K., C.A., S.U., B.D., M.O.T., B.S., E.C.; Funding - G.K., C.A., B.D., M.O.T.; Materials - G.K., C.A., S.U.; Data Collection and/or Processing - G.K., C.A., S.U., B.D., E.C.; Analysis and/or Interpretation - C.A., S.U., B.S., E.C.; Literature Review - C.A., S.U., B.S., E.C.; Writing - C.A., S.U., B.S., E.C., B.D.; Critical Review - C.A., S.U., G.K., E.C.

YAZAR KATKILARI

Fikir - G.K., C.A., S.U., B.D., M.O.T., B.S., E.C.; Tasarım ve Dizayn - G.K., C.A., S.U., B.D., M.O.T., B.S., E.C.; Denetleme - G.K., C.A., S.U., B.D., M.O.T., B.S., E.C.; Kaynaklar - G.K., C.A., B.D., M.O.T.; Malzemeler - G.K., C.A., S.U.; Veri Toplama ve/veya İşleme - G.K., C.A., S.U., B.D., E.C.; Analiz ve/veya Yorum - C.A., S.U., B.S., E.C.; Literatür Taraması - C.A., S.U., B.S., E.C.; Yazıyı Yazan - C.A., S.U., B.S., E.C., B.D.; Eleştirel İnceleme - C.A., S.U., G.K., E.C.

REFERENCES

1. Nayyar V, Ramakrishna B, Mathew G, Williams RR, Khanduri P. Response to antituberculous chemotherapy after splenectomy. *J Intern Med* 1993; 233:81-3. [\[CrossRef\]](#)
2. Udgaonkar U, Kulkarni S, Shah S, Bhav S. Asymptomatic, isolated tubercular splenic abscess, in an immunocompetent person. *Indian J Med Microbiol* 2010; 28:172-3. [\[CrossRef\]](#)
3. Hamzah R, Rohana AG, Anwar SA, Ong TZ, Hamazaini AH, Zulkarnaen AN. Splenic tuberculosis presenting as pyrexia of unknown origin. *Med J Malaysia* 2007; 62:70-1.
4. Pramesh CS, Tamhankar AP, Rege SA, Shah SR. Splenic tuberculosis and HIV-1 infection. *Lancet* 2002; 359:353. [\[CrossRef\]](#)
5. Chandra S, Srivastava DN, Gandhi D. Splenic tuberculosis: an unusual sonographic presentation. *Int J Clin Pract* 1999; 53:318-9.
6. Sharma S, Dey AB, Agarwal N, Nagarkar KM, Gujral S. Tuberculosis: a rare cause of splenic abscess. *J Assoc Physicians India* 1999; 47:740-1.
7. Gupta A, Hunjan PS, Jain SK, Kaza RC, Kumar V. Tubercular splenic abscess in an immunocompetent patient: a rare entity. *Southeast Asian J Trop Med Public Health* 2006; 37:1196-8.
8. Pottakkat B, Kumar A, Rastogi A, Krishnani N, Kapoor VK, Saxena R. Tuberculosis of the spleen as a cause of fever of unknown origin and splenomegaly. *Gut Liver* 2010; 4:94-7. [\[CrossRef\]](#)
9. Ho PL, Chim CS, Yuen KY. Isolated splenic tuberculosis presenting with pyrexia of unknown origin. *Scand J Infect Dis* 2000; 32:700-1. [\[CrossRef\]](#)
10. Rhazal F, Lahlou MK, Benamer S, Daghri JM, Essadel E, Mohammadine E, et al. Splenomegaly and splenic pseudotumor due to tuberculosis: six new cases. *Ann Chir* 2004; 129:410-4. [\[CrossRef\]](#)
11. Lim J, Yu JS, Hong SW, Chung JJ, Kim JH, Kim KW. A case of mass-forming splenic tuberculosis: MRI findings with emphasis of diffusion-weighted imaging characteristics. *J Korean Med Sci* 2011; 26:457-60. [\[CrossRef\]](#)
12. Lonkar Y, Parikh S, Kumar S, Diwan S, Bhake A. Splenic tuberculosis presenting as ascites in immunocompetant patient. *Ann Med Health Sci Res* 2013; 3:116-8. [\[CrossRef\]](#)
13. Sharma SK, Smith-Rohrberg D, Tahir M, Mohan A, Seith A. Radiological manifestations of splenic tuberculosis: a 23-patient case series from India. *Indian J Med Res* 2007; 125:669-78.

14. Wangai F, Achieng L, Otieno G, Njoroge J, Wambaire T, Rajab J. Isolated splenic tuberculosis with subsequent paradoxical deterioration: a case report. *BMC Res Notes* 2017; 10:162. [\[CrossRef\]](#)
15. Gupta P, Dhaka N, Rohilla M. Isolated splenic tuberculosis presenting as an unusual splenic mass . *Int J Mycobacteriol* 2018; 7:397-8. [\[CrossRef\]](#)
16. Dhibar DP, Chhabria BA, Gupta N, Varma SC. Isolated splenic cold abscesses in an immunocompetent individual. *Oman Med J* 2018; 33:352-5. [\[CrossRef\]](#)
17. Zhan F, Wang CJ, Lin JZ, Zhong PJ, Qiu WZ, Lin HH, et al. Isolated splenic tuberculosis: a case report. *World J Gastrointest Pathophysiol* 2010; 1: 109-11. [\[CrossRef\]](#)
18. Imani Fooladi AA, Hosseini MJ, Azizi T. Splenic tuberculosis: a case report. *Int J Infect Dis* 2009; 13:e273-5. [\[CrossRef\]](#)
19. Rao A, Mallarajapatna G, Godehal S, Shivakumar S. Isolated splenic tuberculosis detected only on FDG-PET. *BJR Case Rep* 2017; 3:20150238. [\[CrossRef\]](#)