

Malignant Peripheral Nerve Sheath Tumor Related to Diffuse Neurofibroma of Chest Wall

Göğüs Duvarının Diffüz Nörofibroma ile İlişkili Malign Periferik Sinir Kılıfı Tümörü

Muharrem Çakmak¹, İsmail Demirel²

Abstract

Malignant peripheral nerve sheath tumors account for 5–10% of all soft tissue tumors. These tumors are closely related with Neurofibromatosis type 1. Although many such tumors have been reported in different locations, malignant peripheral nerve sheath tumors arising from diffuse neurofibroma located in the chest wall are extremely rare. In the present study we report on a malignant peripheral nerve sheath tumor arising out of a diffuse neurofibroma of the chest wall.

Key words: Chest wall, Mass, Malignant peripheral nerve sheath tumor.

Özet

Malign periferik sinir kılıfı tümörü yumuşak doku tümörlerinin %5-10'unu oluşturur. Bu tümörler Nörofibromatozis tip 1 ile yakından ilişkilidir. Farklı lokalizasyonlarda birçok olgu bildirilmiş olsa da göğüs duvarı yerleşimli diffüz nörofibroma zemininde gelişen malign periferik sinir kılıfı tümörü son derece nadirdir. Bu çalışmada, göğüs duvarı yerleşimli diffüz nörofibroma zemininde gelişen malign periferik sinir kılıfı tümörünü sunuyoruz.

Anahtar Sözcükler: Göğüs duvarı, Kitle, Malign periferik sinir kılıfı tümörü.

¹Department of Thoracic Surgery, Fırat University Faculty of Medicine, Elazığ, Turkey

²Department of Anesthesiology and Reanimation, Fırat University Faculty of Medicine, Elazığ, Turkey

¹Fırat Üniversitesi Tıp Fakültesi, Göğüs Cerrahisi Anabilim Dalı, Elazığ

²Fırat Üniversitesi Tıp Fakültesi, Anesteziyoloji ve Reanimasyon Anabilim Dalı, Elazığ

Submitted (Başvuru tarihi): 03.07.2020 Accepted (Kabul tarihi): 14.10.2020

Correspondence (İletişim): Muharrem Çakmak, Department of Thoracic Surgery, Fırat University Faculty of Medicine, Elazığ, Turkey

e-mail: drcakmak@gmail.com



Chest wall tumors are classified as either primary or secondary. While primary tumors originate from soft tissue, bone, cartilage, vessels and nerves, secondary tumors are metastatic. Some 60–70% of primary tumors are malignant (1). Malignant peripheral nerve sheath tumors (MPNST) account for 5–10% of all soft tissue tumors, and are closely associated with neurofibromatosis type 1 (NF-1). Although many such cases have been reported in different locations, MPNST tumors related to diffuse neurofibroma located in the chest wall are extremely rare (2–4).

The symptoms are nonspecific, but the most common complaint is a painless growing mass. In tumors including bone-derived factors, accompanying pain due to periosteal injury is common, and is a predictor of poor prognosis (1).

Diagnoses are made based on anamnesis, physical examination, radiological evaluation and biopsy. Fine needle aspiration biopsy, incisional biopsy or excisional biopsy can be performed for a definitive diagnosis. The treatment is surgical, with complete tumor resection with negative margins in tumors smaller than 2cm having been shown to be important for a successful cure (2).

In the present study we report on a rare case with low grade MPNST arising from diffuse neurofibroma of the chest wall. Such tumors, which are extremely rare, should not be ignored in differential diagnosis.

CASE

A 56-year-old female patient was admitted to our clinic with a complaint of a painful, enlarging mass on the chest wall, having been operated three times in the last 6 years due to chest wall masses.

During the subsequent examination, a lesion measuring approximately 8x7cm in size and painful to palpation, as well as incision scars from previous operations, were detected in the left posterolateral hemithorax (Figure 1). There was no significant pathology on chest X-ray.

A thoracic MRI was performed to understand the extent of the lesion on the chest wall. MR imaging of the thorax revealed a mass lesion of 11x7 cm in axial and 11x6 cm in coronal, extending from the infraspinatus and teres minor muscles to the subscapular and latissimus dorsi muscles in the left inferior hemithorax (Elastofibroma dorsi ? Rhabdomyosarcoma ? Metastatic involvement ?) (Figure 2).

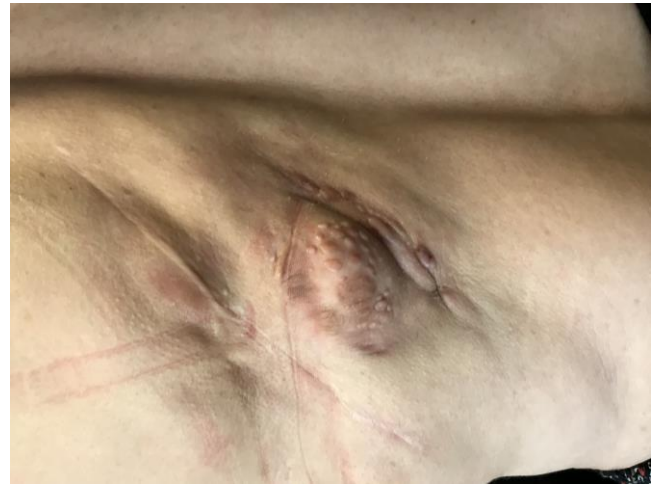

Figure 1: Mass appearance in the patient

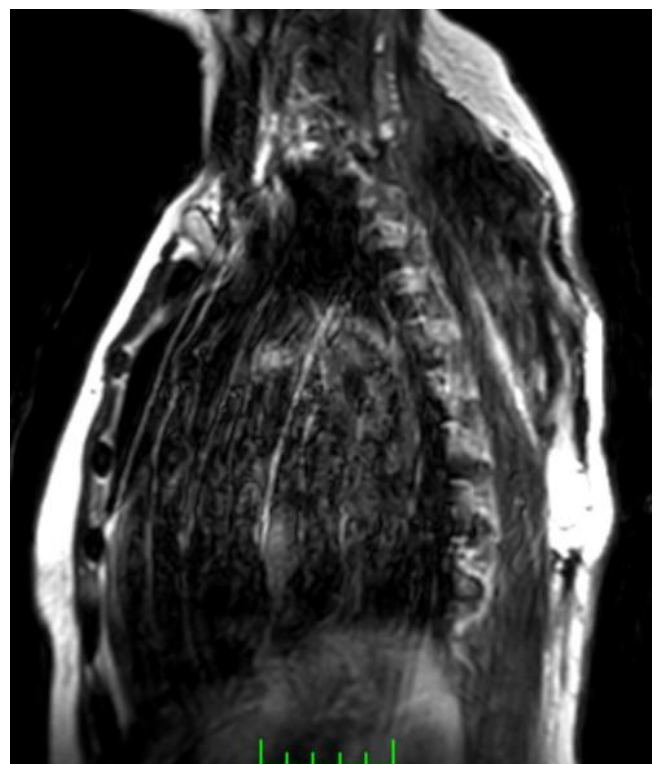


Figure 2: MRI image of the patient (sagittal)

The patient's medical history was unremarkable, other than three separate operations in the same region. Her family history was unremarkable and laboratory tests were normal. An operation was planned for the patient, whose previous pathology results were evaluated as fibrolipoma. The mass was determined macroscopically before the operation. The excision was made 4 cm distant from the mass, and the mass and the surrounding abnormal tissues were excised up to the ribs (Figure 3). The removed mass area was repaired with a skin graft from the thigh region (Figure 4a and b).

The patient experienced no postoperative complications, other than minimal hematoma at the graft site. A patho-

logical examination revealed a low-grade MPNST tumor developing on the basis of diffuse neurofibroma. The surgical margins were negative (Figure 5a and b). After pathological diagnosis, oncology and rheumatology consultations were requested, and the patient was followed up and treated by these departments. The patient was followed up for around five months, during which no complications developed.

DISCUSSION

MPNSTs develop from the peripheral nerve sheath or branches of the peripheral nerve fibers. Although they may develop spontaneously, they are associated with neurofibromatosis type 1 in most cases. NF-1 gene inactivation is thought to play a role in its pathogenesis (5), although there was nothing remarkable in our patient's family history, and an NF-1 gene analysis was negative. MPNSTs are common in the third and fourth decades, but are rare in childhood and adolescence. They are more common in women than in men (6). The case in the present study was a 56-year-old female.

Malignant schwannoma, neurogenic sarcoma, neurofibrosarcoma and anaplastic neurofibroma are the main types of MPNST; approximately two-thirds of them originate from neurofibromas; and 5-year survival is reported to be 15–21% (7).

Diagnosis is primarily by biopsy. For treatment, the tumor should be resected with surrounding tissues up to the intact border. Following resection, it should be performed local radiotherapy, which has been shown to reduce local recurrence. Accordingly, radiotherapy should be started as early as possible in the postoperative period. In recent publications, it has been reported that neoadjuvant/adjunct chemotherapy after en bloc resection yields similar results to the more radical approaches (3). In the patient in the present study, the mass was completely resected with the surrounding intact tissue, and positive results were obtained with grafting. The patient was then sent to the relevant department for radiotherapy.

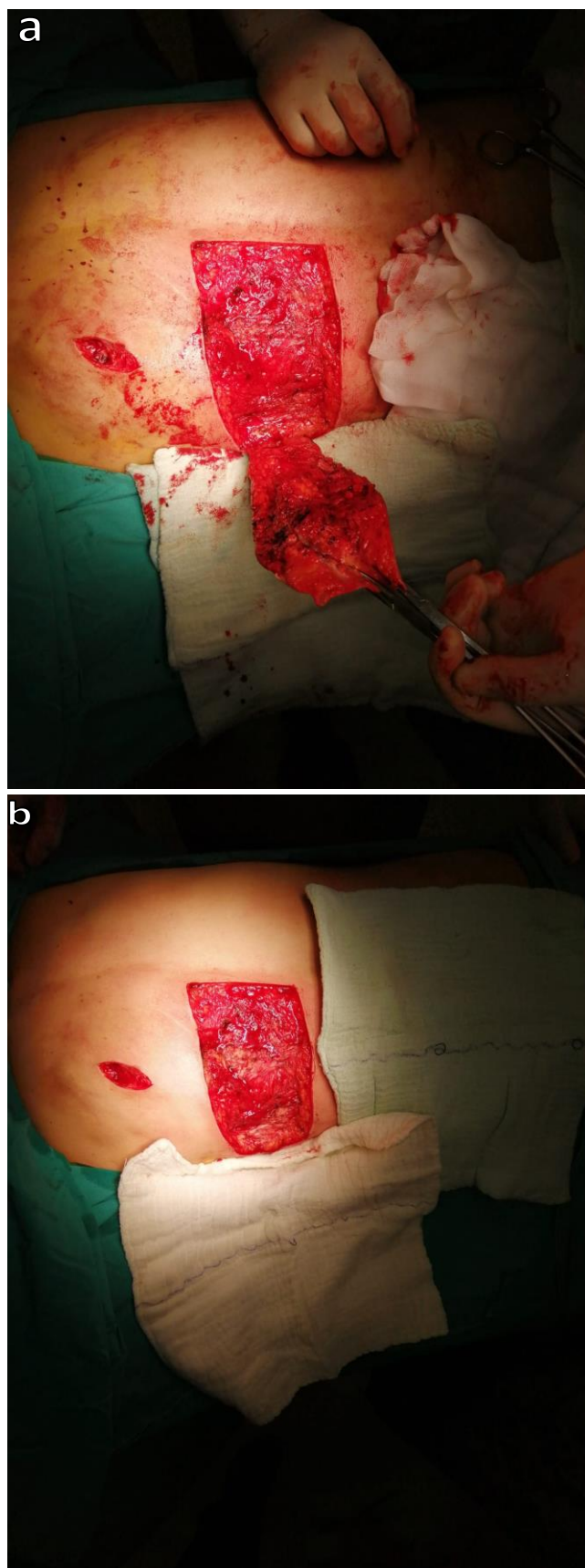


Figure 3a and b: Intraoperative views of the mass

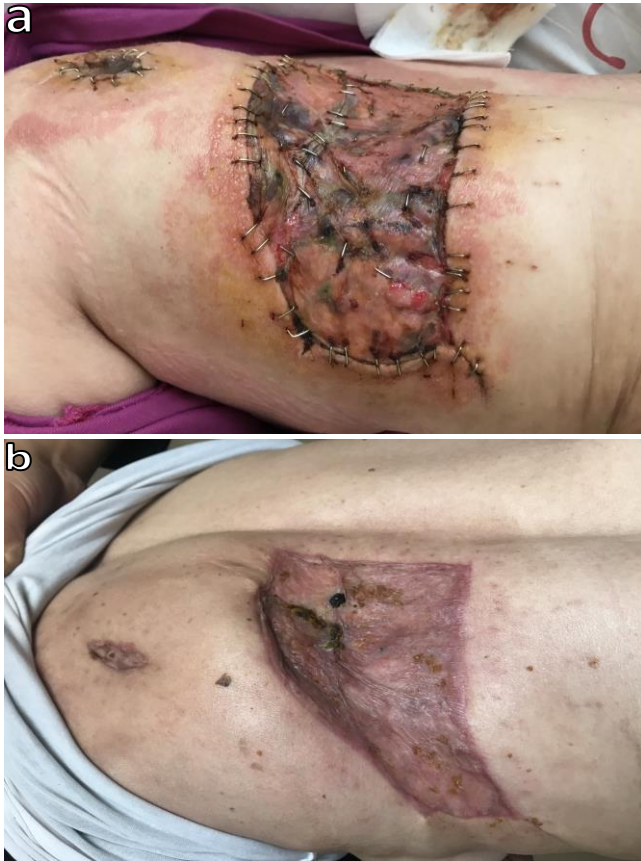

Figure 4a and b: Postoperative 5th day (a), postoperative 1st month (b)

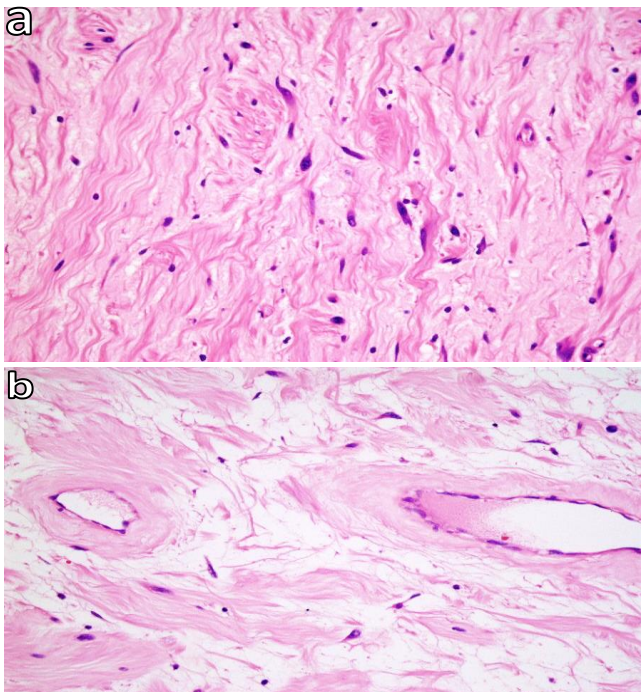


Figure 5a and b: Neurofibroma areas consisting of spindle-shaped and wavy nucleus cells and collagen (HEX400) (a), areas of peripheral nerve sheath tumor with more cellular and sparse atypical cells (HEX400) (b)

In conclusion, MPNSTs are uncommon, and chest wall placements are very rare. MPNSTs should be considered in a differential diagnosis of chest wall malignant masses

in elderly patients. For the treatment of such aggressive and progressive tumors, excision, chemotherapy and radiotherapy should be used to prevent local recurrences.

CONFLICTS OF INTEREST

None declared.

AUTHOR CONTRIBUTIONS

Concept - M.Ç., İ.D.; Planning and Design - M.Ç., İ.D.; Supervision - M.Ç., İ.D.; Funding -; Materials - M.Ç.; Data Collection and/or Processing - M.Ç.; Analysis and/or Interpretation - İ.D.; Literature Review - M.Ç., İ.D.; Writing - T.S.; Critical Review - M.Ç., İ.D.

YAZAR KATKILARI

Fikir - M.Ç., İ.D.; Tasarım ve Dizayn - M.Ç., İ.D.; Denetleme - M.Ç., İ.D.; Kaynaklar -; Malzemeler - M.Ç.; Veri Toplama ve/veya İşleme - M.Ç.; Analiz ve/veya Yorum - İ.D.; Literatür Taraması - M.Ç., İ.D.; Yazıyı Yazan - T.S.; Eleştirel İnceleme - M.Ç., İ.D.

REFERENCES

1. Lin GQ, Li YQ, Huang LJ, Luo FY, Jiang HH, Luo WJ. Chest wall tumors: Diagnosis, treatment and reconstruction. *Exp Ther Med* 2015; 9:1807-12. [\[CrossRef\]](#)
2. Williams LA, Moertel CL, Richardson M, Marcotte E. Incidence of second malignancies in individuals diagnosed with malignant peripheral nerve sheath tumors. *J Neurooncol* 2020; 147:701-9. [\[CrossRef\]](#)
3. Guha D, Davidson B, Nadi M, Alotaibi MN, Fehlings MG, Gentili F, et al. Management of peripheral nerve sheath tumors: 17 years of experience at Toronto Western Hospital. *J Neurosurg* 2018; 128:1226-34. [\[CrossRef\]](#)
4. Aksoy Y, Obuz Ç, Çitak N, İşgörücü Ö, Büyükkale S, Sayar A. Periferik interkostal sinir kaynaklı asemptomatik schwannoma. *Med Bull Haseki* 2017; 55:154-6. [\[CrossRef\]](#)
5. Gutmann DH, Ferner RE, Listernick RH, Korf BR, Wolters PL, Johnson KJ. Neurofibromatosis type 1. *Nat Rev Dis Primers* 2017; 3:17004. [\[CrossRef\]](#)
6. Samsuddin MFB, Omar MAB. Malignant peripheral nerve sheath tumor: Treat or not treat? *Asian J Neurosurg* 2019; 14:283-5. [\[CrossRef\]](#)
7. Peltonen S, Kallionpää RA, Rantanen M, Uusitalo E, Lähteenmäki PM, Pöyhönen M, et al. Pediatric malignancies in neurofibromatosis type 1: A population-based cohort study. *Int J Cancer* 2019; 145:2926-32. [\[CrossRef\]](#)