

# Perforated duodenal diverticulum: A case report

**Mehmet Gulmez, Mehmet Kamil Yildiz, Hacı Mehmet Odabasi,  
Hacı Hasan Abuoglu, Onur Ilhan, Kubra Kaytaç**

Department of General Surgery, Haydarpasa Numune Training and Research Hospital, Istanbul, Turkey

## ABSTRACT

Duodenum is the second most frequent location for diverticulum in the digestive tract, surpassed only by the colon. Perforation is rare, but it is the most serious complication of duodenum diverticula. Presently described is case of 22-year-old male patient who presented at emergency department with abdominal pain and vomiting. Surgery was performed with prediagnosis of perforated duodenum diverticula based on results of computed tomography.

*Keywords: Duodenal diverticulum; duodenum; perforation.*

Duodenum is the second most frequent location for a diverticulum in the digestive tract after the colon. From duodenal diverticula complications as diverticulitis, pancreatitis, bleeding, choleductal occlusion and perforation can develop. Perforation is the most rarely seen, but the most serious complication.

In this paper, we aimed to present a 22-year-old-patient operated with the diagnosis of perforated duodenal diverticulum who presented with clinical manifestations of acute abdomen.

## CASE REPORT

A 22-year-old male patient consulted to our emergency service with complaints of abdominal pain

and vomiting persisting for two days. His anamnesis did not reveal any disease or previous operation. His vital signs were as follows: ABP: 120/70 mmHg, pulse rate: 78/min, body temperature: 36.7°C. On physical examination marked tenderness and abdominal guarding were detected on the upper right abdominal quadrant. Rebound sign was not found. Digital rectal examination and examination of other bodily systems did not reveal any abnormality. Some laboratory test results were as follows: Htc: 42.2 WBC: 13800/mm<sup>3</sup>, FBG: 142 mg/dL, BUN: 19 mg/dL, creatinine: 0.8 mg/dL, C-reactive protein 7.65 mg/dL. Hepatic enzymes and amylase values were within normal limits. Upright abdominal radiograms did not demonstrate any evidence suggesting subdiaphragmatic free air. Gallbladder and biliary tracts were normal on whole

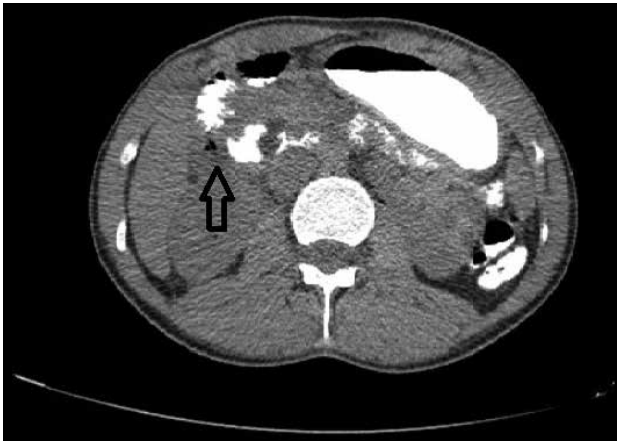*Received:* December 07, 2014 *Accepted:* April 05, 2015

*Correspondence:* Dr. Mehmet GULMEZ. Haydarpasa Numune Egitim ve Arastirma Hastanesi, Genel Cerrahi Klinigi, Istanbul, Turkey.

Tel: +90 216 - 542 32 32 e-mail: mehmetgulmez86@hotmail.com

© Copyright 2016 by Istanbul Northern Anatolian Association of Public Hospitals - Available online at [www.kuzeyklinikleri.com](http://www.kuzeyklinikleri.com)



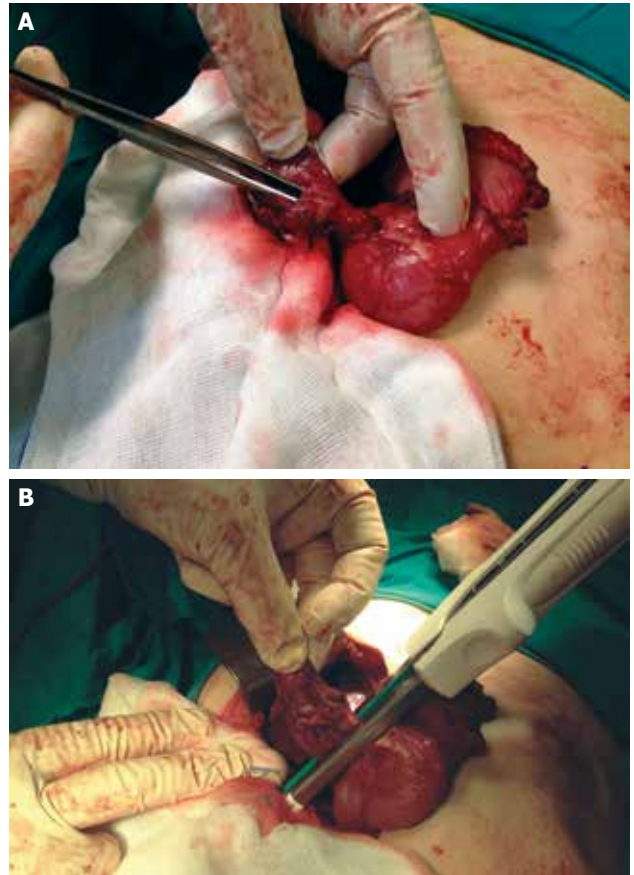


**FIGURE 1.** Duodenal diverticulum and free air in its vicinity.

abdominal ultrasound without intraabdominal free fluid. The patient underwent oral/intravenous contrast-enhanced computed tomography (CT) and at the junction of 2., and 3. parts of the duodenum, a 3.5 cm –long diverticulum filled with oral contrast material and free air in its vicinity were detected (Figure 1). The patient was urgently operated with the diagnosis of perforated duodenal diverticulum. Surgical exploration revealed the presence of periduodenal phlegmon. Following liberation of the duodenum using Kocher manoeuvre, perforated duodenal diverticulum was detected at the junction of the second and third part of the duodenum (Figure 2 A). Diverticulum was nearly 4 cm in length and diverticulectomy was performed using GIA linear cutting stapler (GIATM Stapler, Covidien, Mansfield, MA, USA) (Figure 2 B). The patient was discharged without any postoperative problem and complaint.

## DISCUSSION

Duodenal diverticulum was firstly described by Chomel in the year 1710 [1]. The incidence rates of duodenal diverticulum are 0.8–1% in contrast-enhanced radiograms, 20–32% in autopsy series and 7–23% in ERCP series [2, 3]. Duodenum is the second most frequent location for a diverticulum in the digestive tract after the colon. Duodenal diverticula have been classified as congenital and acquired. Acquired duodenal diverticula are more frequently seen and they occur as a result of mucosal and sub-



**FIGURE 2. (A)** Perforated duodenal diverticulum. **(B)** Diverticulectomy performed using GIA linear cutter stapler.

mucosal herniation through the area where blood vessels penetrate and weaken muscular layer. Since they are not covered by any muscular layer they are called “psedodiverticula”. Acquired diverticula are extraluminal. They can be multiple and generally they are localized on the mesenteric aspect of the second part of the duodenum. Though congenital diverticula frequently localized on the second part of the duodenum, they can extend up to the fourth part of the duodenum.

Complications of duodenal diverticula can develop including diverticulitis, pancreatitis, bleeding, choleductal obstruction and perforation. Perforation is a rarely seen, but the most serious complication [4]. In the literature, only 162 cases have been reported [5]. Perforation can be iatrogenic [6], and occur during ERCP procedure or develop as a result of erosion due to enterolith [7], and diverticulitis [8].

Usually nonspecific symptoms are seen. Most frequently, sudden onset of right upper abdominal quadrant pain, nausea and vomiting are observed. Rarely signs of peritoneal irritation are observed. [9]. Since perforation of the duodenal diverticulum occurs mostly in the retroperitoneal space, upright plain abdominal radiogram generally does not demonstrate presence of free air. Because of difficulties in establishing preoperative diagnosis, only in 13% of the cases accurate preoperative diagnosis could be made [10].

Computed tomography (CT) is the most useful diagnostic method in cases with perforated duodenal diverticulum. Computed tomography can demonstrate retroperitoneal abscess, fluid and air [8].

It has been reported that in selected advanced patients with serious comorbidities and those with milder symptoms and physical examination findings without any evidence of sepsis have been treated with conservative methods as nasogastric drainage, hydration with intravenous fluids, intravenous antibiotherapy and total parenteral nutrition [5]. The optimal treatment option for the perforated duodenal diverticulum is surgery. We also considered surgical alternative as a priority because of the signs of peritoneal irritation detected on physical examination. The most frequently preferred method is diverticulectomy combined with single or two-layered closure [11]. Dependent on the location of duodenal diverticula, the presence of biliary tract obstruction, severity of retroperitoneal inflammation, duodenal diversion, tube duodenostomy, segmental duodenum resection or more complex surgical methods as pylorus-sparing Whipple operation can be performed [11, 12]. The complications of the surgical interventions applied include duodenal fistula, intraabdominal abscess, sepsis, and pancreatitis [10]. Laparoscopic interventions also reportedly yielded successful outcomes [13].

## Conclusion

Duodenal diverticulum is a rarely seen serious complication which can be fatal. Computed tomography is the most important diagnostic imaging modality and surgery is the most effective treatment method.

The patient gave his “Informed Volunteer Consent Form” concerning use of his medical information for scientific publication.

**Conflict of Interest:** No conflict of interest was declared by the authors.

**Financial Disclosure:** The authors declared that this study has received no financial support.

## REFERENCES

1. Chomel JB. Report of a case of duodenal diverticulum containing gallstones. *Acad R Sci Paris* 1710;48–50.
2. Ersan Y, Yavuz N, Çiçek Y, Ergüney S, Kuşaslan R, Belli A, et al. Clinical analysis and review of related literature in cases of duodenal diverticulosis. *Cerrahpaşa J Med* 2005;36:120–7.
3. Yin WY, Chen HT, Huang SM, Lin HH, Chang TM. Clinical analysis and literature review of massive duodenal diverticular bleeding. *World J Surg* 2001;25:848–55. [Crossref](#)
4. Ming TY, Feng HK, Cheng YJ, Chuan CD, Pai LT, Chi LY. Clinical challenge: diverticulitis of third and fourth portion of the duodenum with perforation. *Rev Esp Enferm Dig* 2012;104:156–7. [Crossref](#)
5. Thorson CM, Ruiz PS, Roeder RA, Sleeman D, Casillas VJ. The perforated duodenal diverticulum. *Arch Surg* 2012;147:81–8.
6. Cavanagh JE Jr. Iatrogenic perforation of perivaterian duodenal diverticulum: report of a case. *Can J Surg* 1996;39:336–8.
7. Franzen D, Gürtler T, Metzger U. Solitary duodenal diverticulum with enterolith as a rare cause of acute abdomen. [Article in German] *Swiss Surg* 2002;8:277–9. [Abstract] [Crossref](#)
8. Sakurai Y, Miura H, Matsubara T, Imazu H, Hasegawa S, Ochiai M. Perforated duodenal diverticulum successfully diagnosed preoperatively with abdominal CT scan associated with upper gastrointestinal series. *J Gastroenterol* 2004;39:379–83. [Crossref](#)
9. Favre-Rizzo J, López-Tomassetti-Fernández E, Ceballos-Esparagón J, Hernández-Hernández JR. Duodenal diverticulum perforated by foreign body. *Rev Esp Enferm Dig* 2013;105:368–9.
10. Duarte B, Nagy KK, Cintron J. Perforated duodenal diverticulum. *Br J Surg* 1992;79:877–81. [Crossref](#)
11. Martinez-Cecilia D, Arjona-Sanchez A, Gomez-Alvarez M, Torres-Tordera E, Luque-Molina A, Valenti-Azcarate V. Conservative management of perforated duodenal diverticulum: a case report and review of the literature. *World J Gastroenterol* 2008;14:1949–51. [Crossref](#)
12. Schnueriger B, Vorburger SA, Banz VM, Schoepfer AM, Candinas D. Diagnosis and management of the symptomatic duodenal diverticulum: a case series and a short review of the literature. *J Gastrointest Surg* 2008;12:1571–6. [Crossref](#)
13. Tagaya N, Shimoda M, Hamada K, Ishikawa K, Kogure H. Laparoscopic duodenal diverticulectomy. *Surg Endosc* 2000;14:592.