

Pustular eruption induced by etanercept in a patient with ankylosing spondylitis: a rare side effect

Asude Kara,¹ Emine Tugba Alatas,² Hilal Semra Celebi,² Gursoy Dogan,² Yelda Dere³

¹Department of Dermatology, Mugla Sitki Kocman University Training and Research Hospital, Mugla, Turkey

²Department of Dermatology, Mugla Sitki Kocman University Faculty of Medicine, Mugla, Turkey

³Department of Pathology, Mugla Sitki Kocman University Faculty of Medicine, Mugla, Turkey

ABSTRACT

Etanercept is a tumor necrosis factor alpha (TNF- α) antagonist with anti-inflammatory effects. It is used in the treatment of dermatologic and rheumatologic diseases such as rheumatoid arthritis, polyarticular juvenile rheumatoid arthritis, psoriatic arthritis and ankylosing spondylitis. However, etanercept has various cutaneous and systemic side effects. Herein, we report a case of generalized pustular eruption due to etanercept therapy in an ankylosing spondylitis patient and review pustular diseases.

Keywords: Ankylosing spondylitis; etanercept; pustular drug eruption.

Etanercept is the first tumor necrosis factor- α (TNF- α) antagonist obtained from human protein. Etanercept is an FDA approved drug was firstly used in the treatment of rheumatoid arthritis (RA) in the year 1998. It has been used in the treatment of polyarticular juvenile rheumatoid arthritis, psoriatic arthritis, ankylosing spondylitis (AS) and moderate-severe chronic plaque psoriasis with FDA approval [1]. Pustular eruption due to etanercept is rare. Pustular eruption commonly seen with antibiotics, corticosteroids, antiepileptic agents, antihistaminics, and nonsteroidal anti-inflammatory drugs [2]. Herein, we report a case of pustular eruption developed due to etanercept therapy in an AS patient.

CASE REPORT

A 45-year-old male with the diagnosis of AS, consulted to our outpatient clinic with itching and pustular eruption on his palms, soles, trunk, and back. His complaints had developed after the first course of etanercept treatment. The skin rash had started on the back 1.5 months ago and gradually had increased after the second and third courses of etanercept therapy, and finally had spread to the palms and soles. The medical history was unremarkable. In the family history, mother of the patient had diabetes mellitus and hypertension, his father had coronary artery disease. The patient was generally healthy and had no fever. Laboratory tests were unremarkable. On

Received: December 26, 2014 *Accepted:* April 09, 2015 *Online:* July 24, 2015

Correspondence: Dr. Asude KARA, Mugla Sitki Kocman Universitesi Egitim ve Arastirma Hastanesi, Deri ve Zuhrevi Hastaliklar Klinigi, Mugla, Turkey.

Tel: +90 252 - 214 13 23 e-mail: asudekara@yahoo.com.tr

© Copyright 2015 by Istanbul Northern Anatolian Association of Public Hospitals - Available online at www.kuzeyklinikleri.com



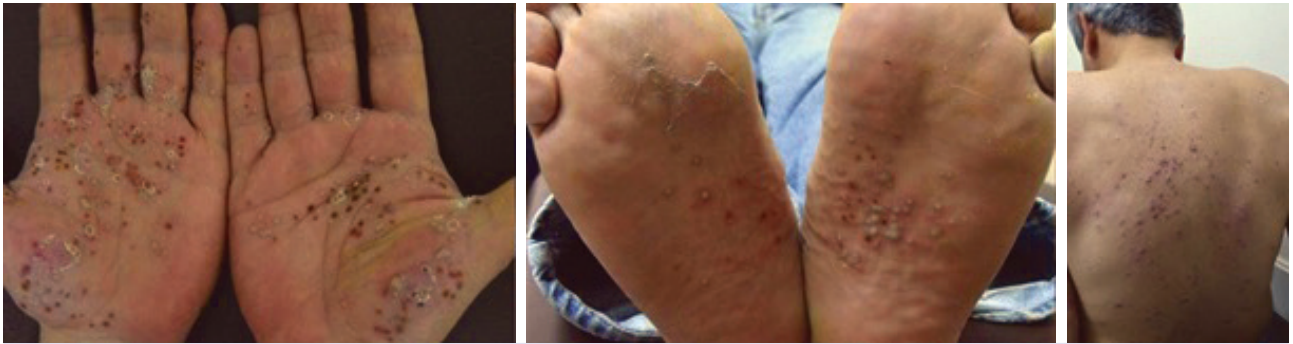

FIGURE 1. Multiple pustular lesions on the palmoplantar areas and back.

dermatological examination, multiple erythematous pustules and papules were observed on the both palmar and plantar regions, trunk, and back (Figures 1–3). There was no bacterial growth on the culture media taken from the pustular lesion.

Histopathological examination revealed intraepidermal infiltration of neutrophils and eosinophils, and also inflammatory cells infiltration in the papillary dermis (Figure 3). We diagnosed the patient as pustular drug eruption with the histopathological and clinical findings. After withdrawal of the etanercept therapy, the skin lesions cleared within 3 weeks. Low-dose oral methylprednisolone, oral antihistaminic, and topical steroid therapies were started. We did not observe any new skin lesion during the follow-up of a year.

DISCUSSION

Pustular drug eruptions are rarely seen forms of drug reactions. In diagnosis of pustular drug

eruption, presence of suspicious drug use history, histopathological examination, and rule out of other pustular dermatoses are important. The most frequently responsible drugs are antibiotics, antifungal, antituberculostatic, and antiepileptic drugs. Pustular drug eruption due to TNF- α antagonists have been reported previously [3, 4].

TNF- α antagonists have been successfully used in the treatment of several chronic autoimmune and inflammatory diseases. Among these agents, etanercept is a recombinant TNF- α receptor (TNFR) fusion protein and constitutes of two extracellular components bound to Fc fragment of human IgG. It competitively inhibits the interaction of circulatory TNF- α with cell surface receptors [5]. It is an effective agent in the treatment of moderately severe chronic psoriasis, psoriatic arthritis, RA, juvenile rheumatoid arthritis, and AS. Although it has been safely used in many diseases, drug-induced adverse effects have been observed [6].

Etanercept has systemic adverse effects involving

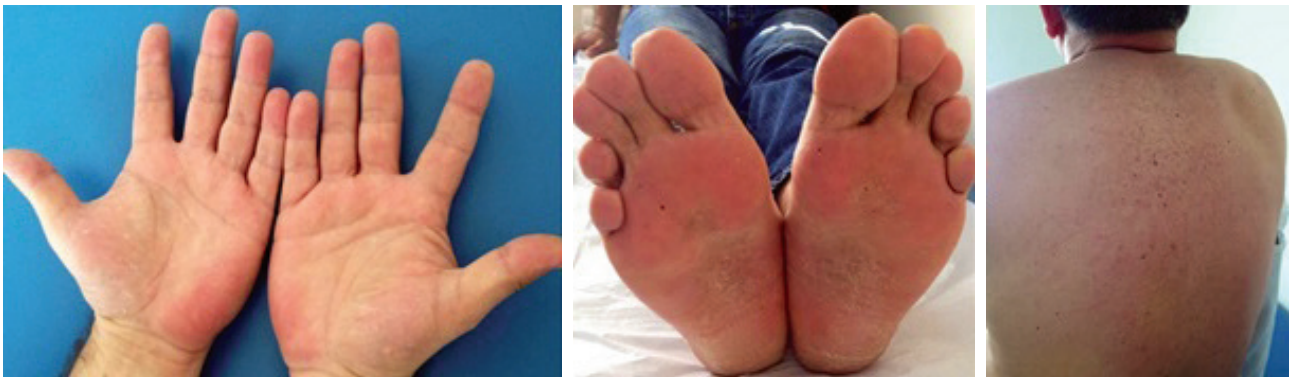

FIGURE 2. Improvement in the skin lesions after the treatment.

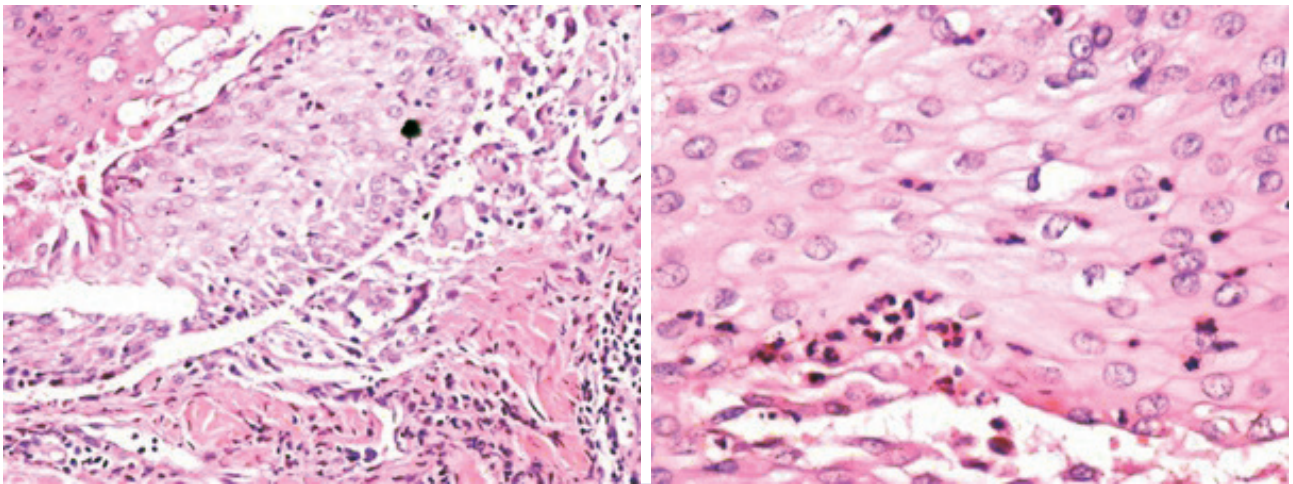


FIGURE 3. Inflammatory cell infiltration in the epidermis and papillary dermis (H&E, x200), Neutrophils and eosinophils infiltration in the epidermis (H&E, x400).

activation of latent infections such as tuberculosis, increase the frequency of demyelinating diseases, and development of malignancy [7]. In addition, cutaneous adverse effects of etanercept are not rare. Cutaneous reactions have been reported in nearly 65 cases [7]. The most frequently reported cutaneous adverse effect of etanercept is injection site reaction. This reaction is characterized by erythema, itching, pain, and edema on the injection site [7, 8]. In our case, we did not observe such a reaction during the etanercept therapy.

Etanercept induces various cutaneous symptoms that exacerbation of psoriasis symptoms is one of the adverse effects. It has been recommended that these symptoms should be treated as psoriasis and another TNF- α antagonist should be started in resistant cases [6]. However, in a case series reported in the literature, in two cases treated with anti-TNF- α , upon development of psoriatic symptoms, another anti-TNF- α agent also induced psoriatic manifestations [9]. In the literature, apart from etanercept, exacerbation of psoriatic symptoms has been observed also with infliximab and adalimumab. In a study performed by Joyau et al., pustular lesions, especially on palmoplantar regions, have been observed in the patients with AS, Crohn's disease, RA, plaque psoriasis on anti-TNF- α therapy with the frequency of 33%. Of these patients, 1.7% had palmoplantar pustular psoriasis. In nearly half of the patients, these side effects developed secondary to infliximab. In the same study literature had been

reviewed and 42.9% of 184 cases on anti-TNF- α had pustular lesions as adverse effects [10].

Other cutaneous adverse effects due to etanercept are eczematous eruptions, cutaneous lymphoma, herpes simplex infection, bacterial infections, lichenoid eruptions, erythema multiforme, lupus erythematosus, and acute generalized exanthematous pustulosis. Among 153 patients reported as case reports, psoriasis and its subtypes (n=38), skin infections (n=31), malignancies (n=15), lupus and related skin manifestations (n=19), and other non-specific skin diseases (n=35) have been found associated with adverse effects due to etanercept that nonspecific skin rash was the most frequently detected finding [7]. In only one case, generalized maculopapular eruption have been reported [11]. In a study, an increase in the frequency of pustular dermatitis has been reported during anti-TNF- α therapy. This study revealed that especially TNF- α blockage increased the release of interferon- α (IFN- α) and the frequency of pustular dermatitis and psoriasis [12]. In our case, we observed erythematous pustules and papules on both palmar and plantar regions, ventral side of trunk, and back as adverse effects of etanercept treatment.

In the differential diagnosis of pustular eruption, generalized pustular psoriasis, Reiter syndrome, subcorneal pustular dermatosis, acute generalized exanthematous pustulosis (AGEP), acneiform drug eruptions, folliculitis, eosinophilic folliculitis,

TABLE 1. Clinical and histopathological features of pustular diseases

Disease	Clinic	Histopathology
Generalized pustular psoriasis	Sterile pustules with erythematous surface on the back, extremities, and palmoplantar region	Spongiform neutrophilic pustules, parakeratosis, elongation of rete, and mononuclear cell infiltration in the dermis
Acute generalized exanthematous pustulosus	Fever, leukocytosis, nonfollicular sterile fistulas, involvement of skin folds, intact palmoplantar region	Spongiform pustules, massive edema in the superficial dermis, perivascular eosinophilic infiltration, and keratinocytic necrosis
Reiter syndrome	Urethritis, oligoarthritis, conjunctivitis, onset of vesicular and pustulous formation on the palmoplantar region, and then transform into hyperkeratotic lesions (keratoderma blennorrhagica)	Psoriasiform changes; epidermal hyperkeratosis and parakeratosis, acanthosis, elongation of retes and infiltration of mixed inflammatory cells
Subcorneal pustular dermatosis	Loose sterile annular and serpinginous pustules with erythematous surface on the inguinal, axillary regions, flexor side of extremities, under breast, and abdomen	Subcorneal pustules containing neutrophils
Acneiform drug eruption	Follicular sterile pustules without comedones on the back, shoulders and upper arm	T-cell infiltration in follicular infundibulum, in suppurative folliculitis in hair follicle at late stage
Folliculitis	Follicular pustules on the scalp, axilla, inguinal region, and extremities	Follicular fistula
Eosinophilic folliculitis	In HIV patients sterile papules and pustules on the chest, scalp, and face; higher serum IgE levels	Follicular and perifollicular abscesses mainly with eosinophilic content
Palmoplantar pustulosis	Pustules on the palmoplantar region developing in a short time	Sterile intraepidermal pustules infiltrated with polymorphonuclear leukocytes
SAPHO (synovitis, acne, pustulosis, hyperostosis, and osteitis)	Various dermatological manifestations such as palmoplantar pustulosis, pustular psoriasis, and acne conglobata	Parakeratosis, hyperkeratosis, psoriasiform hyperplasia, and acanthosis
Hand, foot, and mouth disease	Vesiculopustules on the palmoplantar region and oral mucosa surrounded by an erythematous halo	Vacuolar and reticular degeneration in the epidermis
Varicella	Polymorphous lesions consisting of papules, vesicles, and pustules on the scalp, back, face and extremities	Intracellular edema in the epidermis (balloon degeneration) and nuclear changes

palmoplantar pustulosis, SAPHO (synovitis, acne, pustulosis, hyperostosis, and osteitis), hand-foot-and-mouth disease, and viral diseases such as

varicella should be considered [3, 13, 14, 15, 16]. Clinical and histopathological examinations are helpful in the differential diagnosis (Table 1).

Histopathologically, acanthosis and psoriatic changes at dermoepidermal junction are seen in pustular psoriasis, whereas massive edema in the superficial dermis, perivascular eosinophilic infiltration, and keratinocytic necrosis are seen in AGEP [8]. Histopathological examination of our patient revealed intraepidermal cells infiltration involving neutrophils and eosinophils and also inflammatory cells infiltration in the papillary dermis. We diagnosed the patient as pustular drug eruption with these clinical and histopathological findings.

In conclusion, cutaneous side effects can be seen with etanercept therapy and the therapy should be discontinued if these adverse effects develop. Adverse effects regress with cessation of etanercept therapy in most cases, however, cutaneous symptoms should be treated in some cases [7, 8]. We observed marked improvement in the skin lesions after cessation of etanercept therapy. In addition, we also started therapies for cutaneous symptoms.

Informed consent of the patient was obtained: Received.

Conflict of Interest: No conflict of interest was declared by the authors.

Financial Disclosure: The authors declared that this study has received no financial support.

REFERENCES

- Akdeniz N, Çalka Ö, Bilgili SG. Biyolojik ajanlar. In: Tüzün Y, Serdaroğlu S, Erdem C, Özpoyraz M, Önder M, Öztürkcan S, editor. *Dermatolojide tedavi*. İstanbul: Nobel Tıp Kitapevleri 2010. p. 927–41.
- Adams BB, Mutasim DF. Pustular eruption induced by olanzapine, a novel antipsychotic agent. *J Am Acad Dermatol* 1999;41(5 Pt 2):851–3.
- Mengesha YM, Bennett ML. Pustular skin disorders: diagnosis and treatment. *Am J Clin Dermatol* 2002;3:389–400.
- Vasconcelos LMF, Teixeira FM, Francelino EV, Almeida TLP, Chagas LB, Valença JT, et al. Acute generalized exanthematous pustulosis in a 51-year-old patient under etanercept treatment for psoriasis. *J Pharmacovigilance* 2014;2:120.
- Weinblatt ME, Kremer JM, Bankhurst AD, Bulpitt KJ, Fleischmann RM, Fox RI, et al. A trial of etanercept, a recombinant tumor necrosis factor receptor:Fc fusion protein, in patients with rheumatoid arthritis receiving methotrexate. *N Engl J Med* 1999;340:253–9.
- Collamer AN, Guerrero KT, Henning JS, Battafarano DF. Psoriatic skin lesions induced by tumor necrosis factor antagonist therapy: a literature review and potential mechanisms of action. *Arthritis Rheum* 2008;59:996–1001.
- Kavala M, Zindancı I, Türkoglu Z, Can B, Kocatürk E, Senol S, et al. Acute generalized exanthematous pustulosis induced by etanercept: another dermatologic adverse effect. *Case Rep Dermatol Med* 2013;2013:601412.
- Revuz J, Valeyrie-Allanore L. Drug Reactions. In: Bologna JL, editor. *Dermatology* 2012;21:335–56.
- Cohen JD, Bournerias I, Buffard V, Paufler A, Chevalier X, Bagot M, et al. Psoriasis induced by tumor necrosis factor-alpha antagonist therapy: a case series. *J Rheumatol* 2007;34:380–5.
- Joyau C, Veyrac G, Dixneuf V, Joliet P. Anti-tumour necrosis factor alpha therapy and increased risk of de novo psoriasis: is it really a paradoxical side effect? *Clin Exp Rheumatol* 2012;30:700–6.
- Lai-Cheong J, Warren R, Bucknall R, Parslew R. Etanercept-induced dermatitis in a patient with rheumatoid arthritis. *J Eur Acad Dermatol Venereol* 2006;20:614–5.
- de Gannes GC, Ghoreishi M, Pope J, Russell A, Bell D, Adams S, et al. Psoriasis and pustular dermatitis triggered by TNF- α inhibitors in patients with rheumatologic conditions. *Arch Dermatol* 2007;143:223–31.
- Dimitrova V, Yordanova I, Pavlova V, Valtchev V, Gospodinov D, Parashkevova B, et al. Keratoderma blenorrhagicum in a patient with Reiter syndrome. *J of IMAB* 2008;14:68–71.
- İlaç ve diğer tedavi reaksiyonları. In: Baykal C, editör. *Dermatoloji atlası*. 3. baskı. İstanbul: Nobel Tıp Kitapevleri 2012. p. 344–69.
- Zhao Z, Li Y, Li Y, Zhao H, Li H. Synovitis, acne, pustulosis, hyperostosis and osteitis (SAPHO) syndrome with review of the relevant published work. *J Dermatol* 2011;38:155–9.
- Öztürkcan S. Derinin viral hastalıkları. In: Tüzün Y, Serdaroğlu S, Erdem C, Özpoyraz M, Önder M, Öztürkcan S, editor. *Dermatolojide tedavi*. İstanbul: Nobel Tıp Kitapevleri 2010. p. 554–650.