

Flexible flatfoot

Aziz Atik¹, Selahattin Ozyurek²

¹Department of Orthopedics and Tarumatology, Balikesir University Faculty of Medicine, Balikesir, Turkey;

²Department of Orthopedics and Traumatology, Aksaz Military Hospital, Marmaris, Mugla, Turkey

ABSTRACT

While being one of the most frequent parental complained deformities, flatfoot does not have a universally accepted description. The reasons of flexible flatfoot are still on debate, but they must be differentiated from rigid flatfoot which occurs secondary to other pathologies. These children are commonly brought up to a physician without any complaint. It should be kept in mind that the etiology may vary from general soft tissue laxities to intrinsic foot pathologies. Every flexible flatfoot does not require radiological examination or treatment if there is no complaint. Otherwise further investigation and conservative or surgical treatment may necessitate.

Key words: Children; flatfoot; flexible; foot problem; pes planus.

Though the term flatfoot (*pes planus*) is generally defined as a condition which the longitudinal arch of the foot collapses, it has not a clinically or radiologically accepted universal definition. Flatfoot which we frequently encounter in routine outpatient practice will be more accurately seen as a result of laxity of ligaments of the foot. However each case of flatfoot is not similar to each other. Staheli divided flatfoot into 2 groups as physiological, and pathological flatfoot [1, 2, 3]. Within this context, flexible (flexible, physiological, and hypermobile) flatfoot should be differentiated from secondary ones which can develop as a consequence of other pathologies. In flexible flatfoot, medial longitudinal arch of the foot collapses in various degrees during weight-bearing (Figure 1). However during raising up one's body on tiptoe (tiptoe test) foot arch

forms again (Figure 2). When weight-bearing forces on feet are relieved this arch can be observed. If the foot is not bearing any weight, still medial longitudinal arch is not seen, then it is called rigid (fixed) flatfoot. To differentiate between these two conditions easily, Jack's test (great toe is dorisflexed as the plantar fascia tightens) can be used (Figure 3). In this review flexible flatfoot will be discussed.

Though actual incidence of flatfoot in children is not known, it is acknowledged that it is one of the most frequently seen deformities which cause parent's complaints in the outpatient clinic of pediatrics. Still, the issue whether flexible flatfoot is a real deformity is debatable. For instance Staheli et al. [2] performed a study investigating the development of medial longitudinal arch of the sole, and revealed that "flatfoot is generally seen in infants,

Received: May 29, 2014 Revised: July 18, 2014 Accepted: July 25, 2014 Online: August 03, 2014

Correspondence: Aziz ATIK, Balikesir Universitesi Cagis Yerleskesi Tip Fakultesi, Ortopedi ve Travmatoloji Anabilim Dalı, 10440 Balikesir, Turkey.

Tel: +90 216 - 566 66 00 e-mail: filizsvet@yahoo.com

© Copyright 2014 by Istanbul Northern Anatolian Association of Public Hospitals - Available online at www.kuzeyklinikleri.com



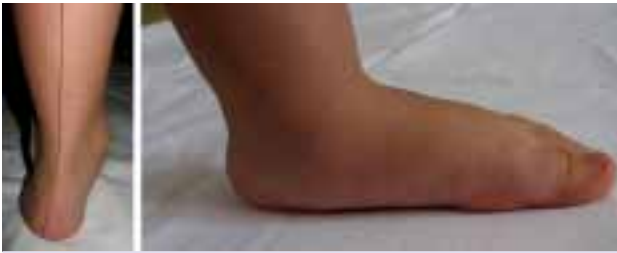

FIGURE 1. Collapse of the weight-bearing foot. During weight-bearing, disappearance of the medial longitudinal arch of the foot is seen. On posterior view, angling of the Achilles tendon (hindfoot valgus) is observed.

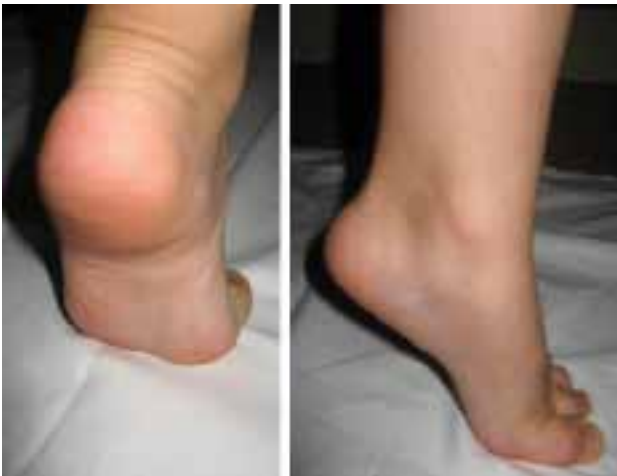

FIGURE 2. Tiptoe test. While raising up on tiptoe, reconstruction of the medial longitudinal arch collapsed during weight-bearing is observed.

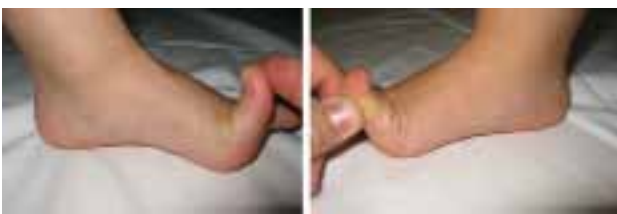

FIGURE 3. Dorsiflexion of the great toe test. When great toe is brought to passive dorsiflexion position, emergence of medial longitudinal arch is observed.

prevalently in children, and occasionally in adults". In their study, Wenger et al.[4] concluded that "flexible flatfoot is an unavoidable outcome of trying to walk on normal foot bones with loose ligaments." Apparently, most of the time flatfoot does not cause any problem.

Epidemiology

In 90% of the children aged <2 years, an anatomic variation resembling flatfoot can be seen which is due to infantile adipose cushion formation localized on the medial part of the foot. Besides toddlers who start to walk can assume a flatfoot posture. In fact they try to walk with their feet resting entirely on the ground so as to maintain a balanced posture. Consequently, they shift their weight-bearing axis to the first or second tarsometatarsal joint which may induce a flatfoot posture. In most of the children normal longitudinal arch develops at 3-5 years of age (Figure 4), and in only 4% of them flatfoot persists after 10 years of age.

Well, how is the situation in adults? In nearly 23% of the adult population collapse of the medial longitudinal arch of the foot can be seen [5]. However it is not an isolated entity, and in two thirds of the cases, subtalar complex, hyperflexible ankle joint, and in one-fourths contracture of the triceps surae muscle have been observed [5, 6]. Probably these combined pathologies cause patients' complaints rather than collapse of the medial longitudinal arch per se.

Etiopathology

Many theories have been generated related to the causes of flexible flatfoot, however precise etiology

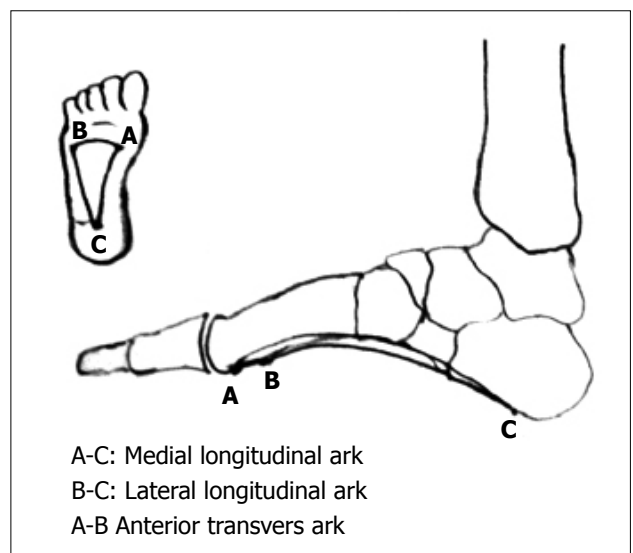


FIGURE 4. Schematic demonstration of the arches of the foot. Three foot arches are schematically displayed.

has not been elucidated yet. During routine outpatient practice, family history, and obesity are routinely inquired, while general theories are based on structural bone deformities, muscular imbalance, and ligamentous laxity.

Foot bones supported with ligaments, tendons, and capsular structures form the normal medial longitudinal arch of the foot. Foot muscles do not maintain longitudinal arch. Electromyographic (EMG) studies have revealed that neither intrinsic, nor extrinsic muscles support, and maintain longitudinal arches at standing posture [7]. However during walking, and activities performed, both muscle groups maintain dynamic stabilization of the arch. In a study reinforcing this argument, Fiolkowski discovered the importance of intrinsic muscles of the foot in providing support for medial longitudinal arch [8]. In recent studies, flatfoot seen in posterior tibial tendon insufficiency which has been studied extensively, suggests the importance of this musculature. In their biomechanical study, Huang et al. indicated that plantar fascia is the most important anatomical structure contributing to the stability of the medial arch, followed by talonavicular, and spring ligaments [9].

In the normal weight-bearing pattern, lateral edge of the foot, the first, and the fifth metatarses come in contact with the ground. However, in flatfooted in-

dividuals valgus shift of the calcaneus occurs resulting in loss of support for talar head which assumes a more upright position. Normal arch is lost, the existing pattern shifts to the medial, and foot sole rests more heavily on the ground (Figure 5).

When the foot is in supination, bones of the midfoot are locked, and lose much of their capacity to move. However joints of the pronated foot become more mobile. During weight-bearing, eversion of the heel, and abduction of the forefoot cause collapse of the midfoot, shortening of the longitudinal arch, and consequently talar head, and navicular tuberosity rest on the floor, and bears the whole weight. With time Achilles tendon shortens, and everts the foot with potential worsening of the deformity, and development of tendon contracture. Many techniques have been used to identify, and define medial longitudinal arch of the foot including radiological imaging modalities, podoscopic systems which employ mirror to show the contact area beneath the foot, whole toeless footprint analysis, arch height, and foot plantar pressure measurements. To obtain quantitative data, Clarke angle, Chippaux-Smirak Index (CSI), Staheli arch index have been defined. Among them CSI [10, 11] has been reported to have a predictive value above 90 percent [12]. CSI is the ratio between the widest (segment a) and the narrowest (segment b) areas with borders passing through metatarsal heads as estimated from podographic measurements of footprints. The classification of feet based on b/a ratio

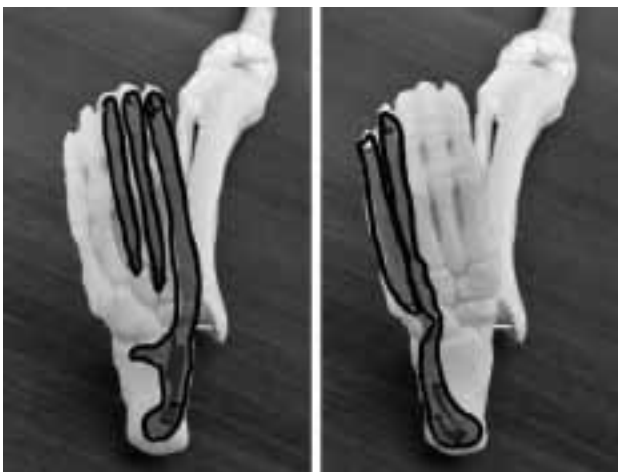

FIGURE 5. Weight- shifting pattern. During normal walking weight-bearing pattern passing through lateral edge of the foot, shifts to the medial side, and medial structures rest on the floor.

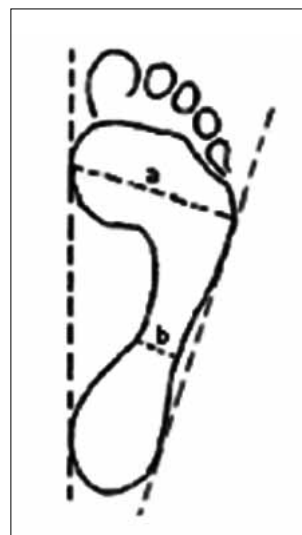


FIGURE 6. Chippaux-Smirak index: $CSI = b/a$. The ratio between the widest (segment a), and the narrowest (segment b) areas passing through the metatarsal heads as estimated from footprints measured by podographs.

is as follows: $b/a = 0$, cavus foot; 0.01-0.29, normal foot; 0.30-0.39, intermediate foot; 0.40-0.44, collapsed foot, and ≥ 0.45 flatfoot (Figure 6) [13].

Clinical evaluation

Studies based on footprint analyses, and radiological evaluations have shown that medial longitudinal arch of the feet continues to develop all along the first 10 years of life [2, 14, 15]. The suggestion that medial ligaments of the foot become harder, and stronger with age which form the arch with time, reveals the futility of using corrective shoes and orthoses. Studies have shown that additional deformities do not develop in flatfooted individuals with aging [16]. Harris and Beath demonstrated that if not associated with comorbidities, collapsed longitudinal arch of the foot did not lead to persistent problems without adversely affecting normal functions of the foot [5, 6].

Even some studies have reported that wearing shoes had harmful effects on the formation of longitudinal arch of the foot [17, 18]. The reason why Hippocrates had not mentioned about flatfoot can be explained by shoe-wearing habits of that time. Rao and Joseph evaluated footprints of 2300 children aged between 4, and 13 years, and indicated that in barefooted children normal medial longitudinal arch formed at a higher frequency, and stated that shoe-wearing habit might adversely effect the development of medial longitudinal arch [18]. Since modifications of shoe design, and sole insoles are ineffective in the treatment of flatfoot [19, 20], the main objective in the treatment of flatfoot should be to convince the patient's relatives that this deformity will resolve with time, and use of orthosis is not necessary.

Physical examination: Generally, children without any complaints are brought to the medical centers by their families. Sometimes, standing for a long time may cause leg, and foot pains. Gait disorders are caused mainly by three factors: problems of stepping inward, and outward (increased femoral anteversion, tibial medial torsion, metatarsus adductus), O and X leg deformities, laming, and limping.

In the presence of contracture of the Achilles tendon, an induration along the Achilles tendon can be palpated while the ankle is in dorsiflexion, the knee in extension, and the foot in inversion. The

child can not walk on his/her heels when requested to do so. Characteristically on lateral radiograms obtained while the patients were pressing against the floor with their feet calcaneus equinus, and plantar flexion of the talus caused by retraction of the Achilles tendon can be seen.

On physical examination laxity of foot ligaments should be evaluated. In cases of general ligamentous laxity, child's hyperextended thumb should touch his/her forearm, and hyperextended fingers can be brought parallel to the back of the hand. Besides genu, and cubital recurvatum should be present. During tiptoe walking, inversion of the heel indicates importance of strengthening plantar, and invertor muscles, however this phenomenon has not been proved yet. If during raising up on tiptoe, inversion of the heel, and formation of a foot arch are not observed, then it is not a case of flexible flatfoot, and mainly the following abnormalities of rigid flatfoot deformity should be investigated:

- Neurological, and myopathic disorders: disorders of muscular weakness (polyomyelitis, peripheral neuropathy); muscular weakness, and contracture of the Achilles tendon (Duchenne muscular dystrophy), calcaneus equinus deformity together with spasticity (cerebral palsy).
- Painful, and restricted hindfoot movements: tarsal coalition, inflammatory arthritis
- Calcaneus equinus together with rocker-bottom deformity: congenital vertical talus
- Pain elicited on pressing over navicular bone: accessory navicular bone or osteochondritis

For the examination of the subtalar joint which is the most important joint in the inversion and eversion of the hindfoot, while the child was laid in the prone position, the knee is brought to 130° flexion, and the foot is held in dorsiflexion to restrict lateral movement of the tibiotalar joint, and evaluation of range of motion (ROM) of only subtalar joint is attempted. Restriction of subtalar joint ROM should suggest especially the presence of tarsal coalition.

Radiological investigations are not necessary for every flatfooted child.

In severe cases or in conditions where the family is dissatisfied, anteroposterior (AP) or lateral radiograms of the foot with the child standing on his/her feet can be obtained. On AP radiograms talo-

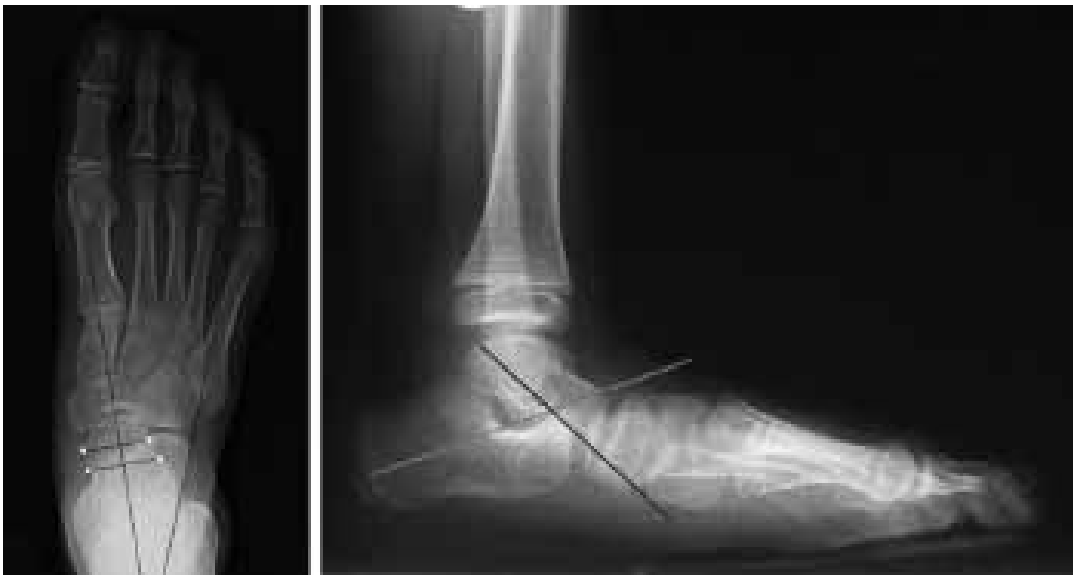

FIGURE 7. Anterior and lateral talocalcaneal angle. On anteroposterior radiograms the angle between the longitudinal axes of the talar, and anterior talocalcaneal joints (Kite angle). It normally measures between 15, and 35 degrees which decreases in varus foot, and increases in hindfoot valgus. On lateral radiograms the angle between longitudinal axes of talus, and calcaneus (plantar surface axis of the calcaneus) is termed as lateral talocalcaneal angle.

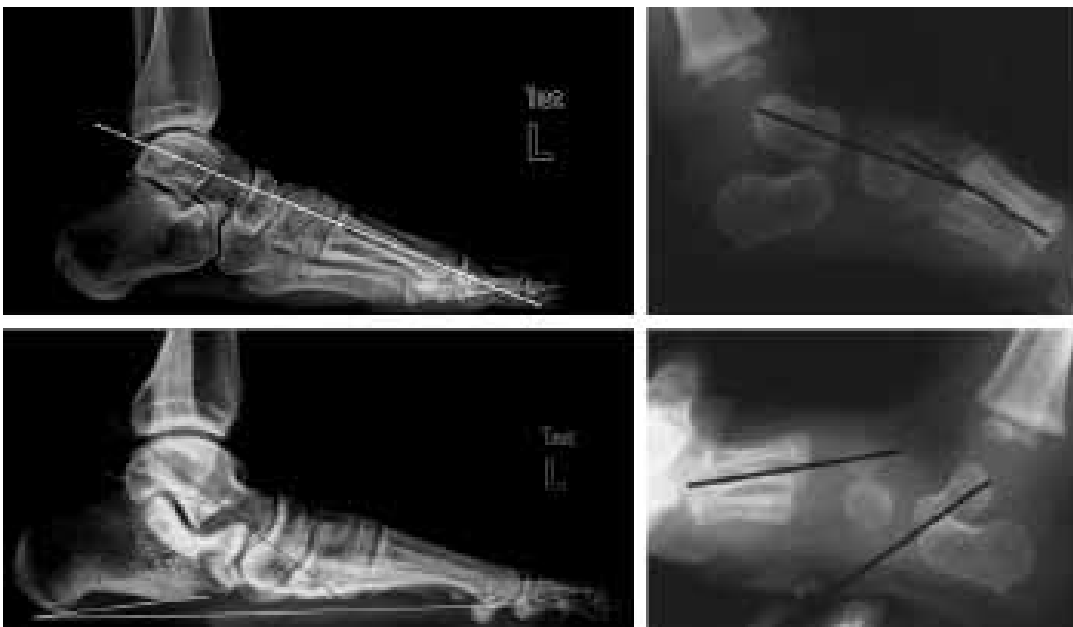

FIGURE 8. Normal, and deformed Meary angle. Lateral radiograms obtained while the patient is standing on foot, the angle between longitudinal axes between the talus, and the first metatars is called Meary angle. Normally these two axes are in alignment.

calcaneal angle should range between 15°, and 35°. An angle over 35° indicates hindfoot valgus. On lateral radiograms, talocalcaneal angle should vary

between 25°, and 50° (Figure 7). Talar-first metatarsal angle (Meary's angle) should not be present. (Figure 8). Talonavicular coverage angle should not

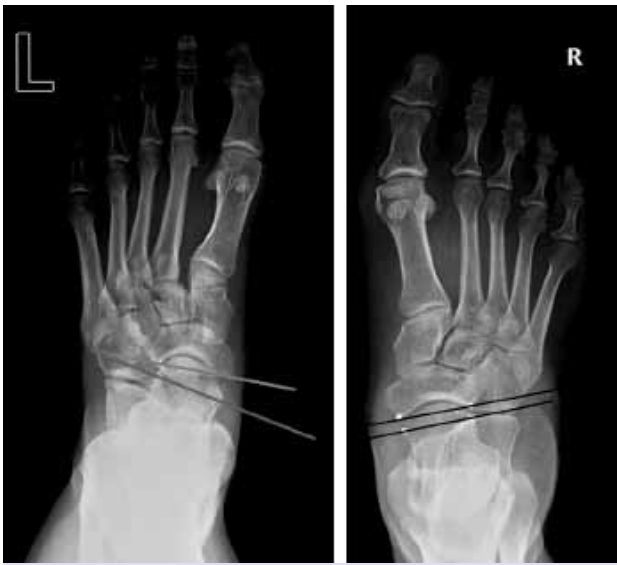

FIGURE 9. Normal, and deformed talonavicular grasping angle. On dorsolateral radiographs obtained while the patient is standing on foot, the angle formed by the bisection of the antero-medial, and the anterior-lateral extremes of the talar head, and the bisection of the proximal articular surface of the navicular. If it is more than 7 degrees, then it indicates presence of a lateral talar subluxation.

exceed 7 degrees (Figure 9). On lateral radiographs of the patients standing on feet with shorter medial longitudinal arches, talus assumes a more vertical, while calcaneus, and metatarses take a more horizontal position. In cases requiring further examinations, on oblique radiographs or Harris radiographs (radiographs of the posterior aspect of the foot obtained from a 45° angle of projection) tarsal coalition, vertical talus, talipes calcaneovalgus, accessory navicular bone can be visualized.

Treatment

Since flatfoot affects mostly our precious children, families with high levels of expectancy for cure most of the time do not satisfy with the treatment which leads to the application of miscellaneous, and extreme surgical, and non-surgical treatment alternatives probably not witnessed in any other pedal deformity.

There is no need to treat flexible flatfoot in children without any complaint.

Controlled studies have demonstrated that foot

orthoses have no effect on the development of medial longitudinal arch of the foot [19, 20]. Interestingly these types of treatment only “cure” parents, rather than the patients.

Then, when, and what type of treatment are necessary? Flatfoot exercises are analyzed in two main headings: weight-bearing, and non-weight-bearing exercises. Exercises performed while seated are non-weight-bearing exercises which include rotating the feet, trying to grip the objects on the floor with foot, holding knees, and feet in extension, forcing the toes for abduction, and adduction, and crossing one foot over the other. Similarly, walking on tiptoes or on outside edge of the foot, standing on tiptoes on an elevated surface, walking with flexed feet are some of the weight-bearing exercises.

If contracture of the Achilles tendon is present, stretching exercises, and Thera-Band exercises should be performed by the parents or if compliant by the children themselves. If tendon stretching exercises are to be performed by the parents, then the method of holding the foot in supination should be taught to the parents so as to prevent forcing the forefoot to dorsiflexion relative to the midfoot. If heel valgus is very pronounced, and ligamentous laxity is present, then tiptoe walking, and gait exercises, and raising on tiptoes can be tried to strengthen tibialis posterior muscle. During these exercises, take care that the feet of the patient are pacing parallel to each other. Firstly heel, then outer edge of the feet, and finally toes should come in contact with the floor. During this heel-toe walking exercises, walking on the medial edge of the feet is not allowed, in addition balanced working of foot muscles is ensured.

In symptomatic patients with painful medial longitudinal arch, and night cramps in addition to stretching, and muscle strengthening exercises, orthosis, and arch support insoles, and inserts can be used. Use of arch support shoes manufactured for this purpose might resolve complaints.

In more persistent cases, use of more rigid orthoses such as UCBL [University of California Biomechanics Laboratory] or Helfet heel cups were found to be helpful in that they corrected talonaviculocuneiform axis, and increased calcaneal dorsiflexion with resultant alleviation of patients' complaints [21, 22].

However, it should not be forgotten that permanent improvement in foot anatomy or medially longitudinal arch could not be demonstrated with any modification of the shoe design or use of orthosis. The most important comparative, and prospective study was published by Wenger [20]. Wenger divided children who were followed up with the indication of flatfoot into four groups as 1) control group without treatment under surveillance, users of 2) corrective orthopedic shoes 3) Helfet heel cups, and 4) UCBL orthoses. At the end of 3 years of follow-up period, any difference between radiologically, and clinically natural course group, and the other 3 groups was not detected [20].

Surgical treatment

Patients whose complaints do not resolve, and couldn't perform their daily activities because of their pain with resultant decline in their quality of life despite conservative treatments are candidates of surgical treatment. In 49-77% of the cases unsatisfactory long-term results have been reported after both soft tissue, and bone surgeries [23, 24]. Since joint fusion induces osteoarthritic changes in adjacent joints, joint separation procedures, extra-articular osteotomies, and soft tissue manipulation, and stretching should be preferably considered. To that end, silicon implantation [arthroereisis] has been defined to prevent development of valgus tilting of the subtalar joint, however long-term outcomes are needed [25, 26]. In cases of Achilles tendon contracture, lengthening, and relaxation procedures should be absolutely performed.

Among conventional methods, subtalar arthrodesis which impairs kinematics of entire hindfoot, and consequently midfoot is not recommended. Triple arthrodesis should be performed as a rescue procedure, if other surgical methods fail, currently, calcaneal osteotomy and lateral column lengthening using tricortical iliac graft appears to be an attractive surgical procedure. On the medial side, talonavicular complex is elevated with its fascia, stretched, and suture-fixed (imbrication). However isolated imbrication is not recommended per se, and it should be performed in combination with lateral column lengthening or calcaneal sliding osteotomies. It should not be forgotten that during medial column shortening procedure, posterior tendon of

the tibialis muscle should be also shortened so as to maintain its support to the medial column.

In conclusion: Flexible flatfoot in children has not a generally acceptable definition, and researches on its miscellaneous treatment alternatives have been continuing. Therefore, the best alternatives seem to involve letting the feet of these children alone, and raising awareness among families on this issue so as to refrain them from resorting to unnecessary applications.

Informed Consent: Written informed consent was obtained from the patient who participated in this study.

Conflict of Interest: No conflict of interest was declared by the authors.

Financial Disclosure: The authors declared that this study has received no financial support.

REFERENCES

1. Staheli LT. Evaluation of planovalgus foot deformities with special reference to the natural history. *J Am Podiatr Med Assoc* 1987;77:2-6. [CrossRef](#)
2. Staheli LT, Chew DE, Corbett M. The longitudinal arch. A survey of eight hundred and eighty-two feet in normal children and adults. *J Bone Joint Surg Am* 1987;69:426-8.
3. Kanatli U, Yetkin H, Bolukbasi S. Evaluation of the transverse metatarsal arch of the foot with gait analysis. *Arch Orthop Trauma Surg* 2003;123:148-50.
4. Wenger D. Flatfoot and children's shoes. In: Wenger D, Rang M, ed. *The art and practice of children's orthopaedics*. New York: Raven Press; 1993:77.
5. Harris RI, Beath T. Hypermobility flat-foot with short tendo achillis. *J Bone Joint Surg Am* 1948;30A:116-40.
6. Harris R, Beath T. *Army foot survey: an investigation of foot ailments in Canadian soldiers*, Ottawa: National Research Council of Canada; 1947:1.
7. Basmajian JV, Stecko G. The role of muscles in arch support of the foot. *J Bone Joint Surg Am* 1963;45:1184-90.
8. Cowan DN, Robinson JR, Jones BH, Polly DW Jr, Berrey BH. Consistency of visual assessments of arch height among clinicians. *Foot Ankle Int* 1994;15:213-7. [CrossRef](#)
9. Huang CK, Kitaoka HB, An KN, Chao EY. Biomechanical evaluation of longitudinal arch stability. *Foot Ankle* 1993;14:353-7.
10. Chippaux C. *Elements d'Anthropologie*. Le Phar: Marseille; 1947.
11. Smirak, J. "Prispevek k problematice ploché nohy u školni a pracijici miádeže." Prague: SPN, 1960.
12. Chen KC, Yeh CJ, Kuo JF, Hsieh CL, Yang SF, Wang CH. Footprint analysis of flatfoot in preschool-aged children. *Eur J Pediatr* 2011;170:611-7. [CrossRef](#)

13. Forriol F, Pascual J. Footprint analysis between three and seven years of age. *Foot Ankle* 1990;11:101-4. [CrossRef](#)
14. MORLEY AJ. Knock-knee in children. *Br Med J* 1957;2:976-9.
15. Vanderwilde R, Staheli LT, Chew DE, Malagon V. Measurements on radiographs of the foot in normal infants and children. *J Bone Joint Surg Am* 1988;70:407-15.
16. Rao UB, Joseph B. The influence of footwear on the prevalence of flat foot. A survey of 2300 children. *J Bone Joint Surg Br* 1992;74:525-7.
17. Sachithanandam V, Joseph B. The influence of footwear on the prevalence of flat foot. A survey of 1846 skeletally mature persons. *J Bone Joint Surg Br* 1995;77:254-7.
18. SIM-FOOK L, HODGSON AR. A comparison of foot forms among the non-shoe and shoe-wearing Chinese population. *J Bone Joint Surg Am* 1958;40-A:1058-62.
19. Gould N, Moreland M, Alvarez R, Trevino S, Fenwick J. Development of the child's arch. *Foot Ankle* 1989;9:241-5. [CrossRef](#)
20. Wenger DR, Mauldin D, Speck G, Morgan D, Lieber RL. Corrective shoes and inserts as treatment for flexible flatfoot in infants and children. *J Bone Joint Surg Am* 1989;71:800-10.
21. Bleck EE, Berzins UJ. Conservative management of pes valgus with plantar flexed talus, flexible. *Clin Orthop Relat Res* 1977;122:85-94.
22. Mereday C, Dolan CM, Lusskin R. Evaluation of the University of California Biomechanics Laboratory shoe insert in "flexible" pes planus. *Clin Orthop Relat Res* 1972;82:45-58.
23. Butte FL. Navicular-cuneiform arthrodesis for flat-foot and end-result study. *J Bone Joint Surg* 1937;19:496.
24. Crego CH Jr, Ford LT. An end-result of various operative procedures for correcting flat feet in children. *J Bone Joint Surg Am* 1952;34:183-95.
25. Addante JB, Chin MW, Loomis JC, Burleigh W, Lucarelli JE. Subtalar joint arthroereisis with SILASTIC silicone sphere: a retrospective study. *J Foot Surg* 1992;31:47-51.
26. Lanham RH Jr. Indications and complications of arthroereisis in hypermobile flatfoot. *J Am Podiatry Assoc* 1979;69:178-85.