

Effect of latanoprost on choroidal thickness in patients with newly diagnosed primary open-angle glaucoma

 Neslihan Buyukmurat,¹  Erdi Karadag,¹  Hanefi Ozbek²

¹Department of Administration, University of Health Sciences, Kartal Dr. Lutfi Kirdar City Hospital, Istanbul, Turkiye

²Department of Medical School Administration, Izmir Bakircay University, Izmir, Turkiye

ABSTRACT

OBJECTIVE: The purpose of this study was to assess the influence of latanoprost on choroidal thickness in patients with newly diagnosed primary open-angle glaucoma using Swept-Source Optical Coherence Tomography (SS-OCT).

METHODS: The retrospective, non-randomized study comprised 40 newly diagnosed primary open-angle glaucoma patients receiving latanoprost therapy (Group 1). Additionally, 40 age- and sex-matched healthy subjects served as the control group (Group 2). Using SS-OCT, measurements of subfoveal, horizontal temporal, and horizontal nasal quadrants choroidal thickness, as well as intraocular pressure (IOP) and retinal nerve fiber layer (RNFL) thickness values, were collected at baseline and after 1 month for both groups.

RESULTS: The mean age was 39.8±4.15 years (range: 18–45 years) in group 1 and 41.67±7.95 years (range: 18–45 years) in group 2 ($p>0.05$). The mean choroidal thickness in the subfoveal area, horizontal temporal quadrant, and horizontal nasal quadrant prior to latanoprost therapy were 263.57±84.23 μm , 233.05±80.08 μm , and 219.52±83.28 μm in the group 1 whereas 278.9±93.88 μm , 243.8±73.37 μm and 209.85±92.92 μm in the group 2. After latanoprost therapy, the mean choroidal thickness in the subfoveal area, horizontal temporal quadrant, and horizontal nasal quadrant changed significantly to 299.77±41.29 μm , 269.9±43.80 μm , and 261.32±45.60 μm in the group 1 ($p=0.02$, $p=0.016$, and $p=0.012$, respectively) (Table 1). However, the mean choroidal thickness in the subfoveal area, horizontal temporal quadrant and horizontal nasal quadrant in group 2 changed not significant and was 279.25±103.37 μm , 246.42±87.07 μm and 203.62±106.74 μm , respectively ($p=0.4$, $p=0.5$ and $p=0.9$, respectively). The mean IOP decreased significantly in group 1 ($p=0.000$) but did not change significantly in group 2 ($p=0.153$). There was no difference in RNFL thickness values at baseline and 1 st month in group 1 and group 2 ($p>0.05$).

CONCLUSION: Topical latanoprost may increase choroidal thickness. Swept Source-OCT may contribute to our understanding of the actions of latanoprost on choroidal thickness.

Keywords: Choroidal thickness; glaucoma; latanoprost; swept source optical coherence tomography.

Cite this article as: Buyukmurat N, Karadag E, Ozbek H. Effect of latanoprost on choroidal thickness in patients with newly diagnosed primary open-angle glaucoma. *North Clin Istanbul* 2024;11(4):271–276.

Prostaglandin analogues (PGAs) are the first choice for the treatment of primary open-angle glaucoma (POAG) due to their effective reduction of intraocular pressure (IOP) with once-daily dosing and their proven efficacy and excellent safety profile [1, 2]. Latanoprost,

an isopropyl ester prodrug of prostaglandin F₂ alpha, is hydrolyzed in the cornea to the biologically active latanoprost acid. It primarily target of latanoprost is prostaglandin F receptors located in the ciliary muscle and iris [3]. PGAs lower intraocular pressure (IOP) by

Received: June 07, 2024

Accepted: June 25, 2024

Online: July 31, 2024



Correspondence: Neslihan BUYUKMURAT, MD. Saglik Bilimleri Universitesi, Kartal Dr. Lutfi Kirdar Sehir Hastanesi, Yonetim Bolumu, Istanbul, Turkiye.

Tel: +90 216 458 30 00 e-mail: neslibuyukmurat@gmail.com

Istanbul Provincial Directorate of Health - Available online at www.northclinist.com

increasing uveoscleral outflow [4, 5]. The choroid contributes to the uveoscleral outflow pathway. Variations in choroidal thickness may be explained by changes in the volume of aqueous humor transported through the ciliary muscle to the choroid. Furthermore, studies have indicated that latanoprost may influence choroidal perfusion in patients with glaucoma [6, 7]. The objective of this study was to assess the impact of latanoprost 0.005% (Xalatan® Pfizer) eyedrops on choroidal thickness. We hypothesized that latanoprost treatment might lead to changes in choroidal thickness.

MATERIALS AND METHODS

This retrospective, non-randomized study was approved by the Istanbul Medipol University Ethics Committee with protocol number 827, dated 27.09.2022. All participants provided written informed consent to participate in the study. The study design adheres to the tenets of the Helsinki Declaration and aligns with the Committee on Publication Ethics (COPE) guidelines. Newly diagnosed patients with open-angle glaucoma also had disc abnormalities according to the European Glaucoma Society (EGS) diagnostic guidelines. However, they had never received hypotensive therapy [8]. Only the right eye was included if both eyes of a participant were fit to be chosen. In the latanoprost group, the right eye of each participant was treated with latanoprost 0.005% (Xalatan® Pfizer) daily at 9 p.m. Each participant underwent a comprehensive ophthalmic examination, including slit-lamp examination, measurement of intraocular pressure (IOP) using applanation tonometry, dilated fundus examination, and optical coherence tomography (OCT) assessments of choroidal thickness (CT) and retinal nerve fiber layer (RNFL) thickness. Optical coherence tomography scans were performed using swept-source OCT (DRI OCT Triton Plus, Topcon, Japan) at two intervals: baseline and 1 month. Scans were performed by the same technician at 9:00 a.m. After pupil dilation (>5 mm), the chorioretinalline mode was used. In cases of suboptimal image quality, remeasurement was performed. Only measurements with a reliability index of 60 or higher according to the OCT device manufacturer's specifications were included. Choroidal thickness was quantified from the outer border of the hyperreflective line (retinal pigment epithelial layer) to the line corresponding to the choroidal-scleral junction, perpendicular to the scan. Measurements were taken from the subfoveal center and from the nasal and temporal quadrants at a horizon-

Highlight key points

- One month of latanoprost treatment increased choroidal thickness in the subfoveal, horizontal temporal and horizontal nasal quadrants.
- It is clinically important that topical latanoprost increases choroidal vascular permeability and impairs choroidal blood flow.
- Short-term latanoprost use did not change RNFL thickness.
- Swept Source Optical Coherence Tomography (SS-OCT) is unique in its ability to non-invasively and objectively examine and measure the choroid *in vivo*.

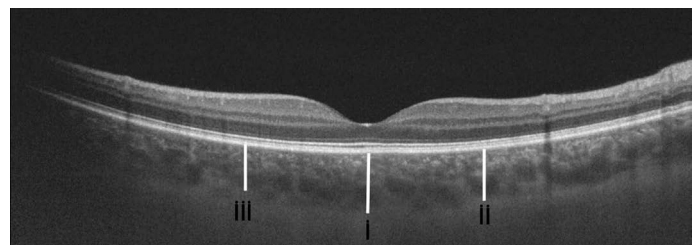


FIGURE 1. A typical choroidal image and the choroidal thickness measurements on OCT scan. i: foveal center, ii: nasal quadrant (1500 μm), iii: temporal quadrant (1500 μm).

tal distance of 1500 μm from the foveal center (Fig. 1). Retinal nerve fiber layer thickness measurements were obtained from the inferior, superior, nasal, and temporal quadrants and total thickness (Fig. 2).

Statistical Analysis

SPSS Statistics 21.0 was used for all statistical tests. (Armonk, New York: IBM Corp.). Forty eyes with an SD of 35 μm for subfoveal choroidal thickness were required to obtain a 95% confidence interval and 80% power. The size of the sample was computed using an alpha error of 0.05 and a beta error of 0.20. The data were proffered as the mean \pm Standard deviation. A two-sample t-test was employed to assess the statistical significance of differences between the control and study groups. A paired t-test was employed to assess the statistical significance of differences in variables between time intervals of latanoprost therapy. A p value of less than 0.05 was considered to indicate a statistically significant result.

RESULTS

Group 1 comprised the 40 eyes of 40 participants (21 females and 19 males), with an average age of 39.8 ± 4.15 years (range: 18–45). Group 2 included the 40 eyes of

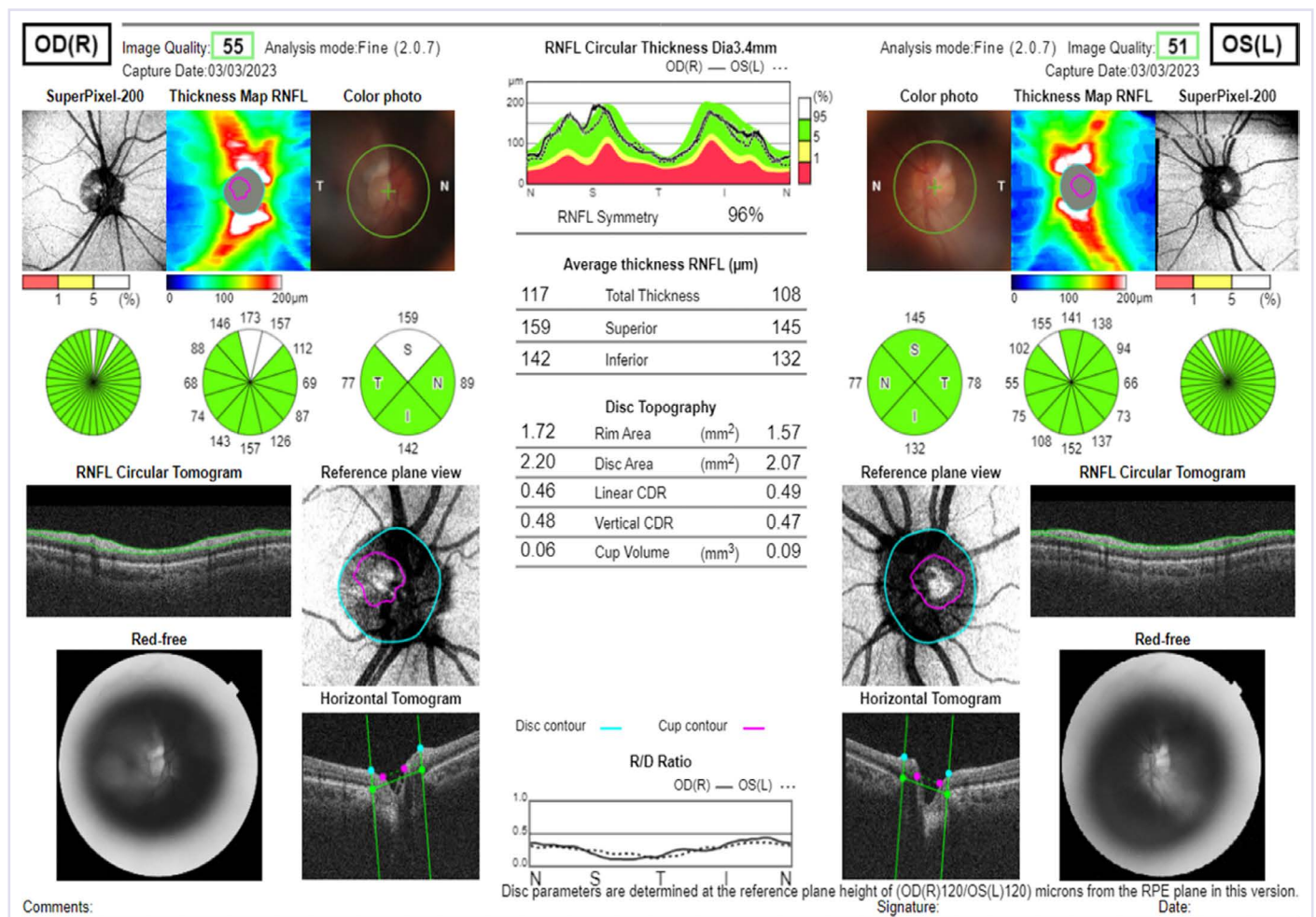


FIGURE 2. A typical retinal nerve fiber layer thickness image and the measurements in a subject.

40 healthy participants (21 males and 19 females), with a mean age of 41.67 ± 7.95 years (range: 18–45). Both groups were not significantly different ($p > 0.05$). The mean choroidal thickness in the subfoveal area, horizontal temporal quadrant and horizontal nasal quadrant at baseline was 263.57 ± 84.23 μm , 233.05 ± 80.08 μm and 219.52 ± 83.28 μm in group 1 (Table 1) and 278.9 ± 93.88 μm , 243.8 ± 73.37 μm and 209.85 ± 92.92 μm in group 2 (Table 2). The mean choroidal thickness in the subfoveal area, horizontal temporal quadrant, and horizontal nasal quadrant at 1 month changed significantly to 299.77 ± 41.29 μm , 269.9 ± 43.80 μm , and 261.32 ± 45.60 μm in the group 1 ($p = 0.02$, $p = 0.016$, and $p = 0.012$, respectively) (Table 1), however, values did not change significantly to 279.25 ± 103.37 μm , 246.42 ± 87.07 μm , and 203.62 ± 106.74 μm in the group 2 ($p = 0.4$, $p = 0.5$, and $p = 0.9$, respectively) (Table 2). The mean IOP at baseline was 25.55 ± 3.19 mmHg in group 1 and 16.2 ± 2.94

TABLE 1. Mean choroidal thickness at baseline and 1st month in the group 1

Choroidal thickness (μm)	Baseline Mean \pm SD	1 st month Mean \pm SD	p*
Subfoveal	263.57 \pm 84.23	299.77 \pm 41.29	0.020
Temporal quadrant	233.05 \pm 80.08	269.9 \pm 43.80	0.016
Nasal quadrant	219.52 \pm 83.28	261.32 \pm 45.60	0.012

SD: Standard deviation; *: $P < 0.05$. The significant p-values ($p < 0.05$) are given in italic and bold type.

mmHg in group 2. At the end of the first month, the mean IOP was 16.7 ± 2.57 mmHg in group 1 and showed a significant decrease ($p = 0.000$), whereas it was 15.87 ± 2.53 mmHg in group 2 and did not change significantly ($p = 0.153$).

TABLE 2. Mean choroidal thickness at baseline and 1st month in the group 2

Choroidal thickness (µm)	Baseline Mean±SD	1 st month Mean±SD	p*
Subfoveal	278.9±93.8	279.25±103.37	0.4
Temporal quadrant	243.8±73.37	246.42±87.07	0.5
Nasal quadrant	209.85±92.92	203.62±106.74	0.9

SD: Standard deviation; *: P<0.05. The significant p-values (p <0.05) are given in italic and bold type.

At baseline, the mean RNFL thicknesses for the total, inferior, superior, nasal and temporal quadrants were 83.4±25.50 µm, 108.95±23.34 µm, 69.82±21.24 µm, and 59.1±15.93 µm in group 1, whereas 105.35±11.41 µm, 138.15±19.59 µm, 130.37±14.17 µm, 80.65±14.87 µm, and 75.52±9.28 µm in group 2. At baseline and 1 month, there were significant differences in RNFL thickness between the two groups for the total, inferior, superior, nasal and temporal quadrants (p=0.000). Mean RNFL thickness did not change significantly between baseline and 1-month visit in either group (p>0.05) (Table 3).

DISCUSSION

The choroid, situated posterior to the uvea, plays a pivotal role in the drainage of aqueous humor from the anterior chamber via the uveoscleral pathway. This accounts for approximately 35% of the total outflow facility in the human eye [9].

In our present study, we hypothesized that the choroid might show increased thickness following the administration of latanoprost. It is possible that this is due to the additional aqueous humor being redirected toward the choroid. The objective of this study was to investigate changes in choroidal thickness following topical administration of latanoprost using the SS-OCT method. The SS-OCT method was employed to investigate the impact of topical administration of latanoprost on choroidal thickness. The results demonstrated a statistically significant increase in choroidal thickness in the subfoveal, horizontal temporal, and horizontal nasal quadrants following one month of latanoprost therapy. This inability to increase may be of clinical significance, as topical latanoprost could potentially elevate choroidal vascular permeability and disrupt choroidal blood flow. Duru et al. [10] reported in their study that there was a statistically meaningful increment in subfoveal choroidal thickness after three months

TABLE 3. Mean retinal nerve fiber layer thickness at baseline and 1st month in the group 1 and group 2

RNFL thickness (µm)	Group 1 (n=40) Mean±SD	Group 2 (n=40) Mean±SD	p*
Total			
Baseline	83.4±25.50	105.35±11.41	0.000
1 st month	84.55±14.15	105.77±10.66	0.000
Inferior quadrant			
Baseline	108.95±23.34	138.15±19.59	0.000
1 st month	108.2±24.12	137.4±18.07	0.000
Superior quadrant			
Baseline	109.02±22.68	130.37±14.17	0.000
1 st month	109.47±29.02	134.52±14.18	0.000
Nasal quadrant			
Baseline	69.82±21.24	80.65±14.87	0.010
1 st month	68.97±21.82	78.35±13.71	0.024
Temporal quadrant			
Baseline	59.1±15.93	75.52±9.28	0.000
1 st month	59.05±13.17	72.6±9.57	0.000

SD: Standard deviation; *: P<0.05; RNFL: Retinal nerve fiber layer. The significant p-values (p<0.05) are given in italic and bold type.

of latanoprost treatment. The observed statistically significant increase may also be clinically relevant as topical latanoprost has been shown to increase choroidal vascular permeability and ruin choroidal blood flow. Artunay et al. [11] documented a case of central serous chorioretinopathy (CSC), which was thought to be possibly related to latanoprost treatment, as many clinical symptoms appeared to improve after discontinuation of latanoprost treatment. If we consider the case of CSC following latanoprost treatment reported by Tufan and Gencer [12], we can say that there is a correlation between the development of CSC and the use of topical latanoprost. Abnormal choroidal circulation, which has been implicated in causing CSC, has also been correlated with thicker choroids. Duru et al. [10] suggested that the increased choroidal vascular permeability induced by topical latanoprost could potentially influence the development of CSC.

Sahinoglu Keskek and Canan [13] conducted another study evaluating choroidal thickness in patients with glaucoma and ocular hypertension, 7 and 30 days after the start of latanoprost treatment. In contrast to our findings, the authors of the aforementioned study reported no significant differences in choroidal thickness after latanoprost treatment. One of the possible reasons for these different

results may be that the sample size used by Sahinoglu Keskek and Canan [13] in their study was smaller compared to other studies. In addition, their use of an OCT device without swept-source technology may have limited their ability to accurately assess choroidal thickness, in contrast to our study, which used an SS-OCT device to accurately assess the retina and choroid. A further study by Okutucu et al. [14] examined the short-term effects of latanoprost treatment on choroidal thickness using Enhanced Depth Imaging (EDI)-OCT. The results showed that there was nothing different in the thickness of the choroid, despite the application of topical latanoprost occurring only 45 minutes prior. The present study is superior to the aforementioned studies due to the utilization of SS-OCT technology.

We can image the Fourier domain in two ways: spectral-domain OCT, abbreviated as SD-OCT, and swept source-domain OCT, abbreviated as SS-OCT [15]. While SS-OCT devices offer a higher scanning speed than SD-OCT, they also provide longer wavelengths. This allows better visualization of deep structures such as lamina cribrosa, choroid, and sclera [16, 17]. Investigation of the choroidal structure is crucial in clinical practice. Swept Source Optical Coherence Tomography (SS-OCT) is unique in its ability to non-invasively and objectively examine and measure the choroid in vivo. [18, 19].

A key feature of glaucoma is the degeneration of retinal ganglion cells and subsequent loss of the RNFL [20]. Thinning of the retinal nerve fiber layer has been observed to occur before the onset of visual function loss and changes in optic disc appearance [21, 22]. In our study, there was no significant change in RNFL thickness values in either group at 1 month. This may be related to the small number of participants in the study and the short follow-up period. In addition, no study was found in the literature that examined changes in RNFL thickness after latanoprost use.

It should be noted that the study was subject to a number of significant limitations. First of all, we would like to point out that in this study we did not evaluate the choroidal vessels and choroidal blood flow with indocyanine green, Doppler imaging or fundus fluorescein angiography. Inclusion of these methods would have allowed us to compare angiographic or ultrasound changes with OCT features. Second, in our study, choroidal thickness images were scored manually, which introduces potential bias. More objective scoring can be achieved using automated software that removes subjective effects. To fully confirm our findings, future studies using automated software are needed. Finally, in our study, participants were not instructed to refrain

from consuming caffeinated or alcoholic beverages prior to measurement. They were not asked to abstain from food or drink before the SS-OCT measurements.

Conclusion

The use of prostaglandin analogs (PGAs) to improve uveoscleral outflow has been demonstrated to result in a reduction in intraocular pressure (IOP). Additionally, these agents have been shown to influence vascular permeability, potentially through the mimicking of vascular endothelial growth factor (VEGF) and vascular permeability factor (VPF) [23, 24]. Results of this clinical trial indicated that, latanoprost has a meaningful effect on choroidal thickness in patients with newly diagnosed primary open-angle glaucoma. To fully understand the long-term effects and potential benefits of latanoprost in treating choroidal thickness in patients with glaucoma, further research and long-term studies are needed. This could potentially lead to improved treatment strategies for the management of glaucoma and its associated complications. SS-OCT is proving to be valuable in choroidal imaging, particularly in patients receiving latanoprost, given its potential side effects. It allows health care professionals to closely monitor changes in choroidal thickness, providing valuable insight into the effects of latanoprost on the choroid over time. By using SS-OCT in the follow-up of glaucoma patients receiving latanoprost, clinicians can better tailor treatment plans and potentially minimize any adverse effects on choroidal thickness. Furthermore, SS-OCT imaging may facilitate a more comprehensive understanding of the long-term effects of latanoprost on choroidal thickness, which may ultimately lead to the development of more effective treatment strategies for individuals diagnosed with primary open-angle glaucoma.

Ethics Committee Approval: The Istanbul Medipol Non-Interventional Clinical Research Ethics Committee granted approval for this study (date: 27.09.2022, number: 827).

Authorship Contributions: Concept – NB, EK, HO; Design – NB, EK, HO; Supervision – NB, EK, HO; Fundings – NB, EK; Materials – NB, EK; Data collection and/or processing – NB, EK; Analysis and/or interpretation – NB, EK; Literature review – NB, EK; Writing – NB, EK; Critical review – NB, EK, HO.

Conflict of Interest: No conflict of interest was declared by the authors.

Use of AI for Writing Assistance: Not declared.

Financial Disclosure: The authors declared that this study has received no financial support.

Peer-review: Externally peer-reviewed.

REFERENCES

1. Konstas AG, Quaranta L, Bozkurt B, Katsanos A, Garcia-Feijoo J, Rossetti L, et al. 24-h efficacy of glaucoma treatment options. *Adv Ther* 2016;33:481–517. [\[CrossRef\]](#)
2. Stewart WC, Konstas AG, Nelson LA, Krufft B. Meta-analysis of 24-hour intraocular pressure studies evaluating the efficacy of glaucoma medicines. *Ophthalmology* 2008;115:1117–22. [\[CrossRef\]](#)
3. Ocklind A. Effect of latanoprost on the extracellular matrix of the ciliary muscle. A study on cultured cells and tissue sections. *Exp Eye Res* 1998;67:179–91. [\[CrossRef\]](#)
4. Toris CB, Camras CB, Yablonski ME. Effects of PhXA41, a new prostaglandin F2 alpha analog, on aqueous humor dynamics in human eyes. *Ophthalmology* 1993;100:1297–304. [\[CrossRef\]](#)
5. Weinreb RN, Toris CB, Gabelt BT, Lindsey JD, Kaufman PL. Effects of prostaglandins on the aqueous humor outflow pathways. *Surv Ophthalmol* 2002;47:S53–64. [\[CrossRef\]](#)
6. Vetrugno M, Cantatore F, Gigante G, Cardia L. Latanoprost 0.005% in POAG: effects on IOP and ocular blood flow. *Acta Ophthalmol Scand Suppl* 1998;227:40–1. [\[CrossRef\]](#)
7. Boltz A, Schmidl D, Weigert G, Lasta M, Pemp B, Resch H, et al. Effect of latanoprost on choroidal blood flow regulation in healthy subjects. *Invest Ophthalmol Vis Sci* 2011;52:4410–5. [\[CrossRef\]](#)
8. European Glaucoma Society. Terminology and Guidelines for Glaucoma (4th edition). Available at: http://www.eugs.org/eng/EGS_guidelines4.asp. Accessed July 1, 2015.
9. Alm A, Nilsson SF. Uveoscleral outflow - a review. *Exp Eye Res* 2009;88:760–8. [\[CrossRef\]](#)
10. Duru Z, Özsaygılı C, Ulusoy DM, Armağan Demirtaş A, Çiçek A, Duru N. Does using topical latanoprost affect subfoveal choroidal thickness? *Cutan Ocul Toxicol* 2019;38:370–4. [\[CrossRef\]](#)
11. Artunay O, Senel A, Sengul A, Rasier R, Bahcecioglu H. Central serous chorioretinopathy associated with topical latanoprost therapy. *Ocul Immunol Inflamm* 2011;19:453–5. [\[CrossRef\]](#)
12. Tufan HA, Gencer B. Central serous chorioretinopathy associated with latanoprost use. *J Retina Vitreous* 2013;21:139–41.
13. Sahinoglu Keskek N, Canan H. Effect of latanoprost on choroidal thickness. *J Glaucoma* 2018;27:635–7. [\[CrossRef\]](#)
14. Okutucu M, Findik H, Arslan MG. Direct and crossover effects of brinzolamide, betaxolol, and latanoprost on choroidal thickness. *Cutan Ocul Toxicol* 2019;38:196–200. [\[CrossRef\]](#)
15. Mrejen S, Spaide RF. Optical coherence tomography: imaging of the choroid and beyond. *Surv Ophthalmol* 2013;58:387–429. [\[CrossRef\]](#)
16. Lee B, Chen S, Moulton EM, Yu Y, Alibhai AY, Mehta N, et al. High-speed, ultrahigh-resolution spectral-domain OCT with extended imaging range using reference arm length matching. *Transl Vis Sci Technol* 2020;9:12. [\[CrossRef\]](#)
17. Schmetterer L, Scholl H, Garhöfer G, Janeschitz-Kriegl L, Corvi F, Sadda SR, et al. Endpoints for clinical trials in ophthalmology. *Prog Retin Eye Res* 2023;97:101160. [\[CrossRef\]](#)
18. Rabiolo A, Fantaguzzi F, Montesano G, Brambati M, Sacconi R, Gelormini F, et al. Comparison of retinal nerve fiber layer and ganglion cell-inner plexiform layer thickness values using spectral-domain and swept-source OCT. *Transl Vis Sci Technol* 2022;11:27. [\[CrossRef\]](#)
19. Michalewska Z, Nawrocki J. Atlas of Swept Source Optical Coherence Tomography. 1st ed. New York: Springer; 2017. [\[CrossRef\]](#)
20. Osborne NN, Melena J, Chidlow G, Wood JP. A hypothesis to explain ganglion cell death caused by vascular insults at the optic nerve head: possible implication for the treatment of glaucoma. *Br J Ophthalmol* 2001;85:1252–9. [\[CrossRef\]](#)
21. Sommer A, Katz J, Quigley HA, Miller NR, Robin AL, Richter RC, et al. Clinically detectable nerve fiber atrophy precedes the onset of glaucomatous field loss. *Arch Ophthalmol* 1991;109:77–83. [\[CrossRef\]](#)
22. Tuulonen A, Airaksinen PJ. Initial glaucomatous optic disk and retinal nerve fiber layer abnormalities and their progression. *Am J Ophthalmol* 1991;111:485–90. [\[CrossRef\]](#)
23. Toris CB, Camras CB, Yablonski ME. Effects of PhXA41, a new prostaglandin F2 alpha analog, on aqueous humor dynamics in human eyes. *Ophthalmology* 1993;100:1297–304. [\[CrossRef\]](#)
24. Martínez A, Sanchez-Salorio M. Predictors for visual field progression and the effects of treatment with dorzolamide 2% or brinzolamide 1% each added to timolol 0.5% in primary open-angle glaucoma. *Acta Ophthalmol* 2010;88:541–52. [\[CrossRef\]](#)