

Diagnostic and prognostic value of F-18 FDG PET/CT in patients with carcinoma of unknown primary

 Nilufer Bicakci

Department of Nuclear Medicine, SBU Samsun Education and Research Hospital, Turkiye

ABSTRACT

OBJECTIVE: Carcinoma of unknown primary (CUP) is inability to detect primary tumor despite all imaging methods with a biopsy-proven tumor metastasis. In the present study, we aimed to investigate the diagnostic and prognostic value of F-18 fluorodeoxyglucose (F-18 FDG) positron emission tomography/computed tomography (PET/CT) in patients with CUP.

METHODS: The patients with a diagnosis of CUP between November 2009 and January 2020 were evaluated retrospectively. A total of 155 patients (96 men and 59 women) were included in the study. Survival rates of the patients were evaluated by Kaplan–Meier and log-rank statistical analysis.

RESULTS: The correctly determined primary tumor by F-18 FDG PET/CT was found in 64 patients (41%) (true positive). F-18 FDG PET CT results were negative (false negative) in determining primary tumor localization in 14 (9%) patients whose had local disease. Of the 155 patients, 66 (42.5%) had true-negative results and 11 (7%) had false-positive results. The sensitivity of 82%, specificity of 86%, and accuracy of 84% were calculated. The SUV_{max} value of the malignant lesion was on average 8.9 (range 3.6–26.1). Kaplan–Meier analysis revealed that the 1-year survival rates were 37.3% in regional disease and 16% in extensive disease (log-rank test, $p=0.021$).

CONCLUSION: F-18 FDG PET/CT is a useful method in the detection of primary tumor in patients with CUP. F-18 FDG PET/CT can be helpful the evaluation of the prognosis by showing the extent of the disease.

Keywords: Carcinoma of unknown primary; extensive metastasized disease; F-18 fluorodeoxyglucose positron emission tomography/computed tomography; localized disease.

Cite this article as: Bicakci N. Diagnostic and prognostic value of F-18 FDG PET/CT in patients with carcinoma of unknown primary. *North Clin Istanbul* 2022;9(4):337–346.

Carcinoma of unknown primary (CUP) is defined as the cases where metastasis has been proven by biopsy, but the primary tumor cannot be detected despite extensive clinical studies [1]. Among the tests used to detect the primary tumor include medical history, physical examination, tumor-specific chemical markers, and radiological imaging such as X-ray, magnetic resonance imaging (MRI), computed tomography (CT) and mammography, scopic interventions (gastroscopy, colonoscopy, and bronchoscopy). CUP has aggressive nature and has a short lifespan between

2 and 10 months [2]. CUP accounts for approximately 0.5–9% of all tumors and the age of onset is around 60 years. CUP ranks 7–8th among cancers diagnosed in the world so it is not rare disease [3]. In CUP, primary tumor can be detected only in 10–35% of patients with conventional imaging methods [4]. Likewise, the primary tumor can be detected only 30% of the patients in the biopsy. There are three main histopathological types; adenocarcinoma, poorly differentiated adenocarcinoma, and undifferentiated adenocarcinoma in CUP and approximately 80% of patients have unfavor-



Received: November 09, 2021 Accepted: December 30, 2021 Online: August 25, 2022

Correspondence: Nilufer BICAKCI, MD. SBU Samsun Egitim ve Arastirma Hastanesi, Nukleer Tip Anabilim Dali, Samsun, Turkiye.
Tel: +90 362 311 15 00 e-mail: niluferbicakci@gmail.com

© Copyright 2022 by Istanbul Provincial Directorate of Health - Available online at www.northclinist.com

able subtypes. Determining the location of the primary tumor increases the probability of tumor-specific treatment, thus helping to prolong the survival [5, 6]. Fluorine-18-2-fluoro-2-deoxy-D-glucose positron emission tomography/CT (F-18 FDG PET/CT) imaging is used routinely in the diagnosis, staging, restaging, and follow-up in malignancies [7]. F-18 FDG PET/CT is valuable imaging modality to detect the primary lesion in 25–80% of patients whose cannot be visualized by conventional imaging methods. F-18 FDG PET/CT detects a primary tumor site in 41% of patients with extracervical metastases (24–63%) [8]. CT and MRI can show only anatomical abnormalities and abnormal contrast enhancements. However, F-18 FDG PET/CT also to gather information about metabolic status of the tumor. As stated in the previous studies, F-18 FDG PET/CT is a useful imaging method for finding the primary site with high precision [9]. On the other hand, some authors indicate that there is no superiority of F-18 FDG PET/CT to radiological methods in terms of primary site detection of CUP [10].

In the present study, we investigated the diagnostic and prognostic value of F-18 FDG PET/CT in patient with CUP who were referred to us with various metastases or clinical suspicion of malignancy.

MATERIALS AND METHODS

Patients

In this retrospective study, patients with a diagnosis of CUP on F-18 FDG PET/CT imaging between November 2009 to January 2020 were evaluated. The study was approved by the SBU Samsun Training and Research Hospital Local Ethics Committee (protocol number: GOKA/2021/3/9).

Patients whose medical records were lacking or who had chemotherapy before F-18 FDG PET/CT imaging were excluded from the study. Finally, 155 patients (96 men and 59 women, age range 18–86 years, mean SD 57 ± 14) were included in the study. In all patients, appropriate conventional diagnostic imaging procedures including ultrasound, MRI, and/or CT had been performed without identification of the primary tumor. One hundred and twenty-five of 155 patients had histopathologically proven metastatic disease with unknown primary origin. Thirty out of 155 patients were recorded as clinical suspicion of malignancy with their medical history (significant weight loss, unknown fever, increased

Highlight key points

- Carcinoma of unknown primary (CUP) is a biopsy-proven tumor metastasis with unidentified primary site despite all routine imaging methods clinical work-up.
- Whole-body F-18 FDG PET/CT is also useful in the detection of additional solid organ metastasis and to determine the extent of metastatic disease. Identification of additional metastasis may provide more effective treatment and prolonged survival in some cases.
- F-18 FDG PET/CT is a useful method in the detection of primary tumor in patients with CUP and it can be helpful the evaluation of the prognosis by showing the extent of the disease.

TABLE 1. The characteristics of 155 patients with carcinoma of unknown primary (n=155)

Characteristics	%
Age	
<60 years	46
≥60 years	53
Sex	
Male	61
Female	38
Location of metastatic foci	
Lymph nodes metastases	42.6
Cervical LN	60.6
Mediastinal LN	15.1
Axillary LN	13.6
Retroperitoneal LN	9
Inguinal LN	2
Solid organs and others	57.4
Bone metastases	34.8
Liver metastases	29.2
Brain metastases	11.2
Lung metastases	4.49
Breast metastases	1.12
Bone marrow metastases	1.12
Ethmoid sinus metastases	1.12
Muscle metastases	3.37
Omentum metastases	5.6
Malignant pleural effusion	5.6
Malignant ascites	2.2

LN: Lymph node.

tumor marker, etc.). The clinical characteristics of the patients are shown in Table 1. The histopathological data were accepted as the gold standard.

TABLE 2. The histopathologic characteristic of true-positive patients

Patients (n=64)	%
Adenocarcinoma*	59.3
Squamous cell carcinoma	4.6
Lymphoma	12.5
Extramedullary acute myeloid leukemia/myeloid sarcoma	1.5
Epidermoid and invasive ductal breast cancer	10.9
Nasopharynx and oropharynx cancer	4.6
Renal cell cancer	1.5
Ovarian cancer	3.1
Malign melanoma	1.5

SD: Standard deviation.

Fluorodeoxyglucose PET/CT Imaging

All patients underwent F-18 FDG PET/CT imaging, after 6–8 h of fasting. Blood glucose level was measured in each patient before the FDG injection. Oral contrast was given to each patient before scanning. Sixty minutes after the 250–370 MBq of F-18 FDG intravenous administration, position was given to the patients as a supine position on the table. PET/CT imaging was taken from skull to the upper thighs. F-18 FDG imaging was performed with time of flight (TOF) PET/16-section CT (Philips Gemini TF) and the PET detector crystal material was LYSO. The CT transmission scan was recorded with 140 kVp and 110 mA and 5 mm slice thickness. The maximum standard uptake values (SUV_{max}) were calculated. Primary tumor assessment on the PET images was performed by the detection of focally increased glucose (F-18 FDG) metabolism with a $SUV_{max} \geq 2.5$. Malignancy diagnosis is not only based on increased F-18 FDG findings but also these lesions were also accepted as malignant by evaluating of patients' medical history, physical examination findings, laboratory parameters, and the correlation with the non-diagnostic CT images which were concurrently obtained with a PET study. The rate of primary tumor detection was given with the PET/CT and histopathological results together (Table 2).

Data Analysis

The histopathologically confirmed primary site of malignancy was accepted as true-positive (TP) only. The finding which was not confirmed histopathologically was

regarded as false-positive (FP) diagnosis. The multiple hypermetabolic lesions may be found. However, they could not have been differentiated neither in F-18 FDG PET/CT nor in histopathology. In this situation, they were classified as true negative (TN). When the site of primary was not identified by F-18 FDG PET/CT but proved in histopathologic examination, it was regarded as false negative (FN).

Statistical Analysis

We compared the 1-year survival of CUP patients with multiple metastatic diseases and those with local disease. For statistical analysis, IBM Statistical Package for the Social Sciences (SPSS) for Windows (Version 22.0, Armonk, NY: IBM Corp.) program was used. The Kaplan–Meier test was used for survival analysis. The log-rank test was applied for comparison of the survivors.

The sensitivity, specificity, and accuracy of F-18 FDG PET/CT in detecting primary tumor were calculated using the following standard statistical formula: Sensitivity = $TP / (TP + FN)$, specificity = $TN / (TN + FP)$, and accuracy = $(TP + TN) / (TP + FP + TN + FN)$.

RESULTS

One hundred and fifty-five patients with CUP aged 18–86 years (mean \pm SD: 57 ± 14) were included in the study. Ninety-six were male and 59 were female. One hundred and twenty-five of 155 patients had histopathologically proven metastatic disease with unknown primary site. F-18 FDG PET/CT was able to detect a biopsy-proven primary tumor in 49 of 125 patients: Lung (n: 25), colon (n: 4), breast (n: 4), pancreas (n: 3), ovary (n: 2), nasopharynx (n: 2), and the others (n: 10). F-18 FDG PET/CT identified focal FDG uptake indicative of a primary tumor in nine of 125 which were not confirmed histopathologically. Primary tumor was not detected during the follow-up five of 125 patients with negative F-18 FDG PET/CT. Thirty out of 155 patients were recorded as clinical suspicion of malignancy with their medical history and laboratory examinations (profound weight loss, unknown fever, increased tumor marker, etc.). F-18 FDG PET/CT was able to detect a biopsy-proven primary tumor in 15 of 30 those patients including six non-small-cell lung cancers, four diffuse large B-cell lymphomas, three invasive ductal cancers, one small-cell lung cancer, and one gastric adenocarcinoma. Primary tumor was not detected in four of 30 patients in

TABLE 3. Details of the F-18 FDG PET/CT findings of the 64 patients with true-positive results

Age (years)	Sex	Metastatic localization	Metastatic histology/ radiologic metastases	F-18 FDG PET/CT diagnosis	Histopathology of lesion	Accuracy
49	M	Liver	Malign epithelial tumor metastasis	Lung cancer	NSCLC	TP
62	F	Clinical suspicion	-	Breast cancer	Invasive ductal breast cancer	TP
29	M	Clinical suspicion	-	Lymphoma	DLBCL	TP
43	M	Liver	Malign epithelial tumor	Lung cancer	NSCLC	TP
76	M	Clinical suspicion	-	Breast cancer	Invasive ductal breast cancer	TP
49	M	Clinical suspicion	-	Lymphoma	DLBCL	TP
73	F	Clinical suspicion	-	Lymphoma	DLBCL	TP
61	M	Brain	-	Lung cancer	NSCLC	TP
53	M	Brain	Adenocarcinoma metastasis	Lung cancer	NSCLC	TP
54	F	Lung	Adenocarcinoma metastasis	Colon cancer	Colon cancer	TP
57	F	Lung	Adenocarcinoma metastasis	Colon cancer	Colon cancer	TP
52	F	Mediastinal LN	Metastatic cancer	Lung cancer	NSCLC	TP
58	M	Muscle	Malign tumor	Renal cancer	Renal cell Ca	TP
43	M	Brain	Adenocarcinoma metastasis	Lung cancer	NSCLC	TP
77	M	Liver	Adenocarcinoma metastasis	Lung+colon cancer	Lung+colon cancer	TP
75	M	Brain	-	Lung cancer	NSCLC	TP
44	M	Brain	-	Lung cancer	NSCLC	TP
56	M	Inguinal LN	Malign tumor	Lymphoma	DLBCL	TP
39	M	Cervical LN	Malign epithelial tumor	Oropharynx cancer	Oropharynx cancer	TP
60	M	Cervical LN	Malign epithelial tumor	Nasopharynx cancer	Nasopharynx cancer	TP
65	M	Clinical suspicion	-	Lung cancer	NSCLC	TP
68	M	Brain	-	Lung cancer	SCLC	TP
64	M	Clinical suspicion	-	Lung cancer	SCLC	TP
60	M	Cervical LN	Adenocarcinoma metastasis	Lung cancer	NSCLC	TP
63	M	Bone	Adenocarcinoma metastasis	Lung cancer	NSCLC	TP
79	K	Clinical suspicion	-	Gastric cancer	Gastric adenocarcinoma	TP
54	M	Cervical LN	Malign tumor	Lymphoma	DLBCL	TP
78	M	Clinical suspicion	-	Lung cancer	NSCLC	TP
73	M	Cervical LN	Metastatic cancer	Lung cancer	NSCLC	TP
50	M	Clinical suspicion	-	Lymphoma	DLBCL	TP
28	M	Pleural liquid	Adenocarcinoma metastasis	Lung cancer	NSCLC	TP
35	F	Liver	Malign epithelial tumor	Breast cancer	Invasive ductal breast cancer	TP
74	F	Liver	Adenocarcinoma metastasis	Colon cancer	Colon cancer	TP

TABLE 3 (CONT.). Details of the F-18 FDG PET/CT findings of the 64 patients with true-positive results

Age (years)	Sex	Metastatic localization	Metastatic histology/radiologic metastases	F-18 FDG PET/CT diagnosis	Histopathology of lesion	Accuracy
76	M	Brain	-	Lung cancer	NSCLC	TP
72	F	Liver	Malign epithelial tumor	Breast cancer	Invasive ductal breast cancer	TP
63	F	Clinical suspicion	-	Breast cancer	Invasive ductal breast cancer	TP
41	M	Liver	Adenocarcinoma metastasis	Colon cancer	Colon cancer	TP
77	F	Bone	Malign epithelial tumor	Breast cancer	Epidermoid breast cancer	TP
65	F	Peritoneal liquid	Malign epithelial tumor	Over cancer	Ovarian cancer	TP
56	M	Lung	-	Pancreatic cancer	Pancreatic adenocarcinoma	TP
62	F	Pleural liquid	Poor diferansiye karsinom infiltrasyonu	Lung cancer	NSCLC	TP
58	M	Brain	-	Lung cancer	NSCLC	TP
72	M	Pleural liquid	Adenocarcinoma metastasis	Lung cancer	NSCLC	TP
73	M	Cervical LN	Malign epithelial tumor	Nasopharynx cancer	Nasopharynx cancer	TP
55	M	Bone	Adenocarcinoma metastasis	Lung cancer	NSCLC	TP
75	M	Bone	Adenocarcinoma metastasis	Lung cancer	NSCLC	TP
57	M	Bone	Adenocarcinoma metastasis	Lung cancer	NSCLC	TP
45	M	Lung	-	Lung cancer	NSCLC	TP
24	M	Sphenoid sinus	Bilateral fungal sinusitis	Sphenoid sinus cancer	Extramedullary acute myeloid leukemia/myeloid sarcoma	TP
74	F	Cervical LN	-	Left infraorbital skin cancer	Malign melanoma	TP
26	F	Cervical LN	Malign tumor	Lymphoma	Hodgkin lymphoma, nodular sclerosis	TP
59	F	Liver	Adenocarcinoma metastasis	Pancreatic head cancer	Pancreatic adenocarcinoma	TP
86	M	Clinical suspicion	-	Lung cancer	NSCLC	TP
48	M	Pleural liquid	Adenocarcinoma metastasis	Lung cancer	NSCLC	TP
69	F	Liver	Adenocarcinoma metastasis	Pancreatic head cancer	Pancreatic adenocarcinoma	TP
45	F	Cervical LN	Malign tumor	Lymphoma	Hodgkin lymphoma, nodular sclerosis	TP
65	F	Peritoneal liquid	Adenocarcinoma metastasis	Over cancer	Ovarian cancer	TP
62	M	Clinical suspicion	-	Lung cancer	NSCLC	TP
61	M	Clinical suspicion	-	Lung cancer	NSCLC	TP
65	M	Brain	-	Lung cancer	NSCLC	TP
74	F	Bone	Malign epithelial tumor	Breast cancer	Epidermoid breast cancer	TP
64	M	Pleural liquid	Malign tumor	Lung cancer	SCLC	TP
57	M	Clinical suspicion	-	Lung cancer	NSCLC	TP
49	M	Brain	Adenocarcinoma metastasis	Lung cancer	NSCLC	TP

LN: Lymph node; NSCLC: Non-small-cell lung cancer; SCLC: Small-cell lung cancer; DLBCL: Diffuse large cell B lymphoma; TP: True positive.

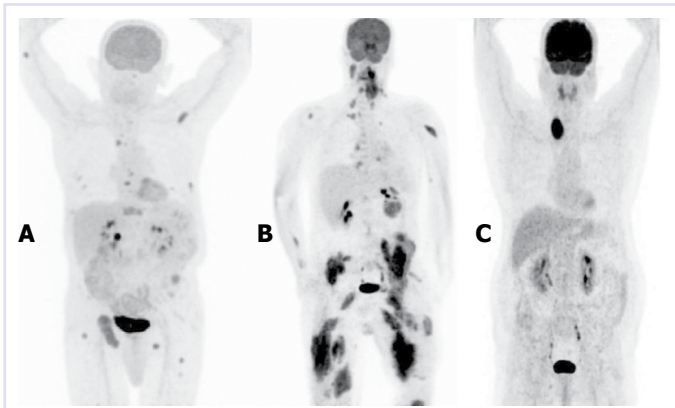


FIGURE 1. (A) A 66-year-old male patient MIP F-18 FDG PET/CT image with carcinoma of unknown primary. Increased accumulations of F-18 FDG were present in metastatic lesions with multiple and focal lytic-weighted lesions in the skeletal system (SUV_{max} : 3.9–5.1). **(B)** A 24-year-old male patient who was diagnosed with chronic invasive fungal sinusitis in sphenoid sinuses on CT and referred to our clinic due to clinical complaints. Hypermetabolic involvement consistent with malignancy in sphenoid sinuses (SUV_{max} : 13.2) and widespread metastatic muscle involvement were detected in MIP F-18 FDG PET/CT images, and histopathologic diagnosis was reported as extramedullary acute myeloid leukemia/myeloid sarcoma. **(C)** A 61-year-old male patient with cervical lymph node metastases. Metastatic histology was adenocarcinoma metastases. In the MIP F-18 FDG PET/CT image, there was a hypodense nodule of 4x3 cm in size showing increased F-18 FDG accumulation in the right thyroid lobe (SUV_{max} : 14.2). Histopathological evaluation of the patient for whom we recommended histopathological examination for thyroid cancer was reported as a benign nodule.

F-18 FDG PET/CT. In two of 30 patients, F-18 FDG PET/CT identified focal FDG uptake in lung. However, these results of F-18 FDG PET/CT were not confirmed histopathologically. F-18 FDG PET/CT was unable to identify the primary tumor in nine of 30 patients which had histopathologically proven primary malignancy.

TP Results

Primary tumors were correctly detected in 64 of 155 patients by F-18 FDG PET/CT whole-body imaging (44 males and 20 females). The 64 patients were aged between 24 and 79 years (Fig. 1). Primary tumors were confirmed histopathologically. The lung carcinoma was the most common detected tumor in our patients and all the primary tumor diagnosis are shown in Table 3.

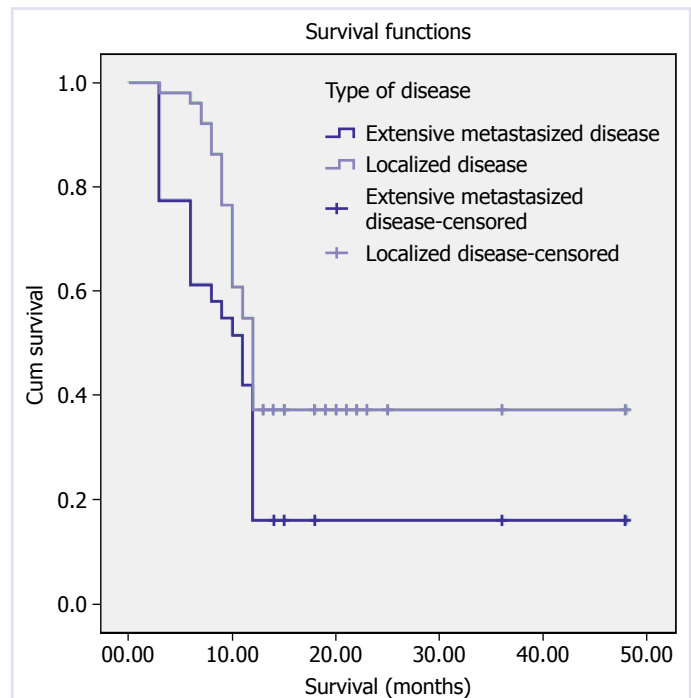


FIGURE 2. Survival analysis.

FP Results

F-18 FDG PET/CT identified focal FDG uptake indicative of a primary tumor in 11 patients (Fig. 1). However, positive results of F-18 FDG PET/CT were not confirmed histologically or identified during the follow-up (Table 4).

TN Results

Primary tumors could not be detected during the follow-up in 66 patients with F-18 FDG PET/CT (Fig. 1).

FN Results

Primary tumor was not detected during the follow-up of 14 patients with negative F-18 FDG PET/CT (Table 5).

Diagnostic Values of F-18 FDG PET/CT in CUP

The sensitivity, specificity, and accuracy of F-18 FDG PET/CT in the detection of primary tumor site were 82%, 86%, and 84%, respectively. The median SUV_{max} of the lesions with maximum uptake in patients with remaining malignant lesions on F-18 FDG PET/CT was 8.9 (range, 3.6–26.1). The 1-year survival rates were 37.3% in locoregional disease, 16% in the multiple metastatic disease on F-18 FDG PET/CT by Kaplan–Meier analysis (log-rank test, $p=0.021$) (Fig. 2).

TABLE 4. Totally 11 F-18 FDG PET/CT false-positive (FP) results with clinical and histopathological findings

Age (years)	Sex	Metastatic localization	Metastatic histology	F-18 FDG PET/CT diagnosis	Histopathology of lesion	Accuracy
56	F	Cervical LN	Adenocarcinoma metastasis	Thyroid cancer	Benign nodule	FP
45	F	Cervical LN	Adenocarcinoma metastasis	Thyroid cancer	Benign nodule	FP
61	F	Cervical LN	Adenocarcinoma metastasis	Thyroid cancer	Benign nodule	FP
67	M	Cervical LN	Adenocarcinoma metastasis	Thyroid cancer	Benign nodule	FP
18	F	Clinical suspicion	–	Colon cancer	Polyp	FP
59	F	Inguinal LN	Adenocarcinoma metastasis	Endometrial cancer	Myoma uteri	FP
59	M	Cervical LN	Adenocarcinoma metastasis	Colon cancer	Polyp	FP
85	F	Cervical LN	Adenocarcinoma metastasis	Thyroid cancer	Benign nodule	FP
61	M	Clinical suspicion	–	Lung cancer	Lung inflammation	FP
73	M	Cervical LN	Adenocarcinoma metastasis	Lung cancer	Lung inflammation	FP
54	F	Liver	Adenocarcinoma metastasis	Sigmoid cancer	Diverticulitis	FP

LN: Lymph node.

TABLE 5. Totally 14 F-18 FDG PET/CT false-negative (FN) results with clinical and histopathological findings

Age (years)	Sex	Metastatic localization	Metastatic histology	F-18 FDG PET/CT diagnosis	Histopathology of lesion	Accuracy
57	F	Clinical suspicion	–	Lymphatic metastasis	Multiple myeloma	FN
50	M	Cervical LN	Epithelial cancer metastasis	Lymphatic metastasis	Papillary thyroid cancer	FN
51	M	Clinical suspicion	–	Generalized disease	Prostatic cancer	FN
65	F	Clinical suspicion	–	Lymphatic metastasis	Multiple myeloma	FN
54	M	Cervical LN	Epithelial cancer metastasis	Lymphatic metastasis	Papillary thyroid cancer	FN
48	M	Clinical suspicion	–	Generalized disease	Prostatic cancer	FN
60	M	Cervical LN	–	Lymphatic metastasis	Prostatic cancer	FN
60	M	Clinical suspicion	–	Normal	Chronic lymphocytic leukemia	FN
50	F	Clinical suspicion	–	Bone metastasis	Low-grade B-cell NHL	FN
55	M	Clinical suspicion	–	Generalized disease	DLBCL	FN
64	F	Clinical suspicion	–	Generalized disease	DLBCL	FN
21	F	Clinical suspicion	–	Generalized disease	DLBCL	FN
29	M	Cervical LN	Epithelial cancer metastasis	Lymphatic metastasis	Papillary thyroid cancer	FN
70	M	Clinical suspicion	–	Normal	Chronic lymphocytic leukemia	FN

LN: Lymph node; DLBCL: Diffuse large cell B lymphoma.

DISCUSSION

The subject of this study is patients with cancer of unknown primary (CUP) who referred our clinic with various site lesions suspected of cancer metastasis or clinical suspicion. Our results demonstrated that F-18 FDG PET/CT has beneficial role in detecting of primary site of tumor and additional metastasis. F-18 FDG PET/CT can also contribute to the evaluation of the prognosis.

Nowadays, CT and MR are routinely used imaging methods in the detection and follow-up of tumors. The main advantage of these methods is the cross-sectional images of the whole body which is also especially important in patients with CUP. However, the detection of only structural abnormalities and pathological contrast enhancements are the main limitations of CT and MRI. In some cases, tumor cannot be detected such as very small lesions or non-enhancing lesions. One of the main characteristics of primary tumor is too small to be detected in many patients with CUP [1, 11]. In addition, metabolic changes can occur without accompanying anatomical pathologies and cannot be showed by conventional imaging modalities. Therefore, CT and MRI may be insufficient and limited to the detection of CUP with low sensitivity [12].

The reasons why the most primary tumors cannot be detected in CUP are still unclear. There are some suggestions that spontaneous disappearance (angiogenetic) after metastasis, destruction of the primary tumor by immune system-related causes, so tiny tumor to detect by imaging methods or the necrotic tumor on the intestinal wall is removed through the gastrointestinal tract [1, 11].

FDG is a very suitable radiotracer for PET imaging due to increase in glucose metabolism in most cancer types (Warburg effect) [13]. F-18 FDG PET/CT modality can identify abnormal metabolic properties of the structures.

It was recently reported that F-18 FDG PET/CT is superior to CT and MRI imaging in the detection of CUP. In one study, while CT alone was demonstrated to identify the primary site only in 8 patients (18%), on the other hand, F-18 FDG PET/CT was able to detect the primary site in 15 patients (33%) [14]. In our study, F-18 FDG PET/CT detected primary tumors in 64 of 155 patients (41.2%).

In the study of Han et al. [12], sensitivity, specificity, and accuracy of F-18 FDG PET/CT were noted as 91.5%, 85.2%, and 88.3%, respectively. These results

were lower in a study of Cengiz et al. [15] as 84%, 78%, and 82%. In our study, we detected the sensitivity, specificity rates, and accuracy of F-18 FDG PET/CT of primary tumor that 82%, 86%, and 84%, respectively.

F-18 FDG PET/CT whole-body imaging is not only could detect the primary site but also present the extent of metastatic disease. Accordingly, F-18 FDG PET/CT prevents further imaging and invasive procedures and provides to start faster suitable therapy [16].

Lung, nasopharynx, oropharyngeal, and pancreatic cancer were declared to be most common primary tumors in patients with CUP [15]. Autopsy studies also showed that lung and pancreatic cancer are also the most common primary tumor [17]. In our study, the most common sites for primary tumors were lung (51%), lymphoma (12.5%), and colon (7.8%). In addition, we were able to localize carcinoma of ovarian, nasopharyngeal, oropharyngeal, breast (invasive and epidermoid), gastric, pancreatic, renal cell, and extramedullary acute myeloid leukemia and malign melanoma.

The most often reported locations of false-positive results in F-18 FDG PET/CT imaging were the lung and the oropharynx (15%) [18]. The cause of that may be FDG uptake in benign conditions with increased glycolysis or high physiological FDG uptake. Unlikely in our study, two out of the 11 false-positive results were detected in the lung. However, the thyroid was the most common site in five patients of false-positive results. FDG uptake in thyroid carcinomas as well as thyroiditis, follicular adenomas, or nodular goiters may be the cause of this result [19]. Other false-positive results occurred in the abdomen. We supported that the combination of functional and anatomical imaging (positron emission tomography and computerized tomography scans) should reduce the rate of false-positive diagnosis.

In our study, the primary tumor could not be detected in 80 patients (51.6%). Primary tumors were detected histopathologically alone in 14 of 155 (9%) patients and it was considered as FN. Breast cancer was the most common cause of false-negative F-18 FDG PET/CT results (27%) [20]. It was because of the inability of F-18 FDG PET/CT to show lesions smaller than <1.0 cm and low-grade lesions with decreased or no FDG uptake. However, false-negative F-18 FDG PET/CT results of our study were prostate cancer, low-grade lymphomas, and head-and-neck cancers. Interestingly, we did not detect breast tumor in the present study. We suggest that our FN results may be due to the low signal-to-noise ra-

tio, low tumor differentiation, or low spatial resolution of the PET system for the detecting small lesions.

Yapar et al. [4] showed that lymph node metastasis was localized in 30 patients of 94 patients (41%) and metastatic localization was most often detected in cervical lymph nodes in 21 (70%) of those patients. Park et al. [21] detected that lymph nodes metastasis in 11 patients with the most frequent metastatic localization was in the cervical lymph nodes in series with 20 patients. Yu et al. [7] detected lymph node metastasis in 330 of 449 patients and determined the metastatic localizations as cervical (37.6%), supraclavicular (12.9%), axillary (10.9%), mediastinal (2.7%), and retroperitoneal (2.2%), respectively. In 66 patients of 155 patients had lymph nodes metastases (42.6%) in our study group. Similarly, we found that 40 (60.6%) had cervical, 10 (15.1%) mediastinal, 9 (13.6%) axillary, 6 (9%) retroperitoneal, and 1 (2%) inguinal lymph node metastasis. Whole-body F-18 FDG PET/CT is also useful in the detection of additional solid organ metastasis and determination of the extent of metastatic disease [1]. Identification of additional metastasis may provide more effective treatment and prolonged survival in some cases. We also detected other solid organ metastases in 82 (52.9%) of 155 patients.

F-18 FDG PET/CT can detect second primary tumors [22]. We also detected second primary tumor in one patient. The primary tumor located in the lung, and additionally, we identified a second primary tumor in the colon in F-18 FDG PET/CT imaging.

High SUV_{max} and F-18 FDG uptake pattern on PET/CT scan are considered an important parameter for locating the primary tumor. The SUV-based quantitative analysis of the hypermetabolic lesions is very useful to make difference between benign from malignant tumors. At present, a maximum SUV of 2.5 is a widely accepted standard threshold in the diagnosis of the malignancy [23]. In our study, the SUV_{max} of the lesion with maximum uptake in patients with remaining malignant lesions on F-18 FDG PET/CT was in the median of 8.9 (range, 3.6–26.1).

Unlike CT and MRI, F-18 FDG PET/CT provides high lesion-to-background contrast. This characteristic makes F-18 FDG PET/CT a potentially more sensitive imaging modality in detection of primary sites and metastasis [24]. On the other hand, in a prospective study, it was found that there were no significant differences between of the imaging methods of F-18 FDG PET/CT and CT regarding sensitivity, specificity, and accuracy [10]. In this prospective study, TP primary tumor

sites identified 38 (28.1%) in F-18 FDG PET/CT and 43 (31.9%) in CT. In addition, whole-body MR imaging may be alternative to F-18 FDG PET/CT. There is no potentially harmful radiotracer in MR and MR contrast agents are more preferred compared CT with iodinated contrast [25]. However, in the literature, there are not enough reports on the diagnostic competency of whole-body MRI in detecting of CUP [26].

Conclusion

Whole-body F-18 FDG PET/CT imaging is both non-invasive and sensitive modality allowing for the detection of a primary tumors and additional metastasis in patients with CUP. Hence, F-18 FDG PET/CT is also useful helping in the decision of the therapeutic approach. We suggest that F-18 FDG PET/CT is convenient whole-body imaging modality in patients with CUP for diagnostic and prognostic evaluation.

Ethics Committee Approval: The Samsun Training and Research Hospital Clinical Research Ethics Committee granted approval for this study (date: 10.02.2021, number: 2021/3/9).

Conflict of Interest: No conflict of interest was declared by the author.

Financial Disclosure: The author declared that this study has received no financial support.

REFERENCES

1. Kwee TC, Basu S, Cheng G, Alavi A. FDG PET/CT in carcinoma of unknown primary. *Eur J Nucl Med Mol Imaging* 2010;37:635–44.
2. Rassy E, Pavlidis N. The currently declining incidence of cancer of unknown primary. *Cancer Epidemiol* 2019;61:139–41. [CrossRef]
3. Pawaskar AS, Basu S. Role of 2-Fluoro-2-deoxyglucose PET/Computed Tomography in carcinoma of unknown primary. *PET Clin* 2015;10:297–310. [CrossRef]
4. Yapar Z, Kibar M, Yapar AF, Paydas S, Reyhan M, Kara O, et al. The value of 18F-fluorodeoxyglucose positron emission tomography/computed tomography in carcinoma of an unknown primary: diagnosis and follow-up. *Nucl Med Commun*. 2010;31:59–66. [CrossRef]
5. Kolesnikov-Gauthier H, Levy E, Merlet P, Kirova J, Syrota A, Carpentier P, et al. FDG PET in patients with cancer of an unknown primary. *Nucl Med Commun* 2005;26:1059–66. [CrossRef]
6. Pavlidis N, Fizazi K. Cancer of unknown primary (CUP). *Crit Rev Oncol Hematol* 2005;54:243–50. [CrossRef]
7. Yu X, Li X, Song X, Dai D, Zhu L, Zhu Y, et al. Advantages and disadvantages of F-18 fluorodeoxyglucose positron emission tomography/computed tomography in carcinoma of unknown primary. *Oncol Lett* 2016;12:3785–92. [CrossRef]
8. Moller AK, Loft A, Berthelsen AK, Damgaard Pedersen K, Graff J, Christensen CB, et al. 18F-FDG PET/CT as a diagnostic tool in patients with extracervical carcinoma of unknown primary site: a literature review. *Oncologist* 2011;16:445–51. [CrossRef]

9. Breuer N, Behrendt FF, Heinzel A, Mottaghy FM, Palmowski M, Verburg FA. Prognostic relevance of (18)F-FDG PET/CT in carcinoma of unknown primary. *Clin Nucl Med* 2014;39:131–5. [\[CrossRef\]](#)
10. Noij DP, Martens RM, Zwezerijnen B, Koopman T, de Bree R, Hoekstra OS, et al. Diagnostic value of diffusion-weighted imaging and 18F-FDG-PET/CT for the detection of unknown primary head and neck cancer in patients presenting with cervical metastasis. *Eur J Radiol* 2018;107:20–5. [\[CrossRef\]](#)
11. Pavlidis N, Fizazi K. Carcinoma of unknown primary (CUP). *Crit Rev Oncol Hematol* 2009;69:271–8. [\[CrossRef\]](#)
12. Han A, Xue J, Hu M, Zheng J, Wang X. Clinical value of 18F-FDG PET-CT in detecting primary tumor for patients with carcinoma of unknown primary. *Cancer Epidemiol* 2012;36:470–5. [\[CrossRef\]](#)
13. Rohren EM, Turkington TG, Coleman RE. Clinical applications of PET in oncology. *Radiology* 2004;231:305–32. [\[CrossRef\]](#)
14. Gutzeit A, Antoch G, Kühl H, Egelhof T, Fischer M, Hauth E, et al. Unknown primary tumors: detection with dual-modality PET/CT--initial experience. *Radiology* 2005;234:227–34. [\[CrossRef\]](#)
15. Cengiz A, Göksel S, Yürekli Y. Diagnostic Value of 18F-FDG PET/CT in patients with carcinoma of unknown primary. *Mol Imaging Radionucl Ther* 2018;27:126–32. [\[CrossRef\]](#)
16. Wang G, Wu Y, Zhang W, Li J, Wu P, Xie C. Clinical value of whole-body F-18 fluorodeoxyglucose positron emission tomography/computed tomography in patients with carcinoma of unknown primary. *J Med Imaging Radiat Oncol* 2013;57:65–71. [\[CrossRef\]](#)
17. Pimiento JM, Teso D, Malkan A, Dudrick SJ, Palesty JA. Cancer of unknown primary origin: a decade of experience in a community-based hospital. *Am J Surg* 2007;194:833–7. [\[CrossRef\]](#)
18. Kwee TC, Kwee RM. Combined FDG-PET/CT for the detection of unknown primary tumors: systematic review and meta-analysis. *Eur Radiol* 2009;19:731–44. [\[CrossRef\]](#)
19. Uematsu H, Sadato N, Ohtsubo T, Tsuchida T, Nakamura S, Sugimoto K, et al. Fluorine-18-fluorodeoxyglucose PET versus thallium-201 scintigraphy evaluation of thyroid tumors. *J Nucl Med* 1998;39:453–9.
20. Lim HS, Yoon W, Chung TW, Kim JK, Park JG, Kang HK, et al. FDG PET/CT for the detection and evaluation of breast diseases: usefulness and limitations. *Radiographics*. 2007 Oct;27 Suppl 1:S197-213. [\[CrossRef\]](#)
21. Park JS, Yim JJ, Kang WJ, Chung JK, Yoo CG, Kim YW, et al. Detection of primary sites in unknown primary tumors using FDG-PET or FDG-PET/CT. *BMC Res Notes* 2011;4:56. [\[CrossRef\]](#)
22. Kim SY, Roh JL, Yeo NK, Kim JS, Lee JH, Choi SH, et al. Combined 18F-fluorodeoxyglucose-positron emission tomography and computed tomography as a primary screening method for detecting second primary cancers and distant metastases in patients with head and neck cancer. *Ann Oncol* 2007;18:1698–703. [\[CrossRef\]](#)
23. Ouyang L, Shi ZY, Lin ZG. 18F-FDG PET/CT makes a significant contribution to diagnosis of malignancy in patients with cervical lymphadenopathy: a study using optimal scale regression tests. *Chin Med J (Engl)* 2013;126:659–67.
24. Roh JL, Kim JS, Lee JH, Cho KJ, Choi SH, Nam SY, et al. Utility of combined (18)F-fluorodeoxyglucose-positron emission tomography and computed tomography in patients with cervical metastases from unknown primary tumors. *Oral Oncol* 2009;45:218–24. [\[CrossRef\]](#)
25. Lauenstein TC, Semelka RC. Emerging techniques: whole-body screening and staging with MRI. *J Magn Reson Imaging* 2006;24:489–98. [\[CrossRef\]](#)
26. Brauck K, Zenge MO, Vogt FM, Quick HH, Stock F, Trarbach T, et al. Feasibility of whole-body MR with T2- and T1-weighted real-time steady-state free precession sequences during continuous table movement to depict metastases. *Radiology* 2008;246:910–6. [\[CrossRef\]](#)