

# Intracranial abscess developed after ganciclovir treatment: A case report

 Murat Cansever,<sup>1</sup>  Elif Nurdan Ozmansur,<sup>2</sup>  Alper Ozcan,<sup>3</sup>  
 Zehra Filiz Kahraman,<sup>4</sup>  Turkan Patiroglu<sup>1</sup>

<sup>1</sup>Department of Pediatric Immunology and Allergy, Erciyes University Faculty of Medicine, Kayseri, Turkey

<sup>2</sup>Department of Pediatric, Erciyes University Faculty of Medicine, Kayseri, Turkey

<sup>3</sup>Department of Hematology and Oncology, Erciyes University Faculty of Medicine, Kayseri, Turkey

<sup>4</sup>Department of Pediatric Radiology, Erciyes University Faculty of Medicine, Kayseri, Turkey

## ABSTRACT

In this report, we examine severe neutropenia secondary to ganciclovir treatment and associated intracranial abscess in a patient with respiratory insufficiency who required intubation due to cytomegalovirus (CMV) pneumonitis. Secondary neutropenia is a condition encountered more frequently than primary neutropenia, and additional risk factors may lead to vital complications, independent of the presence of additional risk factors.

*Keywords:* Cranial abscess; cytomegalovirus; ganciclovir; secondary neutropenia.

**Cite this article as:** Cansever M, Ozmansur EN, Ozcan A, Kahraman ZF, Patiroglu T. Intracranial abscess developed after ganciclovir treatment: A case report. *North Clin Istanbul* 2018;5(4):353–356.

Neutropenia is defined as the absolute neutrophil count (ANC) below 1500 cells/mm<sup>3</sup>. The severity of neutropenia is associated with the ANC. It can be classified as severe neutropenia (ANC, <500/mm<sup>3</sup>), moderate neutropenia (ANC, <500–1000/mm<sup>3</sup>), and mild neutropenia (ANC, <1000–1500/mm<sup>3</sup>) [1]. The classification of neutropenia can be done in several different ways, taking into account different characteristics.

Acute neutropenia is defined as a neutropenia lasting less than 3 months, and chronic neutropenia lasts longer than 3 months. Congenital causes constitute primary neutropenia, while acquired causes lead to secondary neutropenia [2–4].

Neutropenia is a life-threatening condition that can cause serious infections. Secondary neutropenia is more frequently encountered than primary neutropenia. A number of different etiologies have been shown to cause secondary neutropenia. Some of these are infectious agents, drugs, malnutrition, metabolic diseases, and environmental factors [5, 6]. Drug-related neutropenia is a common condition that can be seen at any age. Drug-related neu-

troponia may manifest itself through many mechanisms.

Neutropenia can manifest itself through the immune mechanism, and it can be seen following direct suppression of the precursors in the bone marrow. The first approach to treatment is to discontinue neutropenic drugs and to treat it with the granulocyte-colony-stimulating factor (G-CSF) [7, 8].

Herein, we would like to present a case of intracranial abscess associated with neutropenia following ganciclovir treatment in a case with normal neutrophil counts.

## CASE REPORT

A 6-month-old previously healthy male patient was admitted to the emergency center with cough and respiratory distress. Posteroanterior chest X-ray demonstrated increased aeration and infiltration in the reticular pattern that established the diagnosis of bronchopneumonia, and treatment was initiated. In the follow-up, the postero-anterior lung graft suggested progression to respiratory distress syndrome, so acyclovir and oseltamivir were added to

*Received:* March 17, 2017 *Accepted:* October 01, 2017 *Online:* August 09, 2018



**Correspondence:** Dr. Murat CANSEVER. Erciyes Universitesi Tip Fakultesi, Fevzi Mercan Cocuk Hastanesi, Cocuk Immunoloji Departamani, 38039 Kayseri, Turkey.

Phone: +90 352 207 66 66 e-mail: mcansever66@hotmail.com

© Copyright 2018 by Istanbul Provincial Directorate of Health - Available online at [www.northclinist.com](http://www.northclinist.com)

**TABLE 1.** Hemogram, immunoglobulins, and subgroups of lymphocytes

Hemogram	WBC (mm <sup>3</sup> )	Hb (gr/dl)	Plt (mm <sup>3</sup> )	ANC (mm <sup>3</sup> )	ALC (mm <sup>3</sup> )
	4500	9.5	445000	470	3360
	9600	10.2	355000	4550	4700
Immunoglobulins	IgG (mg/dl)	IgM (mg/dl)	IgA (mg/dl)	IgE (mg/dl)	Eosinophil %/(mm <sup>3</sup> )
	609	17.3	5.81	18.5	0.9/100
Subgroups of lymphocytes	CD3 (%)/(mm <sup>3</sup> )	CD4 (%)/(mm <sup>3</sup> )	CD8 (%)/(mm <sup>3</sup> )	CD19 (%)/(mm <sup>3</sup> )	NK (%)/(mm <sup>3</sup> )
	69.7/3275	39.6/1861	25.2/1184	22.8/1071	5/235

WBC: White blood cell; Hgb: Hemoglobin; Plt: Platelet; ANC: Absolute neutrophil count; ALC: Absolute lymphocyte count; NK: Natural killer.

the treatment. On the 7<sup>th</sup> day of the follow-up, the patient's general condition deteriorated, and he was taken into the intensive care unit because of the necessity of intubation.

On the respiratory tract pathogenetic agent panel, upon cytomegalovirus (CMV), and CMV PCR positivity, we switched from acyclovir to ganciclovir treatment 4 weeks after the initiation of ganciclovir therapy. The CMV PCR negativity was detected, so the treatment was discontinued. The patient experienced seizures, and the head control was difficult during extubating and weaning from mechanical ventilation while he was followed up in the intensive care unit. Therefore, cranial magnetic resonance imaging (MRI) was obtained which revealed a 4.5x3 cm lesion with restricted diffusion consistent with the abscess formation. The patient was operated with the indication of cranial abscess.

Bacterial growth was not detected in the cultures of the abscess material, and gram staining did not reveal the presence of any infectious agent. The CMV-PCR test result of the abscess material was reported as negative.

The patient was referred to the Pediatric Immunology Clinic for further investigation of possible underlying immunodeficiency. The first physical examination of the patient did not reveal any pathology regarding skin, cardiovascular and respiratory systems, and pulmonary vasculature. Lymphadenopathy, hepatosplenomegaly, and microcephaly were not observed, and examinations of other systems were unremarkable.

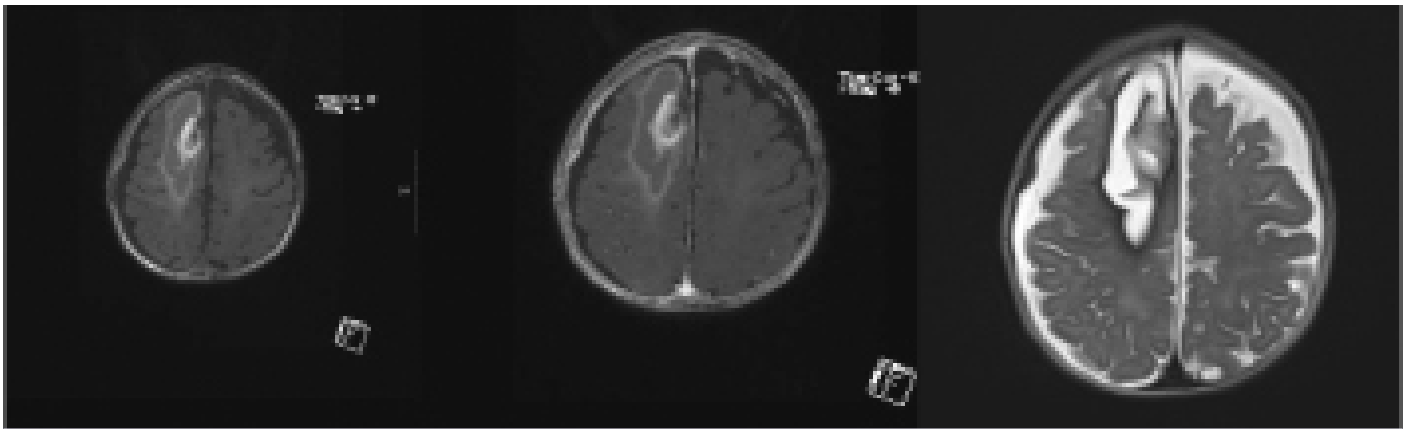
To differentiate between congenital and acquired CMV infection of the patient, eye examination, hearing

test, cranial magnetic resonance (MR), and CMV avidity tests were performed. Calcification was not observed on cranial MR in the patient, whose ocular examination and hearing test results were within the normal limits. The CMV avidity test result was negative. The patient was evaluated in terms of genetics and neurometabolism. In the evaluation of pediatric neurology, no pathology was detected, and the convulsion experienced was interpreted as a manifestation of the secondary to intracranial abscess. Metabolic tests were normal.

A broad-spectrum antibiotherapy (meropenem, vancomycin) was initiated based on the blood culture results.

The hemogram of the patient was reported as follows: WBC, 4500/mm<sup>3</sup>; neutrophils, 470/mm<sup>3</sup>; lymphocytes, 3360/mm<sup>3</sup>; Hgb, 9.5 gr/dl; and Plt, 445,000/mm<sup>3</sup>. On peripheral smear, atypical cells were not detected, and only few neutrophils and toxic granulation were observed. Immunoglobulin results were the following: IgG, 609 mg/dl; IgM, 17.3 mg/dl; IgA, 5.81 mg/dl. Lymphocyte subgroups were CD3, 69.7%; CD4, 39.6%; CD8, 25.2%; CD19, 22.8%; and NK, 5.0% (Table 1). The dihydrorodamine test was normal.

Repeated control MRI obtained in our clinic was evaluated in favor of bleeding (Figure 1). The patient was consulted to neurosurgery for operation. During the operation, pus was drained from the area, and it was interpreted as hemorrhage. The operation was completed by placing the catheter in the loge. Microbiological examination of the material collected during the operation, and abscess material retrieved from the catheter were unremarkable. Gram staining and antibiogram could not reveal any bac-



**FIGURE 1.** Cranial magnetic resonance T1-weighted contrasted and non-contrast, T2-weighted images of the patient.

terial growth in both specimens. Neutropenia was not detected in the evaluation of whole blood counts calculated during healthy periods of the patient, and at the starting time of his first complaints (WBC, 9600/mm<sup>3</sup>; lymphocytes, 4700/mm<sup>3</sup>; neutrophils: 4550/mm<sup>3</sup>).

The bone marrow aspiration was performed to exclude the primary etiologies, drug-related secondary neutropenia was considered, and maturation arrest was not observed. The samples were sent for genetic analysis to exclude possible congenital causes of neutropenia, and the result was reported as normal. The cyclic pattern was not observed in the weekly hemogram follow-ups performed to detect cyclic neutropenia.

After the exclusion of primary etiologies, since the number of neutrophils calculated during the clinical follow-up was within the normal limits, infection associated with drug-related secondary neutropenia was considered in the patient who developed neutropenia after the CMV infection and ganciclovir treatment. It is thought that the cranial abscess developed secondary to these risk factors because of the presence of risk factors such as intubation in the intensive care conditions during this period of neutropenia.

Ganciclovir treatment was continued with the CMV PCR follow-ups, and when the CMV PCR results became negative, neutropenia resolved spontaneously. The patient whose lung infection and cranial abscess treatment completed was discharged with cure. Neutropenia was not detected during the clinical follow-up.

## DISCUSSION

The etiology of acquired neutropenia involves destruction or consumption of peripheral neutrophils, which leads to

the shortening of the neutrophil life. The bone marrow is normal, or the maturation is late in the metamyelocyte/band stage. The risk of developing infections in acquired neutropenia is significantly less than in other neutropenias [9–11].

Secondary neutropenia can be caused by infections, drugs, and autoimmune and isoimmune etiologies [12]. In childhood, the most common etiologies are infections of the secondary neutropenia (viral, bacterial, and parasitic). The most common causes of acute secondary neutropenia are viral infections: CMV, the Epstein–Barr virus, hepatitis A and B, influenza A and B viruses, measles, parvovirus B19, rubella, and chicken pox [13]. Mechanisms of neutropenia secondary to infection involve the passage of neutrophils from circulation into the marginal pool, sequestration, increased consumption, or a decrease in the bone marrow reserves [14].

Neutropenia usually begins 24 hours following infection and lasts for 3–8 days in patients who have or had an infection [5]. Infection with CMV leads to neutropenia, through decreased production and increased destruction of neutrophils [12]. The G-CSF can be used in neutropenic conditions due to depletion and inadequate production of bone marrow reservoir pools in severe sepsis [10]. Since in our case neutropenia developed at the time of detection of the CMV infection, and other possible causes have been ruled out, we interpreted the infection in favor of secondary neutropenia.

Drug-related secondary neutropenia may be caused by many drugs. The most frequent causative drug groups include chemotherapy drugs, analgesics and anti-inflammatory agents, antipsychotics, antiepileptics, antithyroids, cardiovascular agents, and antibiotics [14].

Mechanisms of neutropenia associated with drugs include the idiosyncratic suppression of myeloid production, dose-dependent suppression, suppression due to individual differences in drug metabolisms, and drug-hapten disease-induced destruction [15].

Diagnostic criteria of drug-related neutropenia include neutrophil count below 500 cells/mm<sup>3</sup>, the hemoglobin level above 10 gr/dl, platelet count above 100,000 cells/mm<sup>3</sup>, and drug use history without a causative agent that may cause secondary neutropenia [16, 17]. Ganciclovir idiosyncratically suppresses myeloid production and causes neutropenia [15].

With the use of medications, neutropenia usually develops within 2 to 3 months and is expected to resolve within 10 days after the discontinuation of drug application. However, sometimes this period can be shorter or longer [12]. In our case, after all other causes were excluded, we thought of secondary neutropenia due to ganciclovir treatment for infection because of its myelosuppressive effects in the bone marrow. In our case, neutropenia resolved within 7–10 days after complete control of the infection and cessation of ganciclovir treatment, and neutropenia did not recur during the follow-up period.

Secondary neutropenia due to autoimmune causes is more common in adults, and it constitutes a part of autoimmune diseases.

If rheumatologic diseases are not considered in the presence of secondary autoimmune neutropenia in children, autoimmune lymphoproliferative syndrome and Evans syndrome should first come to mind [18].

Both diseases had findings of lymphadenopathy, splenomegaly, and autoimmunity, which were not detected in our patient. Neutropenia is a serious, life-threatening condition and can cause serious complications. Agranulocytosis increases the susceptibility to many bacterial and fungal infections [19].

## Conclusion

Neutropenia is a serious clinical condition with congenital or acquired causes. Clinicians are more likely to encounter secondary neutropenia, and it should be kept in mind that life-threatening complications such as primary causes may develop in these patients.

**Informed Consent:** Written informed consent was obtained from the patient for the publication of the case report and the accompanying images.

**Conflict of Interest:** No conflict of interest was declared by the authors.

**Financial Disclosure:** The authors declared that this study has received no financial support.

**Authorship Contributions:** Concept – M.C.; Design – M.C.; Supervision – M.C.; Materials – M.C., E.N.O., Z.F.K; Data collection &/or processing – E.N.O., Z.F.K; Analysis and/or interpretation – M.C., Z.F.K.; Writing – M.C.; Critical review – M.C., A.O., T.P.

## REFERENCES

1. Menell JS. Disorders of white blood cells. In: Lanzowsky P. Manual of Pediatric Hematology and Oncology. 5<sup>th</sup> ed. Amsterdam: Academic Press/Elsevier; 2011. p. 272–320.
2. Clay ME, Schuller RM, Bachowski GJ. Granulocyte serology: current concepts and clinical significance. *Immunohematology* 2010;26:11–21.
3. Newburger PE, Dale DC. Evaluation and management of patients with isolated neutropenia. *Semin Hematol* 2013;50:198–206. [CrossRef]
4. Walkovich K, Boxer LA. How to approach neutropenia in childhood. *Pediatr Rev* 2013;34:173–84. [CrossRef]
5. Husain EH, Mullah-Ali A, Al-Sharidah S, Azab AF, Adekile A. Infectious etiologies of transient neutropenia in previously healthy children. *Pediatr Infect Dis J* 2012;31:575–7. [CrossRef]
6. Andrés E, Maloisel F. Idiosyncratic drug-induced agranulocytosis or acute neutropenia. *Curr Opin Hematol* 2008;15:15–21. [CrossRef]
7. Palmblad J, Papadaki HA, Eliopoulos G. Acute and chronic neutropenias. What is new? *J Intern Med* 2001;250:476–91. [CrossRef]
8. Rudolph CD, Rudolph AM, Lister GE, First LR, Gershon AA. Rudolph Pediatry. In: Yüdarök M, translation editor. Ankara: Güneş Tıp Kitabevi; 2013. p. 1592.
9. Boxer LA. How to approach neutropenia. *Hematology Am Soc Hematol Educ Program* 2012;174–82.
10. Berliner N, Horwitz M, Loughran TP Jr. Congenital and acquired neutropenia. *Hematology Am Soc Hematol Educ Program* 2004:63–79.
11. Fioredda F, Calvillo M, Bonanomi S, Coliva T, Tucci F, Farruggia P, et al; Neutropenia Committee of the Marrow Failure Syndrome Group of the AIEOP (Associazione Italiana Emato-Oncologia Pediatrica). Congenital and acquired neutropenias consensus guidelines on therapy and follow-up in childhood from the Neutropenia Committee of the Marrow Failure Syndrome Group of the AIEOP (Associazione Italiana Emato-Oncologia Pediatrica). *Am J Hematol* 2012;87:238–43.
12. Celkan T, Koç BS. Approach to the patient with neutropenia childhood. *Turk Pediatry Ars* 2015;50:136–44. [CrossRef]
13. Boxer L, Dale DC. Neutropenia: causes and consequences. *Semin Hematol* 2002;39:75–81. [CrossRef]
14. Aydoğdu S, Çelik A, Karakaş Z. An Approach to Neutropenia [Article in Turkish]. *J Child* 2015;15:3–9
15. Devocioğlu Ö, Gümüş S. Approach to Childhood Neutropenia. *J Child* 2012;12:53–9. [CrossRef]
16. Andres E, Zimmer J, Affenberger S, Federici L, Alt M, Maloisel F. Idiosyncratic drug-induced agranulocytosis: Update of an old disorder. *Eur J Intern Med* 2006;17:529–35. [CrossRef]
17. van der Klauw MM, Goudsmit R, Halie MR, van't Veer MB, Herings RM, Wilson JH, et al. A population-based case-cohort study of drug-associated agranulocytosis. *Arch Intern Med* 1999;159:369–74. [CrossRef]
18. Farruggia P, Dofour C. Diagnosis and management of primary autoimmune neutropenia in children: insights for clinicians. *Ther Adv Hematol* 2015;6:15–24. [CrossRef]
19. Palmblad J, Papadaki HA, Eliopoulos G. Acute and chronic neutropenias. What is new? *J Intern Med* 2001;250:476–91. [CrossRef]