

Complicated congenital seminal vesicle cyst with unilateral renal agenesis: A rare case report

 Sinan Kılıç,¹  Mehmet Kaba²

¹Department of Pediatric Surgery, Gebze Yuzyil Hospital, Gebze, Kocaeli, Türkiye

²Department of Urology, Gebze Yuzyil Hospital, Gebze, Kocaeli, Türkiye

ABSTRACT

A 16-year-old male presented with persistent abdominal pain for 2 weeks. Mild elevation of liver enzymes ALT and AST was observed. Abdominal ultrasound revealed a missing right kidney and a dense cystic mass near the bladder. CT scan confirmed right kidney agenesis and identified a 7.5×7.5×10 cm cystic mass extending from the bladder to the prostate. Due to fever and worsening pain, laparoscopic surgery was performed to remove the complicated seminal vesicle cyst. Purulent ejaculate was drained and the cystic mass was completely excised. The patient recovered well and liver enzyme levels returned to normal after 1 month.

Keywords: Acute abdomen, Renal agenesis, Seminal vesicle cyst

Introduction

Seminal vesicle cysts associated with genitourinary anomalies are quite rare.^[1] While small seminal vesicle cysts (<5 cm) are usually asymptomatic, larger cysts can become complicated and lead to acute abdomen. Moreover, larger cysts can cause obstructive urinary symptoms.^[2] It is extremely rare for these cysts to present with symptoms in childhood and adolescence. Although acute appendicitis, Meckel's diverticulitis, and renal pathologies are the most common causes of acute abdomen in children and adolescents, seminal vesicle cysts and their complicated forms are rarely encountered. In this case presentation, we aim to present a patient who presented to our clinic with symptoms of acute abdomen, elevated fever, and liver enzyme levels. Initially, the patient was

investigated for acute appendicitis, followed by viral hepatitis and hydatid cyst infection, and eventually, it was revealed that the patient had a complicated seminal vesicle cyst. We aim to present this rare case that is rarely encountered in the pediatric surgery and pediatric urology clinics.


Case Report

A 16-year-old male patient presented to the pediatric surgery outpatient clinic with complaints of abdominal pain that had been ongoing for about 2 weeks. Initial physical examination revealed tenderness and subfebrile fever (37.8°C), particularly in the suprapubic region. Laboratory investigations showed leukocytosis (16.000/mm³) and an increase in C-reactive protein lev-



Received: 20.06.2023 Revision: 20.06.2023 Accepted: 26.06.2023

Correspondence: Sinan Kılıç, M.D., Gebze Yüzyil Hastanesi, Çocuk Cerrahisi Bölümü, Gebze, Kocaeli, Türkiye
e-mail: dr.sinankilic@yahoo.com



This work is licensed under a Creative Commons Attribution-NonCommercial 4.0 International License.

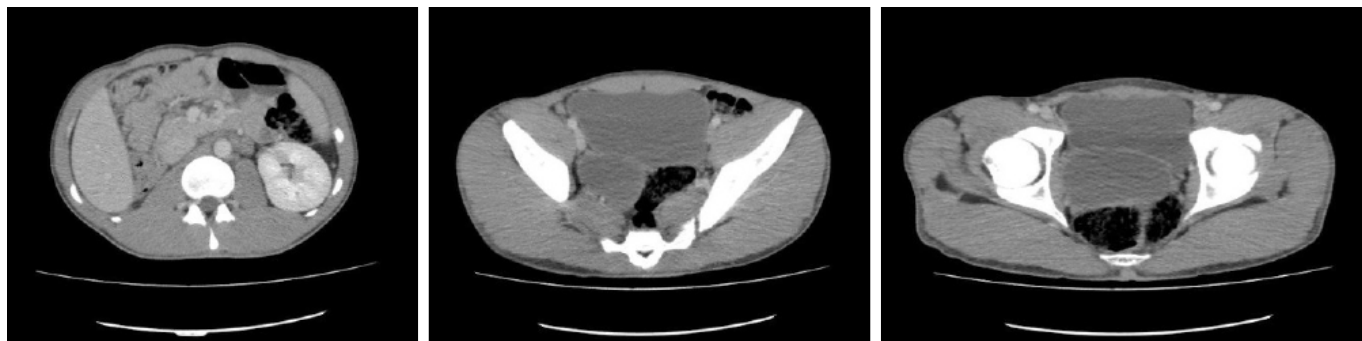

Figure 1. Vesicle cyst on abdominal tomography.

els (45 mg/dL, reference range 0–5). Liver enzymes ALT and AST were found to be slightly elevated (80 mg/dL and 85 mg/dL, respectively). Viral hepatitis panel and hydatid cyst serology were negative. Abdominal ultrasonography revealed the absence of the right kidney and a dense cystic mass in the posterior of the bladder. Abdominal tomography was performed on the patient. The tomography confirmed agenesis of the right kidney and identified a cystic mass measuring 7.5×7.5×10 cm in diameter, extending from the posterior of the bladder to the central zone of the prostate (Fig. 1). The patient's fever (38.4°C) persisted, and the abdominal pain worsened, leading to surgical intervention. The complicated seminal vesicle cyst located in the posterior of the bladder was opened laparoscopically. After the cyst was opened, a large amount of purulent ejaculate fluid was aspirated from its content (Fig. 2 and Video 1). Subsequently, the cystic mass was completely removed (Fig. 3 and Video 1). The patient had a urinary catheter removed on the 1st

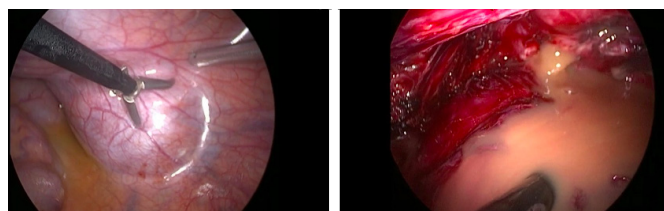


Figure 2. Laparoscopic excision.

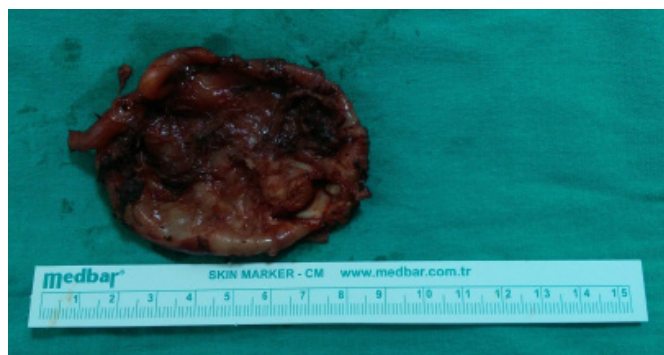

Figure 3. Image of cyst after excision.

day, the drain was removed on the 2nd day, and he was discharged on the 3rd post-operative day. A month later, liver enzymes were observed to have returned to normal. The patient did not experience any abdominal pain or genitourinary symptoms after the operation.

Discussion

The association of congenital seminal vesicle cyst and unilateral renal agenesis is not surprising, as both organs originate from the mesonephric (Wolffian) duct during embryogenesis.^[1] Failure of isolated ureteral budding leads to renal agenesis, while the rest of the genital system remains unaffected. However, abnormal development of the mesonephric duct at the 12th week of gestation affects the ureter, kidney, seminal vesicle, and vas deferens on the same side.^[2] Most seminal vesicle cysts are diagnosed in adults and are generally seen in the third and fourth decades of life.^[1,3-5] While they are usually observed in sexually active males, their occurrence in the adolescent age.^[6]

Disclosures

Informed Consent: Written, informed consent was obtained from the patient's family for the publication of this case report and the accompanying images.

Peer-review: Externally peer-reviewed.

Conflict of Interest: None declared.

Authorship Contributions: Concept – S.K.; Design – S.K.; Supervision – S.K.; Materials – S.K.; Data collection and/or processing – S.K., M.K.; Analysis and/or interpretation – S.K.; Literature search – S.K.; Writing – S.K.; Critical review – S.K., M.K.

References

1. Rappe BJ, Meuleman EJ, Debruyne FM. Seminal vesicle cyst with ipsilateral renal agenesis. *Urol Int* 1993;5054–6.

2. Heaney JA, Pfister RC, Meares EM Jr. Giant cyst of the seminal vesicle with renal agenesis. *AJR Am J Roentgenol* 1987;149:139–40.
3. Liatsikos EN, Lee B, Filos KS, Barbalias GA. Congenital seminal vesicle cyst and coexisting renal agenesis: Laparoscopic approach. *Urology* 2004;63:584–6.
4. King BF, Hattery RR, Lieber MM, Berquist TH, Williamson B Jr, Hartman GW. Congenital cystic disease of the seminal vesicle. *Radiology* 1991;178:207–11.
5. Livingston L, Larsen CR. Seminal vesicle cyst with ipsilateral renal agenesis. *AJR Am J Roentgenol* 2000;175:177–80.
6. van den Ouden D, Blom JH, Bangma C, de Spiegeleer AH. Diagnosis and management of seminal vesicle cysts associated with ipsilateral renal agenesis: A pooled analysis of 52 cases. *Eur Urol* 1998;33:433–40.