

# Gastrointestinal system foreign bodies

Örgün Güneş,<sup>1</sup> Arif Atay,<sup>1</sup> Furkan Karahan,<sup>2</sup> Hakan Çamyar,<sup>3</sup> Osman Nuri Dilek<sup>1</sup>

<sup>1</sup>Department of General Surgery, Katip Çelebi University Atatürk Training and Research Hospital, Izmir, Türkiye

<sup>2</sup>Department of General Surgery, Erciş Şehit Rıdvan Çevik Hospital, Van, Türkiye

<sup>3</sup>Department of Gastroenterology, Katip Çelebi University Atatürk Training and Research Hospital, Izmir, Türkiye

## ABSTRACT

**Introduction:** While foreign bodies in the gastrointestinal tract are observed more frequently and accidentally in the childhood age group, they may occur to attract attention, sexual satisfaction, self-harming behavior, abuse, secondary gain, or during self-treatment in young people and adults. In the United States, 1500 people die yearly from ingested foreign bodies. The leading cause of mortality is obstruction and perforation due to impaction in the gastrointestinal system. In this study, we evaluated the clinical findings, risk factors, and clinical output data of foreign bodies in the gastrointestinal tract and presented the most accurate approach considering the literature.

**Materials and Methods:** This is a retrospective and descriptive study analyzing data from a prospective database. Adult patients admitted to the emergency department of our 3<sup>rd</sup> level university hospital between January 2015 and January 2022 due to foreign bodies in the gastrointestinal tract were included in the study.

**Results:** Transanal rectal body removal in the operating room was performed using the Crede maneuver in seven patients. Laparotomy or thoracotomy was performed in nine patients, and thirty-six patients were treated with endoscopic methods. Endoscopy and laparotomy were performed simultaneously in one patient. It was determined that the foreign body of 29 patients was removed by conservative methods.

**Conclusion:** For treating of foreign bodies, a multidisciplinary approach, including advanced endoscopic and surgery, is required according to the localization and content of the foreign body, underlying cause and patient population.

**Keywords:** Aspiration, Endoscopy, Laparotomy, Prisoner, Rectal

## Introduction

While foreign bodies in the gastrointestinal tract are observed more frequently and accidentally in the childhood age group, they may occur to attract attention, sexual satisfaction, self-harming behavior, abuse, secondary gain, or during self-treatment in young people and adults. It is observed more frequently in patients and prisoners with


various mental and psychiatric disorders and alcohol dependence.<sup>[1,2]</sup>

Most foreign bodies detected in gastrointestinal system (GIS) in children are coins, disc-type batteries, and toy parts. In adults, foreign bodies are observed in a broader range, such as food pieces, sharps, and toothbrushes. Follow-up and treatment should be done with care since



Received: 19.02.2023 Revision: 27.02.2023 Accepted: 27.02.2023

Correspondence: Örgün Güneş, M.D., Katip Çelebi Üniversitesi Atatürk Eğitim ve Araştırma Hastanesi Genel Cerrahi Kliniği, Izmir, Türkiye  
e-mail: orgungunes@hotmail.com



This work is licensed under a Creative Commons Attribution-NonCommercial 4.0 International License.

more damage may occur in the urinary system due to the higher incidence of sharps, especially in adults.<sup>[3,4]</sup> Most ingested foreign bodies are excreted spontaneously without causing any injury to the gastrointestinal tract. However, it can also cause severe complications along the long gastrointestinal tract. In the United States, 1500 people die yearly from ingested foreign bodies. The leading cause of mortality is obstruction and perforation due to impaction in the GIS.<sup>[5]</sup>

Most rectal foreign bodies were deliberately inserted by the patient or partner. In cases where the patient cannot remove the foreign body spontaneously, delays in seeking medical help due to embarrassment increase morbidity and mortality.<sup>[6]</sup>

There are treatment options according to the level of the foreign body in the gastrointestinal tract and the content of the swallowed body. Foreign bodies detected in the esophagus require an urgent therapeutic approach, whereas foreign bodies in the stomach and intestinal system can be followed. With the development of endoscopic treatment, approximately 15% of gastrointestinal foreign bodies require surgical intervention.<sup>[7]</sup>

In this study, we evaluated the clinical findings, risk factors, and clinical output data of foreign bodies in the gastrointestinal tract and presented the most accurate approach considering the literature.

## Materials and Methods

This is a retrospective and descriptive study analyzing data from a prospective database. Adult patients admitted to the emergency department of our 3<sup>rd</sup> level university hospital between January 2015 and January 2022 due to foreign bodies in the gastrointestinal tract were included in the study.

### Data Collection

The patients' age, gender, socioeconomic levels, psychiatric diseases, sexual drive disorders, conviction status, and medical history were examined. Types, characteristics, number, and location of the removed foreign bodies, accidental or deliberate ingestion, in which part of the gastrointestinal tract they obstructed, imaging methods and endoscopic procedures performed, and their timing, surgical indications, surgical techniques, the duration of surgery, hospital stay times, pathology data, morbidity, and mortality rates were analyzed retrospectively. In addition,

the time of admission to the emergency department and their complaints were recorded.

Patients with missing data, those under 18, and whose data could not be reached not included in the study.

### Statistical Analysis

Data were evaluated in the IBM SPSS Statistics 25.0 statistics package program. A comparison of variables and two groups was made using the Mann–Whitney U test.  $P < 0.05$  value was considered statistically significant.

The study was conducted out following the principles of the Helsinki Declaration. As a routine procedure, written informed consent was obtained from each patient for all procedures and publications. Ethics committee approval was received for this study from the Clinical Trials Ethics Committee (2023-GOKAE-0081).

## Results

Of the 82 patients included in the study, 59 (71%) were male, 23 (29%) were female, and the mean age was  $38.1 \pm 14.0$  years. 27 (32.9%) patients were prisoners in a closed prison. When the patients were examined according to their medical history, it was seen that 30 (24.6%) of them were admitted to or followed up in the psychiatry outpatient clinic (Table 1). While five patients had moderate-to-severe mental retardation, one was diagnosed with Down syndrome.

Among the foreign bodies, objects such as razors, pins, batteries, lighters, forks, magnets, dental implants, needles, bones, food residues such as fishbones, bottles, caps, eggplants, and sex objects were detected (Table 2). From the anamnesis of the patients, it was seen that orally ingested foreign bodies were accidentally used to gain secondary gain in prisoners or due to psychiatric mental pathologies. In addition, four patients were found to have taken foreign bodies orally due to drug capsule smuggling. In rectal foreign bodies, the practices of the

**Table 1. Demographic data**

Variables	n (%)
Gender (Female/Male)	59 (71)/23 (29)
Age	38.1±14.0
Prisoners	27 (32.9)
Psychiatric disease	30 (24.6)

Table 2. Types and location of foreign body

Foreign body	Osephagus	Stomach	Small intestine	Colon	Rectum	Total
Razer Blade	1	8	10	4	1	24
Pin	1	6	3	2	0	12
Bone or awn	4	0	3	0	0	7
deodorant/juice container	0	0	0	0	6	6
Dental implant	0	1	5	0	0	6
Battery	0	3	1	0	0	4
Nail	0	2	1	1	0	4
Drug bag	0	1	0	0	3	4
Sex toy	0	0	0	0	3	3
Key	0	1	0	1	0	2
Lighter	0	1	1	0	0	2
Glase	0	0	1	1	0	2
Food piece	2	0	0	0	0	2
Sexobject (eggplant)	0	0	0	0	2	2
Ceramic piece	0	0	1	1	0	2
Balloon	0	0	0	0	1	1
Magnet	0	0	1	0	0	1
Fork	0	1	0	0	0	1
Stone	1	0	0	0	0	1
Bottle cap	0	0	0	0	1	1

patients themselves or their partners as a sexual habit were in the first place.

The most common reasons patients applied to the emergency department are pain, nausea, and vomiting. While accidental intestinal foreign bodies were usually applied to the emergency department immediately, the admission time of prisoners and patients who inserted foreign bodies due to sexual habits were recorded later due to judicial processes and the feeling of embarrassment. The latest admission was on the 5th day due to ingested foreign bodies in prisoners, while the latest admission was on the 36th h due to rectal foreign bodies.

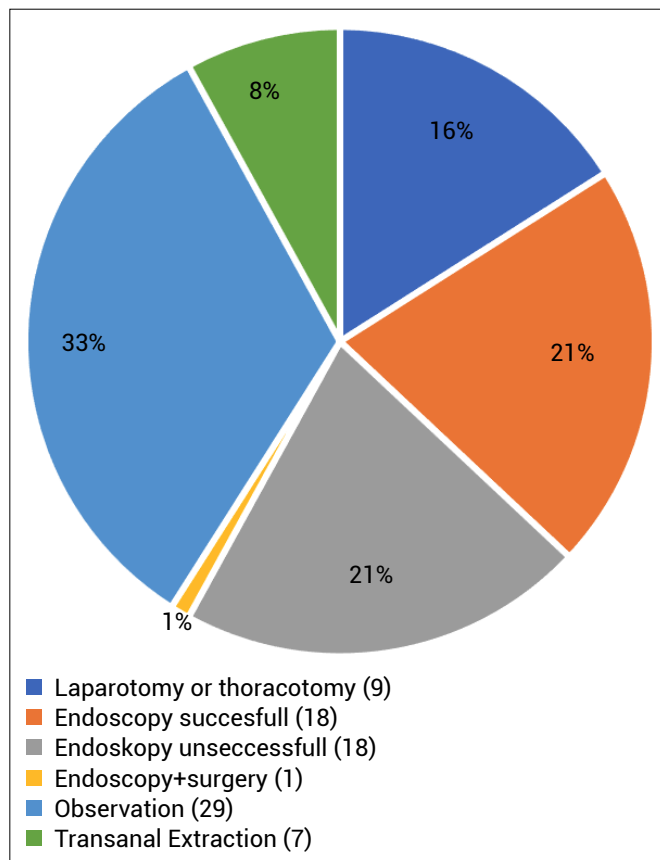
A positive image was detected by abdominal tomography in 65 patients who applied due to a foreign body, and by standing direct abdominal X-ray in 17 of them. According to abdominal tomography findings, the foreign body was detected in the stomach of 15 patients, whereas foreign bodies were detected in the stomach and small intestines of five patients. In three patients, foreign bodies were observed in the colon and stomach. In addition, foreign bodies of 19 patients were detected in the intestinal tract

between the small intestines and the anal canal.

While endoscopy was performed for 36 foreign bodies taken orally, RSS was performed in three patients, and RSS+ gastroscopy was performed in one patient. Eggplant, balloon, and needle were detected in the rectum of the patients who underwent RSS. Foreign bodies other than the eggplant were removed by RSS. However, the eggplant was removed under sedation in operating room conditions. The foreign body was removed in 18 patients who underwent upper gastrointestinal endoscopy, and the foreign body could not be removed in 18 patients (Fig. 1).

The number of patients with foreign bodies detected in the esophagus was 9. Upper GIS endoscopy was performed in all patients for foreign bodies in the esophagus. Foreign bodies were successfully removed by endoscopy in eight of the patients. In the endoscopy performed in the operating room conditions of one patient with an impacted stone in the esophagus, the stone was advanced to the stomach and was removed by laparotomy.

Transanal rectal body removal in the operating room was performed using the Crede maneuver in seven patients.



**Figure 1.** Management of foreign body.

Laparotomy or thoracotomy was performed in nine patients, and thirty-six patients were treated with endoscopic methods. Endoscopy and laparotomy were performed simultaneously in one patient. It was determined that the foreign body of 29 patients was removed by conservative methods.

In our study, mortality was observed in a patient who underwent small bowel resection due to magnet-induced ileus, whereas wound infection was the most common complication in operated patients (Table 3).

**Table 3.** Morbidity and mortality

Variables	n (%)	Total (%)
Mortality	1 (1.2)	1 (1.2)
Morbidity		7 (5.7)
Wound infection	3 (3.6)	
Anastomotic leak	1 (1.2)	
Aspiration pneumonia	1 (1.2)	
Hoarseness	1 (1.2)	
Fournier infection	1 (1.2)	

## Discussion

The 2016 ESGE guideline recommends emergency endoscopic treatment in the first 6 h for sharps and punctures that cause esophageal obstruction and carry the risk of perforation. In addition, a similar approach has been proposed for batteries obstructing the esophagus. The therapeutic endoscopy period is defined as 24 h in bodies that do not have a risk of perforation and partially obstruct.

According to the ESGE guideline for the stomach, therapeutic endoscopic intervention should be performed within 24 h for objects that have an erosive effect, such as sharps, piercing tools, magnets, and batteries, which are at risk of perforation. In medium-sized blunt bodies, therapeutic endoscopy can be planned within 3 days.<sup>[8]</sup>

Our study found that therapeutic esophagogastroduodenoscopy was performed in all patients who applied to the emergency department due to a foreign body in the esophagus within the first 6 h, regardless of the content of the foreign body. The foreign body was removed without complications in approximately 90% of patients with early intervention. The success of the endoscopy performed was considered the complete removal of the foreign body from the digestive tract, and then the absence of foreign bodies was confirmed in the evaluation of the digestive tract. Liu et al. routinely performed endoscopic control after foreign-body removal.<sup>[9]</sup> In our clinic, control endoscopy was not routinely performed in patients who did not have perforation clinics, such as severe pain and crepitation after foreign-body removal. Computed thoracoabdominal tomography is preferred primarily in these patients.

Foreign-body types are associated with geographical and cultural differences in eating habits.<sup>[10]</sup> Although our study was a single-center study, a reason for this wide range of foreign bodies is that we are a hospital where convicted patients in the region are brought.

Mosca et al. reported upper GIS foreign bodies as the most common food residues in western populations.<sup>[11]</sup> In Asian countries, food residues are fish, chicken bones, and fruit seeds.<sup>[12,13]</sup> Razor blades and pins were the most common foreign bodies in our study. The reason was determined as the habits of the prisoners.

Among rectal foreign bodies, deodorant/juice containers, and ready-made sex toys were found in the first place. Similarly, in the literature, the most common rectal foreign bodies have been reported as sex toys, vegetables, bottles,

and drugs.<sup>[14,15]</sup> Kurer et al. reported the predominant male sex ratio in rectal foreign bodies in a systemic review they prepared. In our study, no female patients were detected among the patients with rectal foreign bodies. In the literature, rectal foreign bodies have been detected primarily in men aged 20–40. In our study, while the sex ratios were consistent with the literature, the average age was higher, contrary to the literature. Nearly 80% of the patients were 40 and over.<sup>[16]</sup>

Most foreign bodies reported in the literature are inserted into the rectum by the patient or partner for sexual satisfaction. Secondly, the entry of foreign bodies into the rectum may be due to an underlying psychiatric disease. Rarely, foreign-body insertion is a part of self-injurious behavior. In addition, foreign bodies are used for sexual assault, threats, or in connection with violence.<sup>[5,17]</sup>

In our study, three patients who presented with the rectal foreign body were under psychiatric treatment, and one was a prisoner. The convicted patient had a previous history of rectal foreign bodies to injure himself. In other rectal foreign bodies, the aim was determined as sexual satisfaction.

Patients presenting with the rectal foreign body usually tend to hide this situation. In our study, rectal foreign-body patients were identified as a group with the highest non-compliance with treatment. Four of these patients left the hospital without informing the health personnel after the rectal foreign body was removed.

The most common mortal complication in the literature has been reported as a rectal perforation.<sup>[18]</sup> In our study, while one of the rectal foreign bodies was removed by laparotomy, an ostomy was opened in this patient. Fournier's gangrene developed in one patient due to the foreign body being removed by the rectal route, and anal incontinence was not observed in any of these patients. No perforation or sphincter injury was observed since the foreign bodies we removed, especially the glass ones, were removed without damaging their integrity, and the application times were generally short.

In our clinic, rectal foreign bodies were removed under sedation, operating room conditions and the lithotomy position. Local anesthetic agents were also used to relax the anal sphincter. In addition, if necessary, simultaneous sigmoidoscopy is also applied. Similarly, various types of equipment are used in the literature to protect the sphincters, especially during foreign-body removal.

Spoons, vaginal spatulas, wire and plastic snakes, uterine vulsellum, rubber-covered bone-holding clamps, rubber-covered tonsils or polyp snare, and tenaculum forceps are some of them.<sup>[19,20]</sup>

Different foreign-body removal algorithms have been created in the approach to intestinal foreign bodies. However, each foreign body in the gastrointestinal tract has a unique and different story. In our study, different types of foreign body content were found. Four cases in the study were defined as body packers. These people usually swallow drugs voluntarily or under threat or insert them into their body cavities to smuggle drugs from areas where strict controls are made. The syndrome due to the toxicity caused by tearing the packages in which these substances are wrapped has been defined as Body Packer Syndrome.<sup>[21]</sup>

In these patients, complications such as mechanical ileus and perforation that may be seen in other foreign bodies and intoxication symptoms should be followed closely. In our study, foreign bodies were detected in 3 of 4 body packer cases at the time of admission, in the colon, and in one in the stomach and small intestines. These patients were hospitalized with the approach in the literature and followed up with laxatives, and all foreign bodies were spontaneously removed with conservative treatment. In these cases, stool examinations that do not contain foreign bodies and imaging methods that do not contain foreign bodies were expected, mainly to ensure the output of all substances.<sup>[22]</sup>

## Conclusion

Rectal foreign bodies may occur due to sexual satisfaction, underlying psychiatric illness, threats, attempted assault, or trafficking. A detailed history should be taken precisely and extracted using the least invasive technique possible.

Minimally invasive methods can remove most gastrointestinal foreign bodies or be expelled spontaneously. Centers where emergency endoscopic interventions are performed in the esophagus and rectal bodies, should be preferred.

Protective measures should be taken to prevent the ingestion of foreign objects, particularly in prisoners.

For treating foreign bodies, a multidisciplinary approach, including advanced endoscopic and surgery, is required according to the localization and content of the foreign body, underlying cause and patient population.

## Disclosures

**Ethics Committee Approval:** Ethics committee approval was received for this study from the Clinical Trials Ethics Committee (2023-GOKAE-0081).

**Peer-review:** Externally peer-reviewed.

**Conflict of Interest:** None declared.

**Authorship Contributions:** Concept – O.G.; Design – A.A., F.K.; Supervision – O.N.D., H.C.; Materials – O.G.; Data collection – O.G., F.K.; Analysis – A.A., O.N.D.; Literature search – O.G., H.C.; Writing – O.G., F.K., A.A.; Critical reviews – O.N.D.

## References

- Dalal PP, Otey AJ, McGonagle EA, Whitmill ML, Levine EJ, McKimmie RL, et al. Intentional foreign object ingestions: Need for endoscopy and surgery. *J Surg Res* 2013;184:145–9. [\[CrossRef\]](#)
- Fung ACH, Tsui BSY, Wong SYS, Tam YH. Self-inserted foreign bodies during COVID-19: Two case reports. *Hong Kong Med J* 2021;27:142–4. [\[CrossRef\]](#)
- Egorov VI, Musatenko LY, Mustafaev DM. Inorodnye tela pishchevoda u detei [Foreign bodies of the esophagus in children]. [Article in Russian]. *Vestn Otorinolaringol* 2021;86:46–9. [\[CrossRef\]](#)
- Skok P, Skok K. Urgent endoscopy in patients with “true foreign bodies” in the upper gastrointestinal tract - a retrospective study of the period 1994-2018. *Z Gastroenterol* 2020;58:217–23. [\[CrossRef\]](#)
- Anderson KL, Dean AJ. Foreign bodies in the gastrointestinal tract and anorectal emergencies. *Emerg Med Clin North Am* 2011;29:369–400. [\[CrossRef\]](#)
- Pashaei MR, Tarvirdinasab S, Jazayeri M, Najafinia K, Pashaei B, Mobaraki K, et al. Rectal foreign body presenting as chronic diarrhea: a case report. *Gastroenterol Nurs* 2021;44:55–9.
- Palta R, Sahota A, Bemarki A, Salama P, Simpson N, Laine L. Foreign-body ingestion: characteristics and outcomes in a lower socioeconomic population with predominantly intentional ingestion. *Gastrointest Endosc* 2009;69:426–33.
- Birk M, Bauerfeind P, Deprez PH, Häfner M, Hartmann D, Hassan C, Hucl T, et al. Removal of foreign bodies in the upper gastrointestinal tract in adults: European Society of Gastrointestinal Endoscopy (ESGE) Clinical Guideline. *Endoscopy* 2016;48:489–96. [\[CrossRef\]](#)
- Liu Q, Liu F, Xie H, Dong J, Chen H, Yao L. Emergency removal of ingested foreign bodies in 586 adults at a single hospital in china according to the European Society of Gastrointestinal Endoscopy (ESGE) Recommendations: a 10-year retrospective study. *Med Sci Monit* 2022;28:e936463.
- Ambe P, Weber SA, Schauer M, Knoefel WT. Swallowed foreign bodies in adults. *Dtsch Arztebl Int* 2012;109:869–75.
- Mosca S, Manes G, Martino R, Amitrano L, Bottino V, Bove A, et al. Endoscopic management of foreign bodies in the upper gastrointestinal tract: report on a series of 414 adult patients. *Endoscopy* 2001;33:692–6. [\[CrossRef\]](#)
- Hong KH, Kim YJ, Kim JH, Chun SW, Kim HM, Cho JH. Risk factors for complications associated with upper gastrointestinal foreign bodies. *World J Gastroenterol* 2015;21:8125–31. [\[CrossRef\]](#)
- Zhang S, Cui Y, Gong X, Gu F, Chen M, Zhong B. Endoscopic management of foreign bodies in the upper gastrointestinal tract in South China: a retrospective study of 561 cases. *Dig Dis Sci* 2010;55:1305–12. [\[CrossRef\]](#)
- Ayantunde AA. Approach to the diagnosis and management of retained rectal foreign bodies: clinical update. *Tech Coloproctol* 2013;17:13–20. [\[CrossRef\]](#)
- Ostrowski K, Edwards G, Maruno K. Removal of retained rectal foreign bodies in the emergency department. *Emerg Med Australas* 2016;28:459–61. [\[CrossRef\]](#)
- Kurer MA, Davey C, Khan S, Chintapatla S. Colorectal foreign bodies: a systematic review. *Colorectal Dis* 2010;12:851–61.
- Lazzari V, Siboni S, Asti E, Bonavina L. Transanal removal of a broken drinking glass self-inserted and retained in the rectum. *BMJ Case Rep* 2017;2017:bcr2017220268. [\[CrossRef\]](#)
- Bhasin S, Williams JG. Rectal foreign body removal: increasing incidence and cost to the NHS. *Ann R Coll Surg Engl* 2021;103:734–7.
- Lim KJ, Kim JS, Kim BG, Park SM, Ji JS, Kim BW et al. Removal of rectal foreign bodies using tenaculum forceps under endoscopic assistance. *Intest Res* 2015;13:355–9.
- Ploner M, Gardetto A, Ploner F, Scharl M, Shoap S, Bäcker HC. Foreign rectal body - Systematic review and meta-analysis. *Acta Gastroenterol Belg* 2020;83:61–5.
- Arora A, Jain S, Srivastava A, Mehta M, Pancholy K. Body Packer Syndrome. *J Emerg Trauma Shock* 2021;14:51–2.
- Traub SJ, Hoffman RS, Nelson LS. Body packing-the internal concealment of illicit drugs. *N Engl J Med* 2003;349:2519–26. [\[CrossRef\]](#)