

ISSN 2147 – 0758

# KOCAELİ TIP DERGİSİ

Kocaeli Medical Journal

CİLT 11 SAYI 2 YIL 2022

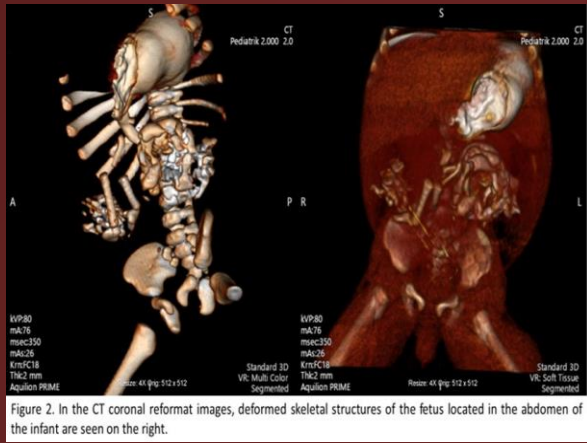
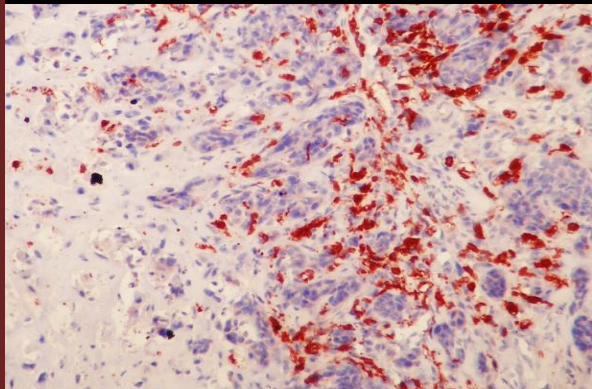
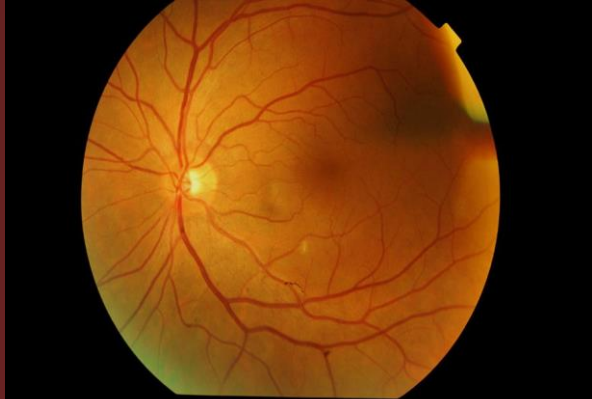


Figure 2. In the CT coronal reformat images, deformed skeletal structures of the fetus located in the abdomen of the infant are seen on the right.



*Small Bowel Obstruction due to Phytobezoar*

*Relationship between 25-hydroxyvitamin D Level and Idiopathic Premature ventricular Complexes*

*Akciğer Tüberküloz Olgularımızın Klinik, Radyolojik Bulguları ve Yan Etki Profillerinin Değerlendirilmesi, Tek Merkez Sonuçları*

*Fetus-in-fetu: Disguising Lymphocyst*

*Üniversite Öğrencilerinde Algılanan Stres Düzeyi ile Yeme Farkındalığı Arasındaki İlişkinin Belirlenmesi*

*Evaluation of Clinical Symptoms in Carbon Monoxide Poisoning with Biochemical Parameters*

*Knowledge Attitudes and Practices of Pregnants about the Influenza Vaccine*

*Biyopsi Sonrası Gelişen Sistemik İnflamatuvar Yanıtta, Biyopsi Öncesi İnflamatuvar Yanıt Biyomarkerlerinin Prediktif Değeri*

*May Covid-19 Disease Cause Renal Infarction in Young People without Comorbidity?*

*Kounis Sendromu*

*The Effect of Nintedanib on Acute Exacerbations of Idiopathic Pulmonary Fibrosis*

*Procedural and Short-Term Results of Percutaneous Ventricular Septal Defect Closure in Adolescents and Adults*

*Investigation of CD40 -1C>T Genetic Variant and sCD40 Levels in Colorectal Cancer*

*Carotid Artery Stenting: Experiences of a Neurology Department*

*Can Peripheral Blood Parameters Be a Prognostic Factor in Patients with EGFR Positive Lung Adenocarcinoma?*

*Meme Karsinomlarında Dendritik Hücrelerde CD1a Boyanması ile Diğer Prognostik Parametrelerin Karşılaştırılması*

*Evaluation of Treatment Responses of COVID-19 Patients Receiving Hydroxychloroquine Treatment: a Retrospective Analysis in a Tertiary Reference Hospital in Turkey*

*Donor Renal Artery Diameter (RAD) is Associated with Graft Function in Kidney Transplantation*

*Porous Polyethylene Implants in Orbital Floor Reconstruction: Outcome and Complications*

*Biomarkers of Renal and Overall Survival in Patients with Granulomatosis Polyangiitis*

*Chordomas of the Head and Neck Region*