

Dev İnsizyonel Hernilerde Modifiye Dick Yöntemi: Tek Merkez Deneyimi

Modified Dick Procedure in Giant Incisional Hernia, a Single Center Experience

Mehmet Aslan¹, Acar Aren²

¹Sağlık Bilimleri Üniversitesi Derince Eğitim ve Araştırma Hastanesi, Cerrahi Onkoloji Kliniği, Kocaeli, Türkiye

²Sağlık Bilimleri Üniversitesi İstanbul Eğitim ve Araştırma Hastanesi, Genel Cerrahi Kliniği, İstanbul, Türkiye

ÖZ

GİRİŞ ve AMAÇ: Günümüzde tıp alanında ki gelişmelerin artmasıyla minimal invaziv girişimler daha yaygın kullanılmaktadır. Buna rağmen insizyonel herni oluşumu halen büyük problem teşkil etmektedir. İnsizyonel hernilerin tedavisi cerrahidir. Seçilecek cerrahi teknik, kullanılacak materyal değişiklik göstermektedir. Hiçbir cerrahi yaklaşım nüks riskini ortadan kaldırmayacağından insizyonel hernilerin cerrahisi konusundaki tartışmalar devam edecektir. Çalışmamızın amacı Modifiye Dick Takviye yönteminin insizyonel herni onarımındaki yerini belirlemektir.

YÖNTEM ve GEREÇLER: Kliniğimizde Ocak 2007 - Ocak 2013 yılları arasında insizyonel herni tanısıyla ameliyat olan hastalar retrospektif olarak taranmıştır. Modifiye Dick Takviye yöntemi uygulanmış 40 hasta çalışmaya dahil edilmiştir. Aynı yıllarda benzer demografik özelliklere sahip, benzer bir yaklaşım olan Onlay meshle onarım yapılan 40 hasta kontrol grubu amacıyla randomize seçilmiştir.

BULGULAR: Çalışmadaki iki grup karşılaştırıldığında; demografik veriler, geçirilmiş ameliyat sayısı, önceki ameliyatlarında uygulanan onarım tipi, ameliyat süresi, hastanede yatış süresi açısından 2 grup arasında istatistiksel anlamlı fark saptanmamıştır. Modifiye Dick Takviye grubunda defekt boyutu ortalama 9.3 cm (6-16 cm) iken, Onlay mesh ile onarım grubunda ortalama 3.9 cm (2-12 cm) saptanmıştır. İki grup arasında istatistiksel anlamlı fark vardır ($p < 0.001$). Modifiye Dick Takviye ve Onlay meshle onarım grupları arasında komplikasyon, morbidite ve mortalite açısından istatistiksel olarak fark izlenmemiştir.

TARTIŞMA ve SONUÇ: Modifiye Dick Takviye; Onlay mesh ile onarım ile karşılaştırıldığında hastalarda ek morbidite ve mortaliteye neden olmamaktadır. Kullanılan cerrahi teknik nedeni ile daha geniş defektlerde uygulanmasına rağmen operasyon süresini uzatmamıştır. Fasya defektinin primer kapatılamayacağı olgularda fasyanın herni üzerine yeniden konumlandırılmasıyla herni kesesiyle kullanılan mesh materyalinin temasını önlemektedir. Bu nedenle bu teknik fasya defektinin primer kapatılamayacağı dev insizyonel hernilerde poliprolen mesh kullanımı planlanıyorsa yararlı olabilir.

Anahtar Kelimeler: insizyonel herni, modifiye dick takviye, dev herni

ABSTRACT

INTRODUCTION: Minimally invasive interventions are widely used recently. However, incisional hernia is still a problem. Discussions will continue about the surgical treatment since there isn't any technique able to eliminate the risk of recurrence. Here we aimed to determine the role of Modified Dick technique in incisional hernia repair.

METHODS: Patients; operated for incisional hernia between January 2007 and January 2013 in our clinic were screened retrospectively. Forty patients who underwent Modified Dick operation were included in the study and 40 patients with similar demographic features and treated with onlay mesh approach were randomized as control group.

RESULTS: There was no statistically significant difference between groups in terms of demographic data, number of previous operations, operation duration and length of hospital stay. The mean defect size was detected as 9.3 cm (6 to 16 cm) in the Modified Dick repair group while 3.9 cm (2-12 cm) in the latter group with a statistical significance of p value < 0.001 . There was no statistically significant difference in terms of complication, morbidity and mortality.

DISCUSSION and CONCLUSION: Modified Dick Technique did't cause additional morbidity and mortality compared with onlay mesh repair. Although it was applied to larger defects, it did't prolong operation time. In cases where the defect can't be closed primarily, the technique prevents the contact of the mesh with the hernia sac by repositioning of fascia over the sac. Therefore this technique can be useful if polypropylene mesh is planned to be applied in cases where the defect can't be closed properly, especially in giant incisional hernias.

Keywords: incisional hernia, modified dick repair, giant hernia

İletişim / Correspondence:

Dr. Mehmet Aslan

Sağlık Bilimleri Üniversitesi Derince Eğitim ve Araştırma Hastanesi, Cerrahi Onkoloji, Kocaeli, Türkiye

E-mail: ege_mehmetaslan@hotmail.com

Başvuru Tarihi: 13.02.2019

Kabul Tarihi: 03.08.2019

INTRODUCTION

Minimally invasive interventions are more widely used with the advances in medicine, recently. However, incisional hernia formation is still a major problem. Incisional hernia formation is reported up to 10-12% in several studies, mostly in patients with previous median and pararectal incision (1-3).

Surgical treatment requires primary repair or reinforcement with prosthetic materials. Repairing with prosthetic material may be with open or minimally invasive approach. Recurrence rate is decreased below 10% with the help of the prosthetic materials placed today (4). On the other hand, incisional hernias with a large defect and multiple recurrences cause more problems in terms of treatment. Therefore, we aimed to determine the role of Modified Dick technique in incisional hernia repair especially in giant incisional hernias in this study.

METHODS

Patients who were operated for incisional hernia between January 2007 and January 2013 in University of Health Sciences İstanbul Training and Research Hospital were screened retrospectively. Forty patients who underwent Modified Dick operation were included in the study. In the same period, 40 patients who had similar demographic features and were treated with onlay mesh with an open surgical approach were randomized as the control group. In this study patients are divided into two groups as Modified Dick repair (group 1) (n:40) and onlay mesh repair (group 2) (n:40).

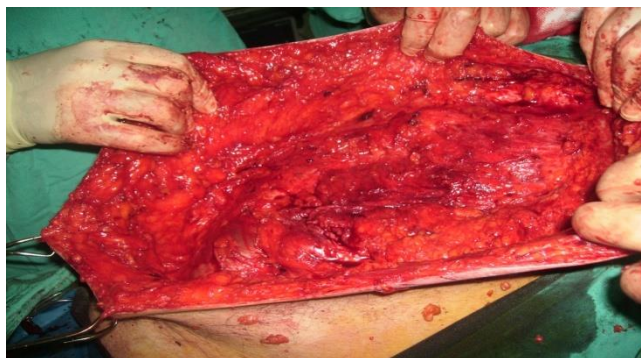This study was approved by ethics committee of the University of Health Sciences İstanbul Training and Research Hospital (2013/241). All subjects provided written informed consent.

Surgical Technique

With onlay mesh repair method, the hernia sac is dissected until the solid fascia is reached. Then the fascia is sutured primarily and reinforced with a mesh material. Tension may occur in the fascia during primary closure.

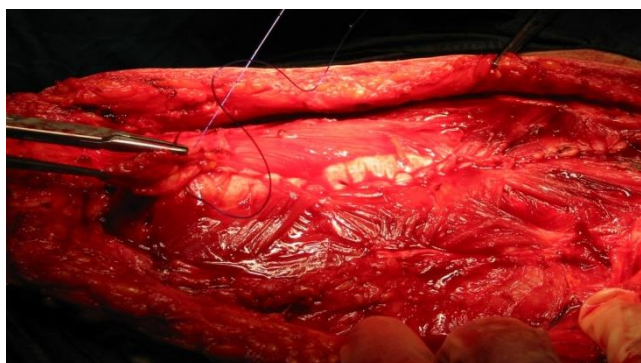
The Modified Dick method is like open onlay mesh repair but differs from this method by technical differences such as reduction of the hernia sac without opening and closure of the fascia without creating tension.

Modified Dick Technique: This technique is a modification of the original Dick method. In this method tension-free repair is aimed by using a polypropylene mesh instead of the sutures that are placed for repair in the original Dick technique. In the operation, a skin incision is made according to the size of the hernia and excessive skin is removed. The subcutaneous adipose tissue should be dissected at least 3 cm distant from the defect margins until an intact fascia is seen (Picture 1).



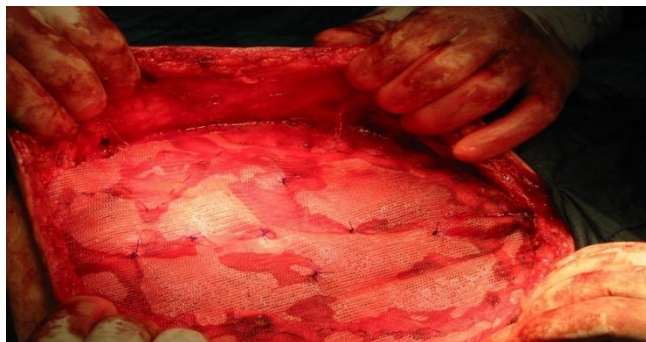Picture 1: Modified Dick Repair: Removal of the old incision scar and dissection up to intact fascia

The fascia is incised 2 cm away from the defect margins. Then, the fascia is inverted and closed with nonabsorbable suture material in continuous manner. Therefore tension-free closure of the fascia is achieved (Picture 2).



Picture 2: Modified Dick Repair: Closure of the inverted fascia with a continuous manner over the hernia sac.

Meanwhile the hernia sac is reduced back into the peritoneal cavity. Polypropylene mesh is then placed on the abdominal fascia without tension. The mesh is fixed to the margins of external oblique muscle fascia (Picture 3).



Picture 3: Modified Dick Repair: Placement and fixation of the polypropylene mesh

Statistical Method

The Mann-Whitney U test, chi-square test/Fisher's test and Student T test were used where appropriate to compare the two groups. Statistical analysis was performed using SPSS v.15.0 (SPSS inc., Chicago, IL, USA). P value<0.05 was considered statistically significant.

RESULTS

Of the 80 patients included for this study, 27 were male (33.8%) and 53 were female (66.3%). The study population had a mean age of 62.1 years (range, 38-84 years).

The operation time was similar between the two groups (45.3 min-46.6 min) (p: 0.741). The mean size of the fascia defect was 9.3 cm in patients with Modified Dick repair group and 3.9 cm in the other patient group. There was statistically significant difference between two groups (p <0.001). Although larger fascia defects were repaired, the duration of operation was not increased in patients treated with Modified Dick technique. The mean length of hospital stay was 2.7 days. The mean follow-up period was 43.7 months (range 3-84 months).

Table 1. Comparison of the two groups summarized

		Numeral	Mean	Median	Standard deviation	Minimum	Maximum	P
Hernia formation time (years)	Whole Group	80	3.5	2	3.3	1	20	0.193
	Modified Dick	40	4.0	2.5	3.5	1	15	
	Polypropylene Mesh	40	3.0	2	3.1	1	20	
Number of previous operations	Whole Group	80	2.4	2	0.8	2	6	0.062
	Modified Dick	40	2.5	2	0.8	2	6	
	Polypropylene Mesh	40	2.3	2	0.8	2	6	
Defect size (cm)	Whole Group	80	6.6	7	3.7	2	16	<0.001
	Modified dick	40	9.3	8.5	2.6	6	16	
	Polypropylene Mesh	40	3.9	3	2.4	2	12	
Duration of operation (min)	Whole Group	80	45.9	45	12.1	30	95	0.741
	Modified Dick	40	45.3	40	9.8	30	70	
	Polypropylene Mesh	40	46.6	45	14.1	30	95	
Length of stay (day)	Whole Group	80	2.7	1	3.7	1	22	0.511
	Modified Dick	40	3.0	1.5	3.9	1	18	
	Polypropylene Mesh	40	2.4	1	3.5	1	22	

When the postoperative data were evaluated; A total of 14 patients (35%) with Modified Dick technique and 15 patients (37.5%) with onlay mesh

repair had complications. Wound site infection was observed in 8 patients (20%) in the first group and in 6 patients (15%) in the latter group. Five patients had prolonged ileus, but no cases needed

reoperation. Patients with Modified Dick technique did not have bowel injury or fistula. In the group undergoing onlay mesh repair, bowel injury occurred in 2 patients (5%), but no fistula developed in any of them. There was no statistically significant difference between the two

groups (p: 0.494).

Although some of the patient's (8%) had suffered from pain, this complaint was mostly temporary.

There was no significant difference between the groups in terms of recurrence (0 -5%) (p: 0.494).

Table 2. Summarizes the complications and statistical differences between the groups.

	Modified Dick Technique(grup1)	Polypropylene Mesh Repair(grup 2)	P
	n (%)	n (%)	
Hematoma	6 (15.0)	6 (15.0)	1.000
Seroma	7 (17.5)	7 (17.5)	1.000
Chronic pain	4 (10.0)	2 (5.0)	0.675*
Infected seroma	6 (15.0)	4 (10.0)	0.499
Mesh removal	2 (5.0)	1 (2.5)	1.000*
Prolonged ileus	3 (7.5)	2 (5.0)	1.000*
Bowel fistula	-	-	-
Deep venous thrombosis	-	-	-
Bowel injury	0 (0.0)	2 (5.0)	0.494*
Pulmonary complications	5 (12.5)	3 (7.5)	0.712*
Cardiovascular complications	-	-	-
Infection	8 (20.0)	6 (15.0)	0.556
Morbidity	14 (35.0)	15 (37.5)	0.816
Mortality	-	-	-
Recurrence	0 (0.0)	2 (5.0)	0.494*
Subcutaneous necrosis	2 (5.0)	1 (2.5)	1.000*

Chi-square test Fisher test*

DISCUSSION

Incidence of incisional hernia is approximately 4-10% in patients undergoing abdominal surgery (5). It is significantly less common after laparoscopic procedures compared to open surgery (4.3 vs. 10.1%) (6).

The most important cause of postoperative hernia formation is wound infection. Wound infection causes deterioration of the fascia integrity. The hernia is formed due to disordered fascia. Once incisional hernia develops, it increases in size over time. Incisional hernia may cause life-threatening conditions such as obstruction, strangulation, skin necrosis and perforation. Therefore, its treatment is surgical repair.

Many difficulties are encountered in the repair of incisional hernias. These patients have more than one previous operative history, and the herniated organs are located extra-abdominally. The abdominal cavity retracts, the size of the fibrotic hernia ring increases.

After surgical interventions complications can be

observed frequently. In the literature, wound complications such as hematoma, seroma or infection after incisional hernia repair have been reported between 0-36% (7). Complications were associated with longer length of stay. In open ventral hernia repair, the average length of stay is reported to be 5-9 days (8-10).

Giant incisional hernias are observed to have unsatisfactory recurrence rate, prolonged operative time, length of stay and have a higher rate of wound site complications, due to the extent of dissection (11-13). Although Modified Dick repair group had wider fascia defect (mean 9.3 cm) in our study, the operation time did not increase due to the surgical technique used. Similarly, there was no increase in wound site complications and length of hospital stay. This suggests that this technique can be used safely in the patient group with large incisional hernia.

The most important complication of incisional hernia repair is recurrence of hernia. As mentioned earlier, infection is the most important risk factor of recurrence (4). Wound infection and wound

complications are associated with recurrence (14). Recurrences may occur along the border of the mesh in patients without wound infection. The reason for this is the inadequate width of the mesh. The mesh should cover both all defects and should extend at least 4-5 cm in all directions on the solid fascia. The location of the mesh is also an important factor in hernia recurrences. Israelsson et al. (15) found a recurrence rate of 29.1% with primary suture repair, 19.3% with onlay mesh repair and 7.3% with sub lay mesh repair. In the literature, recurrence is less than 10% in incisional hernia repairs with mesh material (16).

When the mesh material is placed intraperitoneally, adhesions may occur between the intestines and the mesh, resulting in complications such as obstruction, fistula, peritonitis and migration of the mesh into the hollow organs (17). Especially in experimental studies, it has been shown that polypropylene and polyester mesh placed in peritoneum may lead to intestinal obstruction and late fistulas (18). Placing the omentum as a barrier between the intestines and the mesh is a precaution against these complications (19). Bauer (20) and colleagues reported a 3% intestinal injury rate, while McLanahan (21) and colleagues reported a rate of 1.8%. In our study, bowel injury occurred in 5% of cases who treated with onlay mesh repair. Patients with Modified Dick technique did not have any bowel injury or fistula. Reducing the hernia sac into the abdomen, repositioning the fascia on the defect without tension, preventing the peritoneal contact with the mesh may contribute to this situation. With these findings, we consider that this technique can be useful if polypropylene mesh is planned to be used in cases where the fascia defect cannot be closed properly.

In conclusion: Modified Dick technique did not cause additional morbidity and mortality to patients when compared with onlay mesh repair. It has a low recurrence rate with similar complication rate. In addition, because of the surgical technique used, the contact of the mesh material with the hernia sac is prevented, and the operation time is not prolonged even though it is applied to patients with a larger defect.

As a result, this technique can be useful in cases where the fascia defect cannot be closed properly, especially in giant incisional hernias.

The low number of patients in the study and short follow-up period are the missing aspects of this study. Thus, additional prospective randomised large-scale studies are required to establish the effectiveness of this procedure.

Disclosures

Peer-review: Externally peer-reviewed.

Conflict of Interest: None declared.

REFERENCES

1. Çelik F, Aren A, Göney E, Hızlı F. Büyük insizyonel hernilerin onarımında güvenilir bir yöntem "Dick Yöntemi. *Ulusal Cerrahi Dergisi* 1990; 6(1): 31-3.
2. Leaper DJ, Pollock AV, Evans M. Abdominal wound closure: a trial of nylon, polyglycolic acid and steel sutures. *Br J Surg* 1977 Aug; 64(8): 603-6.
3. Mudge M, Hughes LE. Incisional hernia: a 10 year prospective study of incidence and attitudes. *Br J Surg* 1985 Jan; 72(1): 70-1.
4. Millikan KW. Incisional hernia repair. *Surg Clin North Am* 2003 Oct; 83(5): 1223-34.
5. Dietz UA, Menzel S, Lock J, Wiegand A. The Treatment of Incisional Hernia. *Dtsch Arztebl Int* 2018 Jan 19; 115(3): 31-7.
6. Kössler-Ebs JB, Grummich K, Jensen K, Hüttner FJ, Müller-Stich B, Seiler CM et al. Incisional Hernia Rates After Laparoscopic or Open Abdominal Surgery-A Systematic Review and Meta-Analysis. *World J Surg* 2016 Oct; 40(10): 2319-30.
7. Schumpelick V, Conze J, Klinge U. Preperitoneal mesh-plasty in incisional hernia repair. A comparative retrospective study of 272 operated incisional hernias. *Chirurg* 1996 Oct; 67(10): 1028-35.
8. Holzman MD, Purut CM, Reintgen K, Eubanks S, Pappas TN. Laparoscopic ventral and incisional hernioplasty. *Surg Endosc* 1997 Jan; 11(1): 32-5.
9. Park A, Birch DW, Lovrics P. Laparoscopic and open incisional hernia repair: a comparison study. *Surgery* 1998 Oct; 124(4): 816-21; discussion 821-2.
10. Carbajo MA, Martp del Olmo JC, Blanco JI, Toledano M, de la Cuesta C, Ferreras C et al. Laparoscopic approach to incisional hernia. *Surg Endosc* 2003 Jan; 17(1): 118-22.
11. Kaufmann R, Halm JA, Eker HH, Klitsie PJ, Nieuwenhuizen J, van Geldere D et al. Mesh versus suture repair of umbilical hernia in adults: a randomised, double-blind,

- controlled, multicentre trial. *Lancet* 2018 Mar 3; 391(10123): 860-9.
12. EU Hernia Trialists Collaboration. Mesh compared with non-mesh methods of open groin hernia repair: systematic review of randomized controlled trials. *Br J Surg* 2000 Jul; 87(7): 854-9.
 13. Lindmark M, Strigård K, Löwenmark T, Dahlstrand U, Gunnarsson U. Risk Factors for Surgical Complications in Ventral Hernia Repair. *World J Surg* 2018 Nov; 42(11): 3528-36.
 14. Hesselink VJ, Luijendijk RW, de Wilt JH, Heide R, Jeekel J. An evaluation of risk factors in incisional hernia recurrence. *Surg Gynecol Obstet* 1993 Mar; 176(3): 228-34.
 15. Israelsson LA, Smedberg S, Montgomery A, Nordin P, Spangen L. Incisional hernia repair in Sweden 2002. *Hernia* 2006 Jun; 10(3): 258-61.
 16. Cassar K, Munro A. Surgical treatment of incisional hernia. *Br J Surg* 2002 May; 89(5): 534-45.
 17. Morin B, Bonnamy C, Maurel J, Samama G, Gignoux M. Late intestinal fistula following implantation of parietal abdominal prostheses. *Ann Chir* 2001 Nov; 126(9): 876-80.
 18. Stoppa RE. The treatment of complicated groin and incisional hernias. *World J Surg* 1989 Sep-Oct; 13(5): 545-54.
 19. Mathonnet M, Antarieu S, Gainant A, Preux PM, Boutros-Toni F, Cubertafond P. Postoperative incisional hernias: intra- or extraperitoneal prosthesis implantation?. *Chirurgie* 1998 Apr; 123(2): 154-9; discussion 159-61.
 20. Bauer JJ, Harris MT, Kreel I, Gelernt IM. Twelve-year experience with expanded polytetrafluoroethylene in the repair of abdominal wall defects. *Mt Sinai J Med* 1999 Jan; 66(1): 20-5.
 21. McLanahan D, King LT, Weems C, Novotney M, Gibson K. Retro rectus prosthetic mesh repair of midline abdominal hernia. *Am J Surg* 1997 May; 173(5): 445-9.