

Olgu Sunumu: Erişkin Hastada Karotisi Çevreleyen Servikal Lenfanjiyom Olgusu

A Case Report: Cervical Lymphangioma Encircling the Common Carotid Artery in an Adult Patient

Mahmut Burak Laçın¹, Ahmet Savranlar¹, Altan Kaya², Yasemin Savranlar³

¹Sağlık Bilimleri Üniversitesi Kayseri Sağlık Uygulama ve Araştırma Merkezi, Radyoloji Ana Bilim Dalı, Kayseri, Türkiye

²Sağlık Bilimleri Üniversitesi Kayseri Sağlık Uygulama ve Araştırma Merkezi, Kulak Burun ve Boğaz Hastalıkları Ana Bilim Dalı, Kayseri, Türkiye

³Kayseri Şehir Hastanesi, Histoloji ve Embriyoloji Bölümü, Kayseri, Türkiye

ÖZ

Kistik higroma/Lenfanjiyomlar, yetişkin popülasyonda nadiren görülen lenfatik sistem anormallikleridir. Lenfatik sistemden kaynaklanırlar ve lenfatik vasküler hücrelerin çoğalması sonucu oluşurlar. Genellikle servikal bölgede bulunurlar. Ayrıca aksilla, retroperitoneal, torasik bölgeler ve kasık bölgeleri gibi diğer vücut bölgelerinde de bulunabilirler. Bu olgu sunumunda servikal lenfanjiyomu olan 21 yaşında bir kadın hasta sunuldu.

Anahtar Kelimeler: Lenfanjiom, Karotis Arter, Manyetik Rezonans Görüntüleme

ABSTRACT

Cystic hygroma/Lymphangiomas are lymphatic system abnormalities which are rarely seen in adult population. They arise from lymphatic system and occurs as result of proliferation of lymphatic vascular cells. They are usually located at cervical region. They also can be located at other body regions such as axilla, retroperitoneal, thoracic and inguinal regions. In this case report we present a 21 years old female patient with cervical lymphangioma.

Keywords: Lymphangioma, Carotid Arteries, Magnetic Resonance Imaging

İletişim / Correspondence:

Mahmut Burak Laçın

Sağlık Bilimleri Üniversitesi Kayseri Sağlık Uygulama ve Araştırma Merkezi, Radyoloji Ana Bilim Dalı, Kayseri, Türkiye

E-mail: mahmutburak.lacin@sbu.edu.tr

Başvuru Tarihi: 12.06.2020

Kabul Tarihi: 18.07.2020

INTRODUCTION

Cystic hygroma/Lymphangiomas are relatively common malformations seen in first years of life as a congenital disorder, but they are rarely seen in adult population (1). They usually occur at head and neck regions. Also they may occur at several regions other than cervical area like axillary, retroperitoneal, thoracic and inguinal regions (2). In adults, the reason of the lymphangiomas is controversial, but they may occur by proliferating of lymphatic vessels due to a precipitating factor such as trauma or infection (3, 4). Because of their cystic nature, other lesions such as branchial cysts, thyroglossal duct cysts or cystic metastatic lymph nodes should be considered in differential diagnosis (5). Ultrasound, CT (Computerized Tomography) and MRI (Magnetic Resonance Imaging) modalities are used with clinical examination to make diagnosis (6). They are usually treated by surgical excision if there is no contraindication to surgery.

Case Report

A 21 year old female patient has admitted Kayseri City Hospital with a painless swelling in her lateral neck which was present for about 2 months before admission. Her complete blood count and biochemical test results were in normal range. She has undergone ultrasound imaging. In ultrasound imaging there was an hypoechoic cystic structure which was enveloping right common carotid artery nearly completely. Also mobile milimetrical components were present in cystic cavity (Figure 1). Coloured – Duplex Doppler Ultrasound Imaging showed no vascularity inside of lesion. Then she has undergone MRI. On MRI images, a lesion was present which lies between right cervical zone IV and carotid bifurcation level. Lesion was hyperintense in T1 and T2 MRI sequences and fat saturated T1 MRI sequence. After intravenous contrast injection, there was subtle contrast enhancing areas were present which occurred because of venous or hemangiomas elements. Lesion's dimensions were measured as 84x30x26 mm. Right common carotid artery had been encircled by the lesion nearly 300 degrees (Figure 2).

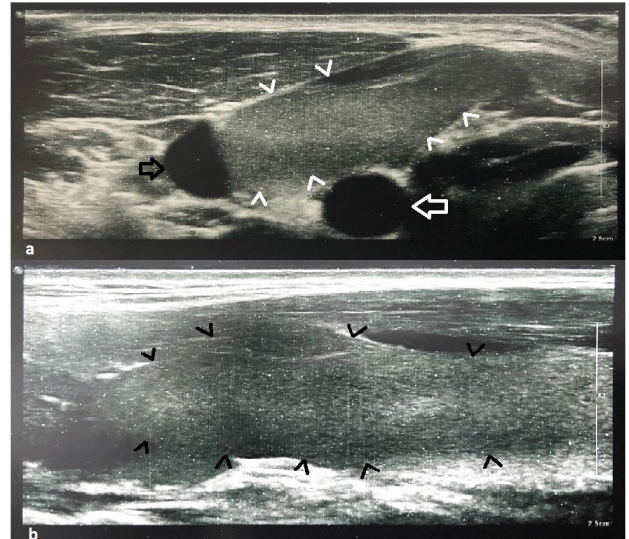


Figure 1. Ultrasound images of cervical lesion in transverse (a) and longitudinal (b) planes. (White arrow: Common Carotid Artery, Black Arrow: Jugular Vein, White and Black Arrowheads: Lymphangioma)

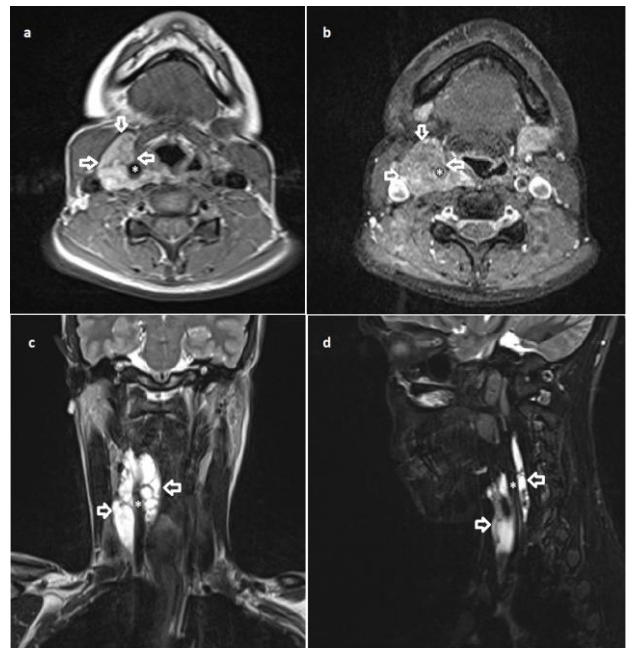


Figure 2. This figure shows the lesion (white arrows) on T1 (a), fat-saturated post-contrast T1 (b), T2 (c) and T2 STIR (d). Note that the right common carotid artery (white asteriks) had been surrounded nearly 300 degrees by the lesion.

As a result of correlation between Ultrasound and MRI findings, we diagnosed this lesion as a cervical lymphangioma. She had a biopsy in another health centre and biopsy results confirmed the lesion as a benign process. She rejected surgical treatment. We present this case to emphasize radiological features of lymphangiomas.

DISCUSSION

Cystic hygroma/Lymphangiomas are generally seen in first years of life as a congenital defect, but they may occur in adults as a result of proliferating lymphatic system cells (1, 7, 8). This proliferation may be connected to some etiological factors such as trauma, infection. They are usually (nearly %70 of all) located at cervical region. Also they may be located at other regions such as axilla, chest wall, shoulder, mediastinum, abdominal wall and thigh (3, 4, 9).

Ultrasound imaging, CT or MRI can be used to diagnose lymphangiomas. Also Doppler Ultrasound Imaging can show vascularity of the lesion as a non-invasive technique. CT and MRI may be superior to the ultrasound in defining the borders between lesions and adjacent structures. Especially T1 and T2 sequences of MRI are useful (6, 10).

Most commonly preferred treatment modality is surgical resection. But treatment modality should be selected according to the relations between the lesion and adjacent structures. Close relationship with vital structures such as carotid artery can make the conditions harder in surgery (10, 11). In these conditions, there are some alternative treatment options. Another option is radiofrequency ablation. Also drainage and sclerotherapy with agents such as triamcinolone, tetracycline, picibanil (OK-432) and bleomycin can be option (12, 13).

In radiological practice, a carotid space mass may be one of the some other tumoral lesions such as lymphangiosarcomas, paragangliomas, schwannomas, lipomas and some other non-tumoral lesions such as aneurysm/pseudoaneurysm, vascular dissection, jugular vein thrombosis (14). To differentiate a lymphangioma from these lesions contrast enhancement pattern on MRI and CT is very important. Significant contrast enhancement refers to hypervascularity of the lesion and this also can be seen on Coloured Doppler Ultrasound imaging.

Lymphangiomas are usually show non-enhancement after contrast injection. They may show mild enhancement if they include venous or hemangiomatous component. Lymphangiomas and paragangliomas (glomus caroticum, glomus jugulare and glomus vagale tumors in carotid space)

show hyper-enhancement pattern on CT and MRI. Also they show hypervascularity on Coloured Doppler Ultrasound Imaging. Lipomas usually don't show contrast enhancement. Differentiating lipomas from lymphangiomas may be based on images which acquired from fat-saturated T1 or STIR (short tau inversion recovery) T2 MRI sequences. Lipomas show hipointensity on these images. Based on these imaging features, a radiologist can make a differential diagnosis (14, 15).

CONCLUSION

Although cervical lymphangiomas are rare lesions in adult population, they should be one of the preliminary diagnoses at cervical mass presentation. Ultrasound imaging, CT and MRI modalities are useful in diagnosis of lymphangiomas.

Conflict of Interests

Authors declare no conflicts of interest regarding the publication of this paper.

REFERENCES

1. Pankhania M, Judd O, Conboy PJ. A frog in the throat? An expansile mass presenting in the neck with dysphonia. *Case Reports*. 2011;2011:bcr1120103478.
2. Cadena-Piñeros E, Rojas Gutiérrez A. Cervical lymphangioma in adults: case report and current treatment. *Case reports*. 2018;4(1):61-8.
3. Suk S, Sheridan M, Saenger JS. Adult lymphangioma: a case report. *Ear, nose & throat journal*. 1997;76(12):881-3.
4. Aneeshkumar M, Kale S, Kabbani M, David V. Cystic lymphangioma in adults: can trauma be the trigger? *European Archives of Oto-Rhino-Laryngology and Head & Neck*. 2005;262(4):335-7.
5. Schefter RP, Olsen KD, Gaffey TA. Cervical lymphangioma in the adult. *Otolaryngology—Head and Neck Surgery*. 1985;93(1):65-9.
6. Siegel M, Glazer H, St Amour TE, Rosenthal D. Lymphangiomas in children: MR imaging. *Radiology*. 1989;170(2):467-70.
7. Derin S, Şahan M, Dere Y, Çullu N, Şahan L. Cervical Cystic Hygroma in an Adult. *Case reports in pathology*. 2014;2014.

8. Veeraraghavan G, Denny C, Lingappa A. Cystic Hygroma in an Adult; a case report. *Libyan Journal of Medicine*. 2008;4(4):160-1.
9. Schloss M, Sweet R, Blais C, Tewfik T. Lymphangioma in children. *The Journal of otolaryngology*. 1984;13(2):95-8.
10. Colbert SD, Seager L, Haider F, Evans BT, Anand R, Brennan PA. Lymphatic malformations of the head and neck—current concepts in management. *British Journal of Oral and Maxillofacial Surgery*. 2013;51(2):98-102.
11. Bayram A, Kaya A, Ünsal N, Akay E, Mutlu C. Boyunda dev kistik higroma olgusu. *Journal of Anatolian Medical Research*. 2018;3(1):36-42.
12. Sanlialp I, Karnak I, Tanyel FC, Senocak M, Büyükpamukçu N. Sclerotherapy for lymphangioma in children. *International journal of pediatric otorhinolaryngology*. 2003;67(7):795-800.
13. Ryoma Y, Moriya Y, Okamoto M, KANAYA I, SAITO M, SATO M. Biological effect of OK-432 (picibanil) and possible application to dendritic cell therapy. *Anticancer research*. 2004;24(5C):3295-302.
14. Chong V, Fan Y. Pictorial review: Radiology of the carotid space. *Clinical radiology*. 1996;51(11):762-8.
15. Chengazi HU, Bhatt AA. Pathology of the carotid space. *Insights into imaging*. 2019;10(1):21.