

# Non-obstructive Giant Gastric Trichobezoar: A Case of Rapunzel Syndrome

## Obstrüktif Olmayan Dev Gastric Trikobezoar: Bir Rapunzel Sendromu Olgusu

Şener Balas<sup>1</sup>, Oskay Kaya<sup>1</sup>, Nurhan Fıstıkçı<sup>2</sup>

<sup>1</sup>General Surgery Clinics, Dışkapı Teaching and Research Hospital, Ankara, Turkey; <sup>2</sup>Psychiatry Clinics, Ardahan State Hospital, Ardahan, Turkey

### ABSTRACT

Bezoars are resulted from undigested foods or indigestible foreign materials passed into the gastrointestinal canal. Particularly, mentally ill patients eating foreign materials such as hair, wood or stones have bezoars. In addition, patients with gastric or intestinal bypass surgery may have bezoars. Rapunzel Syndrome is inspired from the tales of Grimm Brothers and constitutes a trichobezoar and a ball of hair hanging down and caus surgery anding obstruction. We presented a giant gastric trichobezoar case without obstruction and weight loss.

**Key words:** bezoars; eating; intestinal obstruction; weight loss

### ÖZET

Bezoarlar sindirilmemiş besinler ya da sindirilemeyen yabancı cisimlerin sindirim kanalında oluşturdukları yapılardır. Özellikle mental problemi olan hastalarda saç, tahta parçaları, taşlar vb. cisimler bezoar oluşturabilir. Gastrik veya intestinal bypass cerrahi geçirmiş hastalarda da gelişebilirler. Rapunzel Sendromu, Grimm Kardeşlerin masalından esinlenerek trikobezoar ve bundan sarkan saç kuyruğu ve buna bağlı olarak gelişen obstrüksiyon olgularını tanımlar. Bu yazıda, obstrüksiyon ve kilo kaybına yol açmadan büyümüş bir trikobezoar olgusunu sunmayı amaçladık.

**Anahtar kelimeler:** bezoarlar; yeme; barsak tıkanıklığı; kilo kaybı

### Introduction

Trichotillomania was first described by Hallopeau a French dermatologist in 1889. It occurs as a result of forced and unavoidable impulsive disorder in patients suffering from their own hair pulling<sup>1</sup>. Trichotillomania word comes from the Greek words trichs: hair, tillo: pulling mania: madness. Illness is classified in the

impulse control disorders<sup>1,2</sup>. Many researchers state that 20% of patients pulling hairs, also chews and swallows them<sup>2</sup>. Even in one case, the patient was pulling his dog's hairs and eating them<sup>1,2</sup>. In this report we aimed to present a non-obstructive giant trichobezoar without weight loss.

### Case Report

A 17 year-old female patient was admitted to surgical outpatient clinic for abdominal pain and stress. The patient's body mass index (BMI) was 28 and her nutritional status was normal.

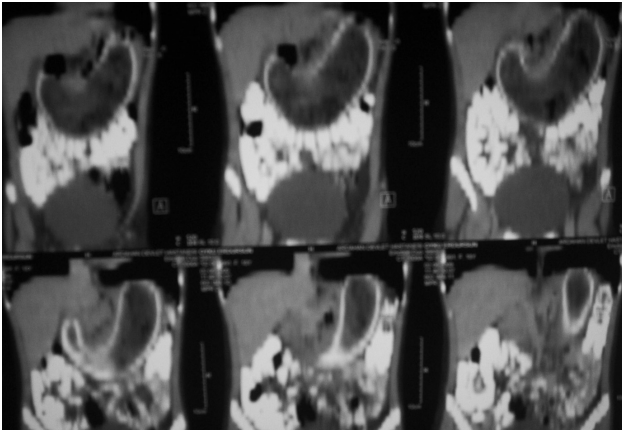
Physical examination revealed a good general condition with normal vital signs. During the abdominal examination we observed a painless mass in the left upper quadrant. The rest of the physical examination was unremarkable.

Biochemical tests and complete blood count were normal. Ultrasound and computed tomography examinations revealed a space occupying lesion that could possibly be trichobezoar (Figure 1). Thus we performed an upper gastrointestinal endoscopic exploration and found out a trichobezoar filling the stomach and extending into the duodenum.

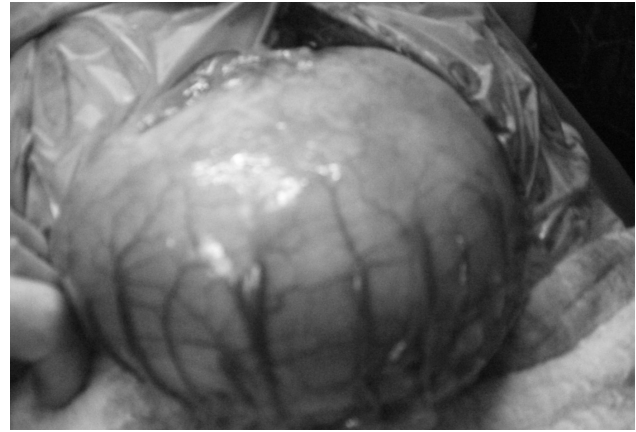
We could not fragment the bezaor and thus, had to perform surgical exploration. The patient was operated by a midline incision. During the surgical process we observed that the stomach was elongated and pithotic (Figure 2). We also palpated the gastric bezoar and demonstrated that it was extending in to the duodenum. The bezoar was pulled out from the gastrotomy incision made on the anterior wall of stomach. Gastrotomy was closed by two layers running absorbable suture (Figures 3, 4).

Uzm. Dr. Şener Balas, İrfan Baştuğ Cad. No: 12 Altındağ, Ankara, Türkiye  
Tel. 0312 596 20 94 Email. senerbalas@yaboo.com

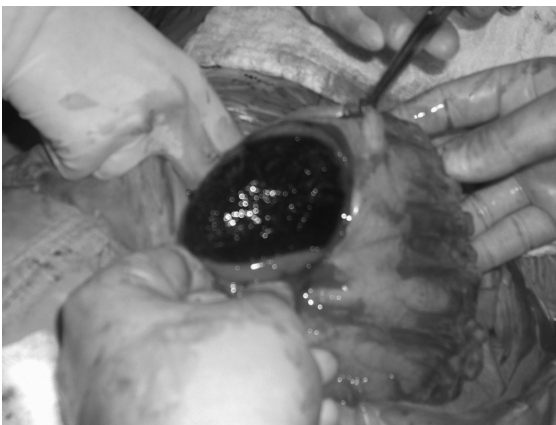
Geliş Tarihi: 11.07.2014 • Kabul Tarihi: 26.07.2014




**Figure 1.** Tomographic view of the bezoar.



**Figure 2.** The image of the stomach during the operation.



**Figure 3.** Removal of the bezoar out of the stomach.



**Figure 4.** Gross appearance of the bezoar.

Postoperative period was uneventful and the patient began to ingest oral clear liquids on the third day. She was discharged on the fifth day. On the first month follow up visit, she was well and symptom free.

## Discussion

Trichophagia begins with putting the hairs between the teeth and following chewing and swallowing many hairs get down into the stomach. This condition of the gastrointestinal lumen is called trichobezoar<sup>1,2</sup>.

Our patient was eating her hair during stressed conditions. We could not provide information about the time of the initiation of the symptoms. Generally, these patients have alopecic areas on their scalp, however we could not find those kind of areas on the scalp of our patient. Bezoars are frequent in second decade especially among adolescent girl patients. To our knowledge, the medical literature does not include an adult patient with Rapunzel Syndrome<sup>2</sup>.

Most common complaints of patients are abdominal pain and weight loss. Fullness in the abdomen, nausea and vomiting are common symptoms<sup>2,3</sup>. In our case main complaint was abdominal pain, however, it was remarkable that she has no complaints about eating problems or intestinal passage. Bezoars can lead gastric and intestinal ulcers, bleeding or perforations<sup>4</sup>. If sufficient enlargement occurs, bezoars can lead pancreatitis, colonic obstructions or chronic anemia due to gastric ulcers<sup>2,4,5</sup>.

The diagnosis of a bezoar is frequent and easy in adult patients who have previous gastric surgery; however diagnostic clues are usually lacking during childhood. Gastric bezoars must be considered as one of the probable diagnosis in a child or an adolescent patient who has a palpable mass in the left upper quadrant<sup>5</sup>.

Although, it is not a specific finding, a mild anemia and leucocytosis may accompany the condition<sup>5</sup>. In the cases with obstructive symptoms, there may be fluid and

air levels in plain films<sup>6</sup>. Intraluminal highly echogenic air line and its posterior acoustic shadow are monitored in ultrasonography and this view distinguishes it from the gas or food scraps<sup>6</sup>. Abdominal computed tomography may help to rule out the calcified tumors<sup>6</sup>. We used both imaging modalities and determined the bezoar with ultrasound and then confirmed the diagnosis with tomography.

Endoscopy is an efficient diagnostic technique for bezoars located in the upper gastrointestinal channel, and pulling them out may be therapeutic. Only 25% of the bezoars determined endoscopically can be seen through barium films<sup>7</sup>. In our case, a bezoar almost completely filling the stomach and extending into the duodenum was detected through gastroscopy. Since the bezoar was too big to be broken down endoscopically, surgery was planned.

Although there are some medical treatment choices for phytobezoars, trichobezoars fail to benefit from medical treatments<sup>8</sup>. With the technological developments, extracorporeal lithotripsy, endoscopic breaking down, crushing by laser or laparoscopic pulling down have become possible. However, surgery is still accepted as the most efficient method for complicated large trichobezoars<sup>9</sup>.

Breakings down of the bezoars via laparoscopically inserted gastric port were described. Although the method has longer procedure time, it has smaller incisions and lower peritoneal contamination risks<sup>9</sup>.

Rapunzel Syndromes are rare and can be found as case presentations in the medical literature. Regarding their 3 cases' presentation along with 23 previous ones, Nalk

et al<sup>10</sup> reported that all the patients were surgically treated. Uncontrollable behavioral disorders secondary to certain psychiatric disorders may be associated with the recurrence of the disease. In order to prevent recurrences, appropriate and efficient psychiatric treatment and follow ups are necessary.

## References

1. Millard LG. Trichotillomania In: Lebowitz MG, Heymann WR, Berth-Jones J, Coulson I, editors. *Treatment of Skin Disease: Comprehensive Therapeutic Strategies*, Fourth Edition Elsevier; 2014. p.239, 773–4.
2. Ceylan ME, Çetin M. Araştırma ve Klinik Uygulamada Biyolojik Psikiyatri 3. baskı; Küre İletişim Grubu, İstanbul, 2005:1117–32.
3. Salena BJ, Hunt RH. Bezoars. In: Sleisinger MH, Fordtran JS, editors. *Gastrointestinal disease*. Vol 1 5th ed. Philadelphia: Saunders; 1993:758.
4. Perez E, Santana JR, Garcia G. Gastric perforation due to trichobezoar in an adult. *Cir Esp* 2005;78:268–70.
5. İslek A, Sayar E, Yılmaz A. A rare outcome of iron deficiency and pica: Rapunzel syndrome in a 5-year-old child iron deficiency and pica. *Turk J Gastroenterol* 2014;25:100–2.
6. Mathai J, Chacko J, Kumar T, et al. Rapunzel syndrome: a diagnosis overlooked. *Acta Paediatr* 2007;96:135–8.
7. Wijetilleke A, Sarkan M, Kamat-Nerikar R. Vomiting in a girl with autism. *Clin Pediatr* 2009;48:224–7.
8. Ladas SD, Triantafyllou K, Tzathas C, et al. Gastric phytobezoar may be treated by nasogastric Coca-Cola lavage. *Eur J Gastroenterol Hepatol* 2002;14:801–3.
9. Dorn HF, Gillick JL, Stringel G. Laparoscopic intragastric removal of giant trichobezoar. *JLS* 2010;14:259–62.
10. Naik S, Gupta V, Naik S, et al. Rapunzel syndrome reviewed and redefined. *Dig Surg* 2007;24:157–61.