



## Case Report

# Varicella Zoster Fulminant Hepatitis in a Pediatric Patient with Leukemia: Recovery Without Liver Transplantation

Fatma Ilknur Varol,<sup>1</sup> Arzu Akyay,<sup>2</sup> Kamuran Karaman,<sup>3</sup> Nese Karadag<sup>4</sup>

<sup>1</sup>Department of Pediatric Gastroenterology and Hepatology, Inonu University Faculty of Medicine, Malatya, Turkiye

<sup>2</sup>Department of Pediatric Hematology and Oncology, Inonu University Faculty of Medicine, Malatya, Turkiye

<sup>3</sup>Department of Pediatric Hematology and Oncology, Yuzuncu Yil University, Van, Turkiye

<sup>4</sup>Department of Pathology, Inonu University Faculty of Medicine, Malatya, Turkiye

### Abstract

Acute liver failure is a sudden and rapidly developing acute liver injury, with impaired metabolic-synthetic function of the liver, with or without encephalopathy that causes multi organ failure in a healthy person. Acute liver failure can develop due to many different reasons. In this report, we presented a child patient who received chemotherapy with the diagnosis of acute lymphoblastic leukemia and developed acute liver failure after Varicella-Zoster Virus infection. In this patient, liver transplantation could not be performed due to active viral infection, and she improved after acyclovir and supportive care with plasmapheresis. To the best of our knowledge, this is the only immunosuppressed child patient in the literature who improved from acute liver failure after Varicella-Zoster Virus infection without liver transplantation.

**Keywords:** Varicella-Zoster Virus, acute lymphoblastic leukemia, acute liver failure, plasmapheresis

Please cite this article as "Varol FI, Akyay A, Karaman K, Karadag N. Varicella Zoster Fulminant Hepatitis in a Pediatric Patient with Leukemia: Recovery Without Liver Transplantation. J Inonu Liver Transpl Inst 2023;1(3):113–116".

Acute liver failure (ALF) is a sudden and rapidly developing acute liver injury, with impaired metabolic-synthetic function of the liver with or without encephalopathy. Although there is no definitive description of ALF in children, it has been defined by the "Acute Liver Failure Study Group (ALFSG)" as the presence of biochemical findings indicating ALF, with or without encephalopathy and a coagulopathy that cannot be corrected (INR>1 and PT>15 seconds, in patients with encephalopathy and INR>2 and PT>20 seconds in patients without encephalopathy) in an individual without a previously known chronic liver dis-

ease.<sup>[1]</sup> ALF can develop due to many different reasons. The most common causes of ALF in children are viral hepatitis, drugs, chemicals, toxins, ischemia, venous thrombosis (hepatic vein, portal vein), autoimmune hepatitis, and metabolic diseases. In many cases, the etiology cannot be determined. Viral causes of acute liver failure include Hepatitis A-E, Varicella-Zoster Virus (VZV), Cytomegalovirus (CMV), Herpes Simplex Virus (HSV), Epstein-Barr Virus (EBV), and Adenovirus. VZV infections are potentially life-threatening in immunosuppressed patients, especially those with acute lymphoblastic leukemia (ALL).<sup>[2]</sup> In the literature, 9 cases (8

**Address for correspondence:** Fatma Ilknur Varol, MD. Department of Pediatric Gastroenterology and Hepatology, Inonu University Faculty of Medicine, Malatya, Turkiye

**Phone:** +90 555 106 33 44 **E-mail:** drivarol@yahoo.com

**Submitted Date:** 11.12.2023 **Revised Date:** 03.01.2024 **Accepted Date:** 03.01.2024 **Available Online Date:** 23.01.2024

©Copyright 2023 by Journal of Inonu Liver Transplantation Institute - Available online at [www.jilti.org](http://www.jilti.org)

**OPEN ACCESS** This is an open access article under the CC BY-NC license (<http://creativecommons.org/licenses/by-nc/4.0/>).



adult, 1 child) of acute hepatic impairment due to hepatitis secondary to VZV has been reported. Of these patients, only 2 adult patients survived.<sup>[3]</sup>

In this report, we presented a child patient who received chemotherapy with the diagnosis of acute lymphoblastic leukemia (ALL) and developed ALF after VZV infection. In this patient, liver transplantation couldn't be done due to active viral infection, and she improved after acyclovir and supportive care. To the best of our knowledge, this is the only immunosuppressed child patient who improved from acute liver failure after VZV infection without liver transplantation.

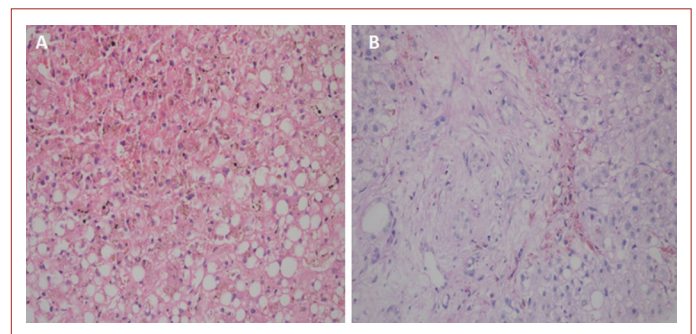
## Case Report

A 15-year-old girl, who was treated with chemotherapy with the diagnosis of ALL, admitted to the outer center with skin rash developed 15 days after receiving her last chemotherapy and was diagnosed with varicella. Laboratory tests were, AST 5500 U/L, ALT (alanine aminotransferase) 1200 U/L, total bilirubin 8.1 mg/dl, direct bilirubin 6.7 mg/dl, and INR 7. The patient was referred to our center for evaluation of liver transplantation with the prediagnosis of ALF, which developed after the diagnosis of varicella. In the patients' history, it has been learned that the patient have not had varicella vaccine and varicella infection before. On physical examination, the patient had a poor general condition with icteric skin color and scleras, vesicular eruptions at different ages spread over entire body, and diffuse rales in the lungs. The liver was palpable 2-3 cm under the ribs. There was no encephalopathy. In the complete blood count, white blood cell was 8300/mm<sup>3</sup>, hemoglobin 8 gr/dl, and platelet 11000/mm<sup>3</sup>. INR was 4.32. In biochemical examination; Glucose 52 mg/dl, aspartate aminotransferase (AST) 7012 U/L, alanine aminotransferase (ALT) 2646 U/L, total bilirubin 8.48 mg/dl, direct bilirubin 6.21 mg/dl, gamma-glutamyl transpeptidase (GGT) 470 U/L, alkaline phosphatase (ALP) 275 U/L, sodium 132 mmol/L, phosphorus 2.8 mg/dl, and ammonia was 159 µg/dl. There was bilateral diffuse infiltration on chest X-ray. Serum VZV PCR revealed 1000 copy/ml. Other viral panel, metabolic and toxicological studies for hepatitis were negative. In abdominal ultrasonography revealed hepatomegaly, normal intrahepatic bile ducts, hepatic and portal veins. Administration of acyclovir 30 mg/kg/day iv, N-acetylcysteine 100 mg/kg/day infusion, ursodeoxycholic acid and fat-soluble vitamin supplements were started. The patient's MELD-Na score was 32, and an emergency liver transplant indication was established according to King's College criteria, but liver transplantation could not be performed because the possible high risk of transplant complications due to the disseminated varicella infection. On the third day of hospitalization, AST was 1044

U/L, ALT 443 U/L, total bilirubin 19.6 mg/dl, direct bilirubin 12.6 mg/dl, GGT 348 U/L, ALP 141 U/L, sodium 140 mmol/L, phosphorus 3.1 mg/dl, ammonia 257 µg/dl, and INR was 4.1. The patient with entered stage 2 encephalopathy and mannitol treatment was started for brain edema. Plasmapheresis (single-volume by centrifugation method) was applied to the patient twice a day with 12 hours of interval for a week until encephalopathy resolved. Then plasmapheresis was continued, once a day for a total of 1 month until bilirubin, ammonia and INR levels improved. On the 20<sup>th</sup> day of hospitalization, coagulation parameters returned to normal and liver biopsy was performed. The liver biopsy revealed parenchymal necrosis and steatosis, canalicular and hepatocellular cholestasis, fibrous enlargement, ductular proliferation, and degenerative changes in the ductus epithelium in most of the portal areas (Fig. 1a, b). Acyclovir was continued for three weeks until VZV PCR turned negative. On the 10<sup>th</sup> day of hospitalization, lung functions and in the first month liver function tests returned to normal, and signs of liver failure improved.

## Discussion

VZV is a causative agent of varicella which is a highly contagious but generally a mild disease of childhood age. Its occurrence with acute liver failure is very rare and has high mortality.<sup>[4]</sup> A moderate increase in liver enzymes during VZV infection is usually seen whereas acute, severe hepatitis which leads to hepatic insufficiency is mainly seen in immunosuppressed patients.<sup>[3]</sup> Our patient had normal liver functions after the last chemotherapy session, and had negative viral panels except serum VZV PCR positivity, normal metabolic and autoimmune markers, absence of ischemia in the liver as shown by imaging methods, presence of vesicular rashes in physical examination. So, VZV was thought to be one of the causative factors in the development of ALF. However, toxic effects due to chemotherapy could not be excluded. Because, the patient was given



**Figure 1. (a)** Necrosis and steatosis in the liver parenchyma (HEX20). **(b)** Fibrosis and ductular proliferation in the portal area, steatosis in the liver parenchyma (PASX20).

peg-asparaginase (2500 U/m<sup>2</sup>/day, single dose), high dose cytosine arabinoside (2 g/m<sup>2</sup>/day, single dose), high dose methotrexate (5g/m<sup>2</sup>/day, single dose) and cyclophosphamide (200 mg/m<sup>2</sup>, 5 doses) 2 weeks before the development of ALF. Hepatotoxicity secondary to chemotherapy usually occur within 1-4 weeks.<sup>[5]</sup> Direct hepatotoxicity of chemotherapy agents have been reported, as rituximab and vincristine are associated with hepatocellular injury, cyclophosphamide and doxorubicin with venoocclusive disease (VOD), L-asparaginase, pegylated asparaginase, high-dose cytosine arabinoside, mitoxantrone and methotrexate with acute liver failure.<sup>[6]</sup>

VZV is common in immunosuppressed patients and may be mortal. In the literature, few patients with VZV-induced ALF have been reported to survive without liver transplantation.<sup>[3,4]</sup> The treatment of secondary acute liver failure involves early intravenous acyclovir, liver support systems, and liver transplantation.<sup>[3]</sup> Support systems save time for spontaneous recovery and serve as a bridge to transplantation in patients who need liver transplantation. Liver support systems include such as continuous renal replacement therapies, plasmapheresis and plasma replacement therapy, hemoperfusion, and liver replacement therapies.<sup>[7]</sup> Our patient benefited from single volume plasmapheresis with the intermittent centrifuge method for one month. In the literature, cases with ALF developed after chemotherapy have also been reported to have benefited from plasmapheresis.<sup>[8]</sup> Transplantation decision should be made considering the possibility of spontaneous hepatic healing in patients with ALF. As the degree of encephalopathy increases, the expected chance of spontaneous recovery decreases. It is difficult to predict which patient will recover without transplantation, and which will not. Many scoring systems have been developed to determine the time of liver transplantation in adults (King's College, Clichy, MELD, MELD-Na, BILE score). Currently, a scoring system for child patients hasn't been introduced and the indications for transplantation are not clear. In children, the diagnostic value of daily evaluation of important prognostic variables has been shown to be superior to King's College and MELD scoring systems.<sup>[9]</sup> The prognostic variables include the time between the onset of jaundice and encephalopathy, the degree of encephalopathy, bilirubin, PT/INR ratios, ALT and ammonia levels, and white blood cell count.<sup>[7]</sup> Our case was evaluated according to King's College Criteria, which is an adult scoring system, and indication for liver transplantation was established by considering that the jaundice period was 7 days before encephalopathy developed, the INR value was 3.5 and the serum bilirubin was above 17.5 mg/dl. In addition, our patient's MELD-Na score was 32 and indicating a poor prognosis. However, since our patient had

disseminated VZV infection, the risk of complications after transplantation would be very high and liver transplantation could not be performed. Therefore supportive treatments have been applied and the patient was improved with these treatments. Although liver transplantation offers a treatment option for patients who cannot heal with medical treatment, it has a high mortality and morbidity. In addition, there are significant risks, including surgical complications and prolonged immunosuppression.<sup>[10]</sup> Comprehensive studies determining prognostic markers in children with ALF are needed to determine which patients will improve only with supportive treatments, and which will not survive without transplantation.

### Disclosures

**Informed consent:** Written informed consent was obtained from the patient for the publication of the case report and the accompanying images.

**Peer-review:** Externally peer-reviewed.

**Conflict of Interest:** None declared.

**Authorship Contributions:** Concept – F.I.V., A.A.; Design – F.I.V., A.A., K.K.; Supervision – F.I.V., A.A., K.K., N.K.; Materials – F.I.V., N.K.; Data collection &/or processing – F.I.V., A.A., K.K.; Analysis and/or interpretation – F.I.V., A.A., K.K., N.K.; Literature search – F.I.V., A.A., K.K., N.K.; Writing – F.I.V., A.A.; Critical review – F.I.V., A.A., K.K., N.K.

### References

1. Squires RH Jr, Shneider BL, Bucuvalas J, Alonso E, Sokol RJ, Narkewicz MR, et al. Acute liver failure in children: the first 348 patients in the pediatric acute liver failure study group. *J Pediatr* 2006;148:652-8.
2. Mantadakis E, Anagnostatou N, Danilidou V, Markaki EA, Spanaki AM, Briassoulis G, et al. Fulminant hepatitis due to varicella zoster virus in a girl with acute lymphoblastic leukemia in remission: report of a case and review. *J Pediatr Hematol Oncol* 2005;10:551-3.
3. Toffaha A, El Ansari W, Ramzee AF, Afana M, Aljohary H. Rare presentation of primary varicella zoster as fatal fulminant hepatitis in adult on low-dose, short-term steroid: Case report. *Ann Med Surg* 2019;48:115-7.
4. Brewer EC, Hunter L. Acute Liver Failure due to Disseminated Varicella Zoster Infection. *Case Reports Hepatol* 2018;2018:1269340.
5. Joshi M, Sodhi K. S, Pandey R, Singh J, Goyal S, Prasad, S, et al. Cancer Chemotherapy and hepatotoxicity: an update. *J Pharm Research* 2014;4(06).
6. Vincenzi B, Russo A, Terenzio A, Galvano A, Santini D, Vorini F, et al. The use of SAME in chemotherapy-induced liver injury. *Crit Rev Oncol Hematol* 2018;130:70-7.
7. Lutfi R, Abulebda K, Nitu ME, Molleston JP, Bozic MA, Subbarao G. Intensive Care Management of Pediatric Acute Liver Failure. *J Pediatr Gastroenterol Nutr* 2017;64:660-70.

8. Göpel W, Schnetzke U, Hochhaus A, Scholl S. Functional acute liver failure after treatment with pegylated asparaginase in a patient with acute lymphoblastic leukemia: potential impact of plasmapheresis. *Ann Hematol* 2016;95:1899-01.
9. Kumar R, Shalimar, Sharma H, Goyal R, Kumar A, Khanal S, Prakash S, et al. Prospective derivation and validation of early dynamic model for predicting outcome in patients with acute liver failure. *Gut* 2012;61-7:1068-75.
10. Zhang LN, Guo W, Zhu JH, Guo Y. Successful rescue of acute liver failure and hemophagocytic lymphohistiocytosis following varicella infection: A case report and review of literature. *World J Clin Cases* 2018;6:659-65.