



## Letter to the Editor

# Anatomical Variations and Reconstruction Techniques of the Left Hepatic Vein in Pediatric Living Donor Liver Transplantation

Sertac Usta, Sezai Yilmaz, Sami Akbulut

Department of Surgery and Liver Transplant Institute, Inonu University Faculty of Medicine, Malatya, Türkiye

Please cite this article as "Usta S, Yilmaz S, Akbulut S. Anatomical Variations and Reconstruction Techniques of the Left Hepatic Vein in Pediatric Living Donor Liver Transplantation. J Inonu Liver Transpl Inst 2023;1(2):77-78".

Dear Editor,

We read with interest the article by Shankar et al.<sup>[1]</sup> that was recently published in American Journal of Transplantation. This study was conducted on prospectively collected database of 296 left lateral segment (LLS) pediatric living donor liver transplantation. Aim of it was to identify different venous drainage patterns of segment 2 (V2) and segment 3 (V3) and to describe their proper reconstruction. We would like to make a few contributions by emphasizing that we appreciate great importance to this study.

The left hepatic vein (LHV) anatomy defined by the authors, which we encounter in a previous study of Mohamed Rela,<sup>[2]</sup> can be more comprehensive classification with addition of two different types, although the frequency is low. V2 and V3 may drain conjoin or separately into the middle hepatic vein (Fig. 1a, b).

In "modified triangular technique" frequently used in anastomosis to the vena cava inferior (VCI) of the recipient of the LHV, we do not recommend making a longitudinal slit in the anterior aspect of the inferior vena cava, as suggested in the article by Fukuda et al.<sup>[3]</sup> Because this incision will cause an excessive width on the inferior vena cava side of the anastomosis, adapting sutures will be used excessively

to adapt the anastomosis, and inferior vena cava stenosis will occur as a result.

Regarding reconstruction techniques in grafts with multiple orifices:

- Unification venoplasty should be performed in type 1b and type 2. However, while doing this procedure, V2 and V3 orifices should be held together like an equilateral triangles (Fig. 2a). The closest edge of triangles should be joined with interrupted 7/0 absorbable monofilament sutures (Fig. 2b). The objective here is to apply a joining suture without narrowing or stretching both lumens. If the unifying includes half of the orifices of V2 and V3, that is half of the circles, it can be seen that both of the lumens narrow. Then an autologous saphenous vein that cut longitudinally or cryopreserved iliac vein graft is sutured around the joined vessel like a circumferential fence or venous conduit (Fig. 2c). This may also be called a funnel shaped extension.<sup>[4]</sup>
- In this article,<sup>[1]</sup> we see that a partial circumferential fence is made the named as "extension venoplasty" in Figure 4c. Such reconstructions will complicate anastomosis. A circumferential fence with saphenous vein or a venous conduit should always be made as 360 degree.

**Address for correspondence:** Sami Akbulut, MD. Department of Surgery and Liver Transplant Institute, Inonu University Faculty of Medicine, Malatya, Türkiye

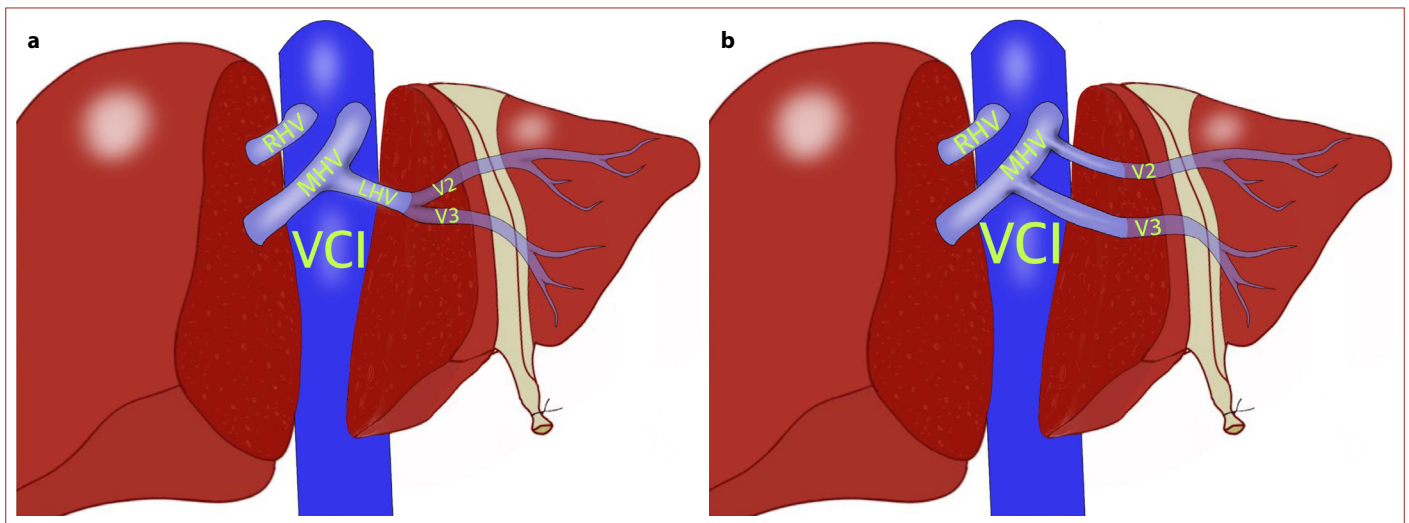
**Phone:** +90 532 325 12 12 **E-mail:** akbulutsami@gmail.com

**Submitted Date:** 29.05.2023 **Revised Date:** 29.05.2023 **Accepted Date:** 31.05.2023 **Available Online Date:** 25.09.2023

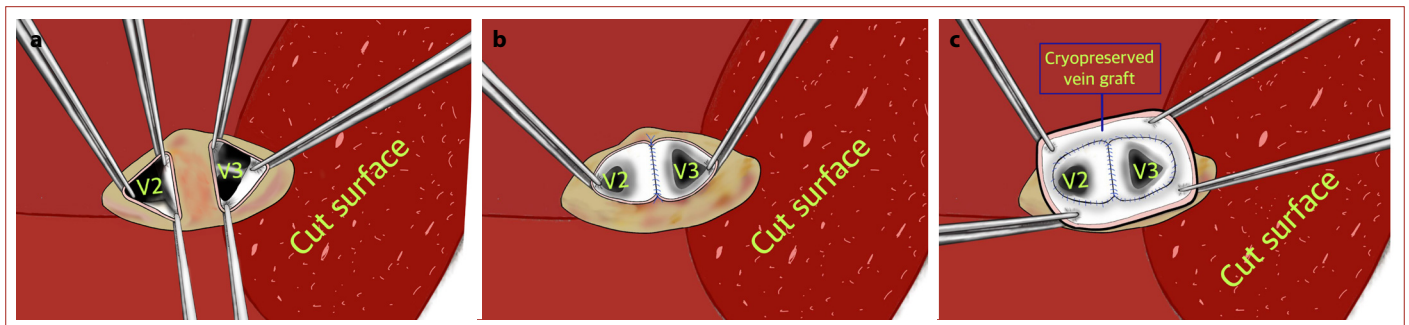
©Copyright 2023 by Journal of Inonu Liver Transplantation Institute - Available online at [www.jilti.org](http://www.jilti.org)

**OPEN ACCESS** This is an open access article under the CC BY-NC license (<http://creativecommons.org/licenses/by-nc/4.0/>).





**Figure 1.** V2 and V3 may drain conjoin into the middle hepatic vein (a); V2 and V3 may drain separately into the middle hepatic vein (b).



**Figure 2.** V2 and V3 orifices are held together like an equilateral triangles (a); the closest edge of triangles are joined with interrupted sutures (b); a cryopreserved ilia vein graft is sutured around the joined vessel like a venous conduit (c).

- We would like to state that we cannot make sense of the fact that the diameter of V3 below or above 7 mm in type 3 determines the type of reconstruction. In any case, the V3 orifice should be extended to V2 with a cryopreserved vein and unification should be done as described above. In the pediatric patients, especially under 10 kg, lengthening and anastomosis of the V3 into the inferior vena cava with an already very narrow diameter will invite inferior vena cava complications. Also, since the extension of V3 into the inferior vena cava will partially change the flow direction, thrombosis will be inevitable in a low-flow venous system.

#### Disclosures

**Peer-review:** Externally peer-reviewed.

**Conflict of Interest:** The authors declare that they have no conflict of interest.

**Authorship Contributions:** Concept – S.A., S.Y., S.U.; Design – S.A., S.Y.; Supervision – S.Y.; Materials – S.Y., S.U.; Data collection &/or processing – S.Y., S.U.; Analysis and/or interpretation – S.A., S.Y.; Literature search – S.A., S.Y.; Writing – S.A., S.Y.; Critical review – S.Y.

#### References

- Shankar S, Rammohan A, Gunasekaran V, Narasimhan G, Rajalingam R, Palaniappan K, Kanagavelu R, Rajkumar A, Kaliamoorthy I, Rela M. Anatomical variations of left hepatic vein and outflow reconstruction techniques in pediatric living donor liver transplantation. *Am J Transplant* 2023;S1600-6135(23)00346-5.
- Dar FS, Faraj W, Heaton ND, Rela M. Variation in the venous drainage of left lateral segment liver graft requiring reconstruction of segment III vein with donor iliac artery. *Liver Transpl* 2008;14(4):576-579.
- Fukuda A, Sakamoto S, Sasaki K, Narumoto S, Kitajima T, Hirata Y, Hishiki T, Kasahara M. Modified triangular hepatic vein reconstruction for preventing hepatic venous outflow obstruction in pediatric living donor liver transplantation using left lateral segment grafts. *Pediatr Transplant* 2018;22(3):e13167.
- Yilmaz S, Kayaalp C, Isik B, Ersan V, Otan E, Akbulut S, et al. Reconstruction of Anomalous Portal Venous Branching in Right Lobe Living Donor Liver Transplantation: Malatya Approach. *Liver Transpl* 2017;23(6):751-761.