

# Mild Aromatic L-Amino Acid Decarboxylase Deficiency Causing Hypoketotic Hypoglycemia in a 4-year-old Girl

✉ Merve Yoldaş Çelik<sup>1</sup>, ✉ Ebru Canda<sup>1</sup>, ✉ Havva Yazıcı<sup>1</sup>, ✉ Fehime Erdem<sup>1</sup>, ✉ Ayşe Yüksel Yanbolu<sup>1</sup>, ✉ Ayça Aykut<sup>2</sup>,  
✉ Asude Durmaz<sup>2</sup>, ✉ Ahmet Anık<sup>3</sup>, ✉ Sema Kalkan Uçar<sup>1</sup>, ✉ Mahmut Çoker<sup>1</sup>

<sup>1</sup>Ege University Faculty of Medicine, Department of Pediatrics, Clinic of Pediatric Metabolism and Nutrition, İzmir, Turkey

<sup>2</sup>Ege University Faculty of Medicine, Department of Medical Genetics, İzmir, Turkey

<sup>3</sup>Aydın Adnan Menderes University Faculty of Medicine, Department of Pediatrics, Clinic of Pediatric Endocrinology, Aydın, Turkey

## What is already known on this topic?

Aromatic L-amino acid decarboxylase (AADC) deficiency is an inherited metabolic disease that leads to a deficiency of serotonin, dopamine, epinephrine, and norepinephrine. Neurological findings are dominant due to deficiencies in neurotransmitter synthesis, but hypoglycemia can occur because of autonomic dysfunction.

## What this study adds?

The first finding in this case with mild AADC deficiency was hypoglycemia. In patients presenting with hypoglycemia, AADC deficiency should be considered in the differential diagnosis, even if there are no neurological findings.

## Abstract

Aromatic L-amino acid decarboxylase (AADC) deficiency is a disease in which neurological findings are dominant due to deficiencies in neurotransmitter synthesis. Hypoglycemia caused by autonomic dysfunction is one of the symptoms that may be encountered. Here we report a case of mild AADC deficiency presenting with hypoglycemia without any neurological signs. A 4-year-old girl presented with recurrent hypoglycemia. Her growth and development were normal. Plasma insulin and cortisol values were normal in the sample at the time of hypoglycemia. C8:1-Carnitine elevation was detected in the acylcarnitine profile. A clinical exome panel was performed with the suggestion of a fatty acid oxidation defect. However, a homozygous variant in the *DDC* gene was detected. Furthermore, cerebrospinal fluid neurotransmitter analysis revealed low 5-hydroxyindolacetic acid and homovanillic acid and high 3-O-methyl-dopa and methyltetrahydrofolate (5 MTHF) consistent with AADC deficiency. Plasma AADC enzyme activity was low. The episodes of hypoglycemia were treated with uncooked cornstarch. This case suggests that AADC deficiency should be considered in some patients with hypoglycemia.

**Keywords:** Aromatic L-amino acid decarboxylase deficiency, AADC deficiency, hypoglycemia, neurotransmitter deficiency

## Introduction

Hypoglycemia is a common biochemical findings in endocrine and inherited metabolic disorders. Well-known, specific metabolic disorders causing hypoglycemia include glycogen storage diseases, gluconeogenesis disorders, fatty

acid oxidation defects, and ketolysis defects (1). Identifying and treating the cause of hypoglycemia is of great importance. Therefore, the extremely rare metabolic causes of hypoglycemia, such as neurotransmitter disorders and in particular aromatic L-amino acid decarboxylase (AADC) deficiency, should be kept in mind (2). AADC is an essential

**Cite this article as:** Yoldaş Çelik M, Canda E, Yazıcı H, Erdem F, Yüksel Yanbolu A, Aykut A, Durmaz A, Anık A, Kalkan Uçar S, Çoker M. Mild Aromatic L-Amino Acid Decarboxylase Deficiency Causing Hypoketotic Hypoglycemia in a 4-year-old Girl. J Clin Res Pediatr Endocrinol. 2024;16(3):361-366



**Address for Correspondence:** Merve Yoldaş Çelik MD, Ege University Faculty of Medicine, Department of Pediatrics, Clinic of Pediatric Metabolism and Nutrition, İzmir, Turkey  
**Phone:** +90 505 590 48 56 **E-mail:** drmerveyoldas@yahoo.com **ORCID:** orcid.org/0000-0003-0015-9807

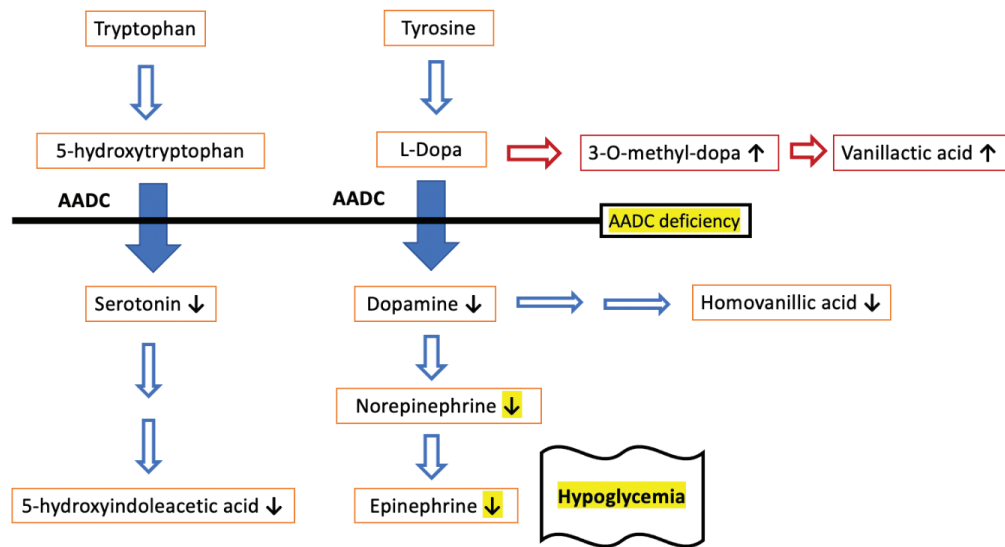
**Conflict of interest:** None declared

**Received:** 12.10.2022

**Accepted:** 13.12.2022



©Copyright 2024 by Turkish Society for Pediatric Endocrinology and Diabetes / The Journal of Clinical Research in Pediatric Endocrinology published by Galenos Publishing House. Licensed under a Creative Commons Attribution-NonCommercial-NoDerivatives 4.0 (CC BY-NC-ND) International License.



**Figure 1.** Norepinephrine (NE) and epinephrine (E) maintain glycemia levels by stimulating glucagon release, glycogenolysis, and food consumption and inhibiting insulin release. Studies by Ste Marie and Palmiter (14) found that the absence of catecholamines in dopamine β-hydroxylase-null mice resulted in chronically low blood glucose levels, impaired glucagon response to hypoglycemia, and elevated insulin levels, suggesting that NE and E are necessary for glucose homeostasis. Isolated deficiency in counter-regulatory hormones, such as growth hormone or cortisol is sufficient to expose the patient to hypoglycemia. Consequently, hypoglycemia in AADC deficiency is probably only the consequence of the altered synthesis of dopamine-derived catecholamines

AADC: aromatic L-amino acid decarboxylase

enzyme for synthesizing the monoamine neurotransmitters, serotonin and dopamine. Dopamine is the precursor of epinephrine (E) and norepinephrine (NE) (Figure 1). AADC deficiency is an autosomal recessive inherited metabolic disease that causes a deficiency of serotonin, dopamine, E, and NE. AADC deficiency usually manifests with neurologic symptoms, such as developmental delay, dystonia, oculogyric crisis, hypotonia, and autonomic findings in the early stages of life. The phenotypic spectrum of the disease is broad. Based on the clinical description, AADC may be classified as mild, moderate, or severe according to the severity of neurological symptoms. The mild phenotype may present with autonomic symptoms without significant movement disorders (3).

AADC deficiency leads to reduced dopamine, NE, and E levels. Catecholamines have essential counter-regulating functions for hypoglycemia, such as stimulation of gluconeogenesis and lipolysis (Figure 1). Hypoglycemia may not be expected as the primary finding in AADC deficiency, where the indicative findings are usually neurological symptoms. In addition to neurological findings, hypoglycemia in intercurrent diseases has been reported in a small number of cases (4,5,6,7,8,9,10,11,12,13). Hypoglycemia is thought to develop from the deficiency of catecholamines, which are contra-insulin hormones. This report describes a case of AADC deficiency diagnosed with hypoglycemia without neurological findings.

## Case Report

A 4-year-old girl presented with four episodes of hypoglycemia. The patient was born at 38 weeks, by C-section at 2700 grams. Prenatal history was unremarkable. Due to meconium staining, she was hospitalized for two days in the neonatal intensive care unit. She experienced jaundice in the neonatal period but did not need phototherapy. She received breast milk for 18 months. Her developmental stages were as expected and in line with her age; she sat unsupported at seven months, speech at 12 months, and walked unsupported at 18 months. There was a history of third-degree cousin marriage between the parents.

On physical examination, body weight was -1.4 standard deviation score (SDS), height was -1.79 SDS, and head circumference was -0.43 SDS. There was no dysmorphism, no organomegaly, and a detailed neurological examination was normal. She had normal muscle bulk, tone, and power. Deep tendon reflexes were normal. She had no movement disorder findings, such as hypokinesia, dystonia, or oculogyric crises. The patient had a history of hypoglycemia accompanied by a seizure after diarrhea, with the first episode at the age of 3.5 years. She had four episodes of hypoglycemia in total prior to presentation. Hypoglycemia was usually observed after about 10 hours of fasting and diarrhea. The fasting test for the etiology of hypoglycemia was performed with metabolic and endocrinological

sampling at 35 mg/dL glucose level at the 12<sup>th</sup> hour of fasting. Insulin, adrenocorticotrophic hormone, and cortisol levels were normal. Urine ketones were negative, and the lactate level was in a normal range. The patient was unresponsive to glucagon administration. After intravenous glucose infusion at the time of hypoglycemia, blood glucose was recorded as 230 mg/dL. In the sample taken at the time of hypoglycemia, there was elevated C8:1 carnitine of 1.0 µmol/L (normal <0.47) in the acylcarnitine profile; tiglylglycine excretion in urine organic acid screen and plasma amino acid profiles were average. Complete blood count with differential, liver, and kidney function tests, lipid profile, ammonia, and lactate levels were as expected in the laboratory analysis. Eye examination and hearing test were unremarkable. Abdominal ultrasonography and echocardiography were normal. Cranial magnetic resonance imaging and electromyography were normal.

Hypoketotic hypoglycemia, high levels of C8:1, and low insulin levels were compatible with fatty acid oxidation defects. However, the clinical exome sequencing panel revealed a homozygous p.Asp15Gly variant in the *DDC* gene. This variant was classified as a variant of uncertain significance [VUS (PM2-PP3)], according to the American College of Medical Genetics criteria. Upon this result, a lumbar puncture was performed, and low cerebrospinal fluid (CSF) levels of 5-hydroxyindole-3-acetic acid (5-HIAA) and homovanillic acid (HVA) and high levels of 3-O-methyl-dopa and 5-methyltetrahydrofolate (5-MTHF) were identified, consistent with AADC deficiency. Systemic AADC activity was low. The laboratory values of the patient are presented

in Table 1. The patient was diagnosed with AADC deficiency, confirmed by enzymatic and genetic analysis. Treatment was begun with 100 mg/day of pyridoxine. The episodes of hypoglycemia were treated with raw cornstarch (1 g/kg).

## Discussion

This report demonstrates the initial finding of hypoglycemia with no neurological signs in a young girl diagnosed with mild AADC deficiency. AADC deficiency is an extremely rare, inherited metabolic disease characterized by reduced activity of AADC, the key enzyme for neurotransmitter (dopamine and serotonin) synthesis. Only around 150 patients have been reported. Children with this condition are usually diagnosed in their first year of life. The cardinal sign of AADC deficiency is neurological symptoms, mainly hypotonia and oculogyric crises. In addition, autonomic nervous system dysfunction may cause extra neurological findings, such as gastrointestinal problems (diarrhea, constipation), feeding difficulties, nasal congestion, unstable body temperature, low blood pressure, and hypoglycemia (3).

Although hypoglycemia is not a cardinal finding of this disease, it was reported in five of the 82 patients in the Pediatric Neurotransmitter Diseases at BioPKU.org database. Hypoglycemia has been associated with E deficiency in AADC deficiency (10,14). Review of the literature showed that episodes of hypoglycemia are not always present in patients with AADC deficiency and have been documented only in patients with a severe phenotype (7,13). We have

**Table 1. Laboratory characteristics of the patient**

	Patient	Normal range
<b>Blood (plasma/serum)</b>		
Glucose, mg/dL	35	> 55
Insulin (during hypoglycemia), µU/mL	0.4	< 1
C-peptide (during hypoglycemia), ng/mL	0.07	< 0.30
Cortisol (during hypoglycemia), µg/dL	30.9	> 20
Growth hormone (during hypoglycemia), ng/mL	15.2	
Prolactin, µg/L	25	4.70-23.3
Plasma activity of AADC, pmol/min/mL	4	33-79
<b>CSF</b>		
CSF homovanillic acid, nmol/L	144.9	233-928
CSF 5-hydroxyindolacetic acid, nmol/L	39	74-345
CSF 3-O-methyl-dopa, nmol/L	415.2	< 150
CSF 5-hydroxytryptophan, nmol/L	34.2	< 10
<b>Urine organic acid analysis</b>		
Tiglylglycine mmol/mol creatinine	4	ND
Vanil lactic acid	ND	ND

AADC: aromatic L-amino acid decarboxylase, CSF: cerebrospinal fluid, ND: not detectable

**Table 2. AADC deficiency patients with hypoglycemia in the published literature**

Reference	Patient 1	Patient 2	Patient 3	Patient 4	Patient 5	Patient 6	Patient 7	Patient 8	Patient 9	Patient 10	Patient 11	Patient 12	Patient 13
Present study	Female	Female	Male	Male	Male	Male	Female	Female	Male	Female	Female	Male	Female
Age at onset	42 months	3 years	2 months	3 months	3 months	2 days	3 months	3 months	7 years	10 months	3 months	4 months	5 years
Disease phenotype	Mild	Mild	Severe	Severe	Severe	Severe	Severe	Severe	Severe	Severe	Severe	Severe	Severe
Hypoglycemia	+	+	+	+	+	+	+	+	+	+	+	+	+
Diarrhea	+	+	-	-	-	-	-	+	-	-	-	-	-
Temperature instability	-	-	-	-	+	+	N/A	N/A	-	-	-	-	+
Hyperhidrosis	-	-	+	+	+	+	+	+	+	-	+	+	-
Nasal congestion	-	+	+	+	-	-	-	+	+	-	+	-	-
Feeding problems	-	-	+	+	-	+	+	N/A	+	+	+	+	+
Failure to thrive	-	-	+	+	-	+	+	N/A	N/A	N/A	+	N/A	N/A
Movement disorders	-	+	+	+	+	+	+	+	+	+	+	+	+
Oculogyric crisis	-	-	+	+	+	+	+	+	+	+	+	+	+
Irritability	-	-	+	+	-	+	+	+	+	-	+	+	+
Developmental delay	-	-	+	+	-	+	+	+	+	+	+	+	+
Epileptic seizures	+	+	-	-	-	-	-	-	+	-	-	-	-
Sleep problems	-	-	+	+	-	-	-	+	N/A	N/A	-	+	-
Hyperprolactinemia	+	+	N/A	+	+	N/A	N/A	N/A	N/A	N/A	N/A	N/A	N/A
Urine organic acids	Tiglylglycine	N/A	N/A	Normal	Normal	Vanillic acid	Vanillic acid	Vanillic acid	N/A	N/A	N/A	N/A	N/A
AADC activity, pmol/min/mL (N 33-79)	4	5	<1	N/A	N/A	<1	2.6	5	2.6	1.5	3.9	0.2	1.6
D/C gene mutation Allele 1	c.44A > G	c.97G > T	c.1222C > A	c.714+4A > T	c.714+4A > T	N/A	c.823G > A	c.665T > C	N/A	N/A	c.714+4A > T	N/A	c.206C > T
D/C gene mutation Allele 2	c.44A > G	c.1385G > C	C102T (premature stop codon)	c.106G > A	c.714+4A > T	N/A	c.823G > A	c.665T > C	N/A	N/A	c.1234C > T	N/A	c.439A > C

N/A: not applicable, AADC: aromatic L-amino acid decarboxylase

summarized clinical and laboratory data of all these AADC deficiency patients with hypoglycemia in Table 2. Remarkably, our patient had hypoglycemic episodes with diarrhea as the primary symptom, and no neurological signs were observed except for a seizure triggered by hypoglycemia. Arnoux et al. (5) reported a similar patient with mild AADC deficiency, a 5-year-old girl with episodes of hypoglycemia and diarrhea who only had hypomimia and dyspraxia as neurological findings. Thus, to the best of our knowledge, only two patients have been reported who presented with hypoglycemia and were diagnosed with mild AADC deficiency, based on the differential diagnosis of hypoglycemia. Routine first-line metabolic investigations for hypoglycemia may not indicate AADC deficiency. Lactate, ammonia, acylcarnitine profile, and plasma amino acid analysis are normal in these patients. However, patients with AADC deficiency may be identified by elevated vanil lactic acid in urine organic acid analysis due to degradation of 3-O-methyl-1-dopa (3-OMD) to vanil lactic acid (7). In our patient, tiglylglycine excretion was found in the urine organic acid analysis due to fasting, and there was no vanil lactic acid excretion. A low ketone level at the time of hypoglycemia may suggest a diagnosis of hyperinsulinism or fatty acid oxidation deficiency. However, NE and E levels decrease in AADC deficiency, leading to an impaired glucagon response to hypoglycemia, which explains the low ketone levels. In particular, the main laboratory test to identify the diagnosis of AADC deficiency is the measurement of neurotransmitter levels. While the pterin level is standard in the CSF analysis, there are high 3-O-methyl-1-dopa and 5-hydroxytryptophan and decreased HVA and 5-HIAA values. 3-OMD is a disease-specific metabolite, and showing its elevation in plasma or dry blood may lead to early detection of patients in newborn screening programs in the future (15). Demonstrating AADC enzyme deficiency in plasma supported the molecular diagnosis.

## Conclusion

The present case report highlights that AADC deficiency should be considered in the differential diagnosis of some patients presenting with hypoglycemia, even in the absence of classical neurological findings of the disease.

## Ethics

**Informed Consent:** Consent form was filled out by all participants.

## Authorship Contributions

Surgical and Medical Practices: Merve Yoldaş Çelik, Ebru Canda, Havva Yazıcı, Fehime Erdem, Sema Kalkan Uçar,

Mahmut Çoker, Concept: Merve Yoldaş Çelik, Sema Kalkan Uçar, Design: Merve Yoldaş Çelik, Sema Kalkan Uçar, Data Collection or Processing: Merve Yoldaş Çelik, Ebru Canda, Havva Yazıcı, Fehime Erdem, Ayşe Yüksel Yanbolu, Ayça Aykut, Asude Durmaz, Ahmet Anık, Sema Kalkan Uçar, Mahmut Çoker, Analysis or Interpretation: Merve Yoldaş Çelik, Sema Kalkan Uçar, Literature Search: Merve Yoldaş Çelik, Ebru Canda, Sema Kalkan Uçar, Mahmut Çoker, Writing: Merve Yoldaş Çelik, Sema Kalkan Uçar.

**Financial Disclosure:** Plasma AADC activity was funded by PTC Therapeutics.

## References

1. Casertano A, Rossi A, Fecarotta S, Rosanio FM, Moracas C, Di Candia F, Parenti G, Franzese A, Mozzillo E. An Overview of Hypoglycemia in Children Including a Comprehensive Practical Diagnostic Flowchart for Clinical Use. *Front Endocrinol (Lausanne)*. 2021;12:684011.
2. Buesch K, Zhang R, Szczepańska K, Veličković V, Turner L, Despotović M, Đorđević B, Russell A. Burden and severity of disease of aromatic L-amino acid decarboxylase deficiency: a systematic literature review. *Curr Med Res Opin*. 2022;38:1871-1882. Epub 2022 May 18
3. Wassenberg T, Molero-Luis M, Jeltsch K, Hoffmann GF, Assmann B, Blau N, Garcia-Cazorla A, Artuch R, Pons R, Pearson TS, Leuzzi V, Mastrangelo M, Pearl PL, Lee WT, Kurian MA, Heales S, Flint L, Verbeek M, Willemsen M, Opladen T. Consensus guideline for the diagnosis and treatment of aromatic L-amino acid decarboxylase (AADC) deficiency. *Orphanet J Rare Dis*. 2017;12:12.
4. Pons R, Ford B, Chiriboga CA, Clayton PT, Hinton V, Hyland K, Sharma R, De Vivo DC. Aromatic L-amino acid decarboxylase deficiency: clinical features, treatment, and prognosis. *Neurology*. 2004;62:1058-1065.
5. Arnoux JB, Damaj L, Napuri S, Serre V, Hubert L, Cadoudal M, Simard G, Ceballos I, Christa L, de Lonlay P. Aromatic L-amino acid decarboxylase deficiency is a cause of long-fasting hypoglycemia. *J Clin Endocrinol Metab*. 2013;98:4279-4284. Epub 2013 Sep 13
6. Helman G, Pappa MB, Pearl PL. Widening Phenotypic Spectrum of AADC Deficiency, a Disorder of Dopamine and Serotonin Synthesis. *JIMD Rep*. 2014;17:23-27. Epub 2014 Jul 8 Erratum in: *JIMD Rep*. 2014;17:97
7. Abdenur JE, Abeling N, Specola N, Jorge L, Schenone AB, van Cruichten AC, Chamoles NA. Aromatic L-aminoacid decarboxylase deficiency: unusual neonatal presentation and additional findings in organic acid analysis. *Mol Genet Metab*. 2006;87:48-53. Epub 2005 Nov 9
8. Spitz MA, Nguyen MA, Roche S, Heron B, Milh M, de Lonlay P, Lion-François L, Testard H, Napuri S, Barth M, Fournier-Favre S, Christa L, Vianey-Saban C, Corne C, Roubertie A. Chronic Diarrhea in L-Amino Acid Decarboxylase (AADC) Deficiency: A Prominent Clinical Finding Among a Series of Ten French Patients. *JIMD Rep*. 2017;31:85-93. Epub 2016 May 5
9. Dai W, Lu D, Gu X, Yu Y; Mainland Chinese League of AADC Rare Disease. Aromatic L-amino acid decarboxylase deficiency in 17 Mainland China patients: Clinical phenotype, molecular spectrum, and therapy overview. *Mol Genet Genomic Med*. 2020;8:e1143. Epub 2020 Jan 23
10. Fusco C, Leuzzi V, Striano P, Battini R, Burlina A; Delphi panel experts' group; Spagnoli C. Aromatic L-amino Acid Decarboxylase (AADC)

- deficiency: results from an Italian modified Delphi consensus. *Ital J Pediatr.* 2021;47:13.
11. Korenke GC, Christen HJ, Hyland K, Hunneman DH, Hanefeld F. Aromatic L-amino acid decarboxylase deficiency: an extrapyramidal movement disorder with oculogyric crises. *Eur J Paediatr Neurol.* 1997;1:67-71.
  12. Lee HF, Tsai CR, Chi CS, Chang TM, Lee HJ. Aromatic L-amino acid decarboxylase deficiency in Taiwan. *Eur J Paediatr Neurol.* 2009;13:135-140. Epub 2008 Jun 24
  13. Manegold C, Hoffmann GF, Degen I, Ikonomidou H, Knust A, Laass MW, Pritsch M, Wilichowski E, Hörster F. Aromatic L-amino acid decarboxylase deficiency: clinical features, drug therapy and follow-up. *J Inherit Metab Dis.* 2009;32:371-380. Epub 2009 Jan 28
  14. Ste Marie L, Palmiter RD. Norepinephrine and epinephrine-deficient mice are hyperinsulinemic and have lower blood glucose. *Endocrinology.* 2003;144:4427-4432. Epub 2003 Jun 26
  15. Hyland K, Reott M. Prevalence of Aromatic L-Amino Acid Decarboxylase Deficiency in At-Risk Populations. *Pediatr Neurol.* 2020;106:38-42. Epub 2019 Dec 26