

Clinical Management in Systemic Type Pseudohypoaldosteronism Due to *SCNN1B* Variant and Literature Review

© Gülin Karacan Küçükali¹, © Semra Çetinkaya¹, © Gaffari Tunç², © M. Melek Oğuz³, © Nurullah Çelik⁴, © Kardelen Yağmur Akkaş³, © Saliha Şenel³, © Naz Güleray Lafcı⁵, © Şenay Savaş Erdeve¹

¹University of Health Sciences Turkey, Dr. Sami Ulus Maternity, Child Health and Diseases Training and Research Hospital, Clinic of Pediatric Endocrinology, Ankara, Turkey

²Sivas Cumhuriyet University Faculty of Medicine, Department of Child Health and Diseases, Division of Neonatology, Sivas, Turkey

³University of Health Sciences Turkey, Dr. Sami Ulus Maternity, Child Health and Diseases Training and Research Hospital, Clinic of Pediatric, Ankara, Turkey

⁴Sivas Cumhuriyet University Faculty of Medicine, Department of Child Health and Diseases, Division of Pediatric Endocrinology, Sivas, Turkey

⁵University of Health Sciences Turkey, Dr. Sami Ulus Maternity, Child Health and Diseases Training and Research Hospital, Clinic of Medical Genetics, Ankara, Turkey

What is already known on this topic?

Pseudohypoaldosteronism is a life threatening disease due to serious salt loss. Differential diagnosis from other adrenal insufficiencies is important because the treatments are different. Patient compliance is difficult due to the need for excessive amounts of oral treatments.

What this study adds?

We present a patient with a difficult diagnostic process due to hypertension. A novel variant resulting in a premature stop codon was detected in the patient. Clinical and laboratory features of all published cases with *SCNN1B* variant are reviewed.

Abstract

Systemic pseudohypoaldosteronism (PHA) is a rare, salt-wasting syndrome that is caused by inactivating variants in genes encoding epithelial sodium channel subunits. Hyponatremia, hyperkalemia, metabolic acidosis, increased aldosterone and renin levels are expected findings in PHA. Clinical management is challenging due to high dose oral replacement therapy. Furthermore, patients with systemic PHA require life-long therapy. Here we report a patient with systemic PHA due to *SCNN1B* variant whose hyponatremia and hyperkalemia was detected at the 24th hour of life. Hyperkalemia did not improve with conventional treatments and dialysis was required. He also developed myocarditis and hypertension in follow-up. Challenges for diagnosis and treatment in this patient are discussed herein. In addition, published evidence concerning common features of patients with *SCNN1B* variant are reviewed.

Keywords: Systemic pseudohypoaldosteronism, hyponatremia, hyperkalemia, metabolic acidosis, epithelial sodium channel, *SCNN1B*

Introduction

Aldosterone is a mineralocorticoid hormone that provides sodium absorption and potassium secretion. Sodium crosses the apical membrane in the principal cells in kidney and enters the epithelial cell through the ion selective epithelial sodium channel (ENaC). Potassium is also secreted into the tight epithelium in the kidney. The ENaC is located in the

apical membranes of sensitive tissues, such as the distal nephron, distal colon, salivary and sweat glands and creates a rate-limiting step in sodium reabsorption (1,2). ENaC is a heteromultimeric protein consisting of three subunits, α , β , γ (3). ENaC subunits are encoded by the *SCNN1A* gene on chromosome 12p13, and the *SCNN1B* and *SCNN1G* genes on chromosome 16p12.2-p12.1.



Address for Correspondence: Gülin Karacan Küçükali MD, University of Health Sciences Turkey, Dr. Sami Ulus Maternity, Child Health and Diseases Training and Research Hospital, Clinic of Pediatric Endocrinology, Ankara, Turkey

Phone: +90 533 764 84 26 **E-mail:** gulinkucukali@gmail.com **ORCID:** orcid.org/0000-0001-7506-1711

Conflict of interest: None declared

Received: 23.05.2020

Accepted: 11.08.2020

©Copyright 2021 by Turkish Pediatric Endocrinology and Diabetes Society

The Journal of Clinical Research in Pediatric Endocrinology published by Galenos Publishing House.

Pseudohypoaldosteronism (PHA) is a salt wasting syndrome that develops due to variants in the mineralocorticoid receptor (MR) or ion channels in the kidney tubules. The estimated incidence of this rare disease is between 1/47,000 and 1/80,000, and its prevalence is < 1/1,000,000 (4,5,6). PHA1 is divided into renal (PHA1A) and systemic (PHA1B) forms depending on mutation in the *NR3C2* gene that codes the MR or in the *SCNN1A*, *SCNN1B* and *SCNN1G* genes that code ENaC subunits, respectively. In the systemic form, there is serious salt loss from the lung, colon, sweat and salivary glands, besides the kidney, and the symptoms begin in the neonatal period. Systemic PHA, which is inherited in an autosomal recessive fashion, results in life-threatening hyponatremia, hyperkalemia and metabolic acidosis. Plasma renin and aldosterone levels increase significantly, indicating end organ resistance. Treatment requires high doses of sodium replacement and potassium-lowering approaches. In this article, the clinical management of a patient with PHA due to an *SCNN1B* variant and the common features of patients with *SCNN1B* variants are presented.

Case Report

The male patient was born at term by normal vaginal delivery with a birth weight of 3600 grams and was followed up in the neonatal intensive care unit due to respiratory distress. It was learned that hyponatremia and hyperkalemia were detected (Na 118 mEq/L, K 8 mEq/L) at the 24th hour of hospitalization. He received 6x1 g salt, 4x2 g/kg calcium polystyrene sulfonate, 12x1 mL/kg 8.4% NaHCO₃ and 12x4 mL/kg 3% NaCl treatment during this period. He was subsequently referred to our clinic because of lack of response to treatments at the age of 1 month and 15 days. On physical examination, his weight was 4000 grams [-1.32 standard deviation score (SDS)], height was 55 cm (-0.34 SDS), and he did not have hyperpigmentation and any abnormality on genital examination. His daily weight gain was insufficient. His blood pressure was high at 110/80 mmHg (95th percentiles for systolic and diastolic blood pressure for this age group are 94/46 mmHg). There was third degree consanguinity between the parents. His brother had died at the age of seven days with hyponatremia and hyperkalemia. On admission, Na concentration was 123 mEq/L, K 7.1 mEq/L, blood pH 7.12, and HCO₃ was 10.8 mmol/L. Echocardiography was normal. He was diagnosed with congenital adrenal hyperplasia. Hydrocortisone and fludrocortisone treatments were started. Calcium gluconate, glucose-insulin infusion, NaHCO₃ infusion, and salbutamol inhalation were administered for hyponatremia and hyperkalemia. Despite these interventions, hyponatremia

persisted. Anti-hypertensive treatment was started for hypertension (0.1 mg/kg/day amlodipine). Oral 2x0.5 grams of salt was also added to the treatment and the dose was gradually increased. The laboratory findings at admission to our clinic were: 17-hydroxyprogesterone 1.22 ug/L, dehydroepiandrosterone sulfate 241.8 ug/dL, total testosterone 215.6 ng/dL, adrenocorticotrophic hormone 255 pg/mL, cortisol 43.8 ug/dL, renin 16.3 ng/mL/hour (NR=2.4-37), aldosterone 6.4 ug/L (NR=0.065-0.86), urine Na 134 mmol/L, urine K 2 mmol/L (when blood Na 123 mEq/L and blood K 7.1 mEq/L). The transtubular potassium gradient (TTKG) was 1.3, indicating very low renal potassium excretion. Based on the laboratory test results, hydrocortisone and fludrocortisone treatments were discontinued. Urinalysis, urine culture and renal ultrasonography were normal. During this process, hypertension continued. The diagnosis of systemic PHA was considered given that the patient was admitted with hyponatremia and hyperkalemia in the neonatal period, with high aldosterone level, increased urinary Na excretion, and decreased K excretion. When hyperkalemia did not respond to conventional treatments, including a trial of calcium polystyrene sulfonate at 1 g/kg/dose in four doses, peritoneal dialysis was required. After three days of peritoneal dialysis, K decreased to 4.18 mEq/L. Electrolyte values of the patient were kept in the normal range with 6x1 g of oral salt and 4x3 g of anti-potassium treatment. The patient had fever during the follow up and despite subsequent normalization of body temperature, tachycardia persisted. The patient was diagnosed with myocarditis due to an increase in acute phase reactants, troponin I level and electrocardiographic findings. Myocarditis findings regressed on the tenth day. However, the cause of hypertension could not be explained and was thought to be related to the salt treatment. Then his blood pressure returned to normal ranges and amlodipine and propranolol treatments were discontinued on the fourteenth day. The Sanger sequencing analysis of the *SCNN1A* gene, which is the most common gene to carry pathogenic variants in systemic PHA type 1B, was found to be normal. In subsequent Illumina MiSeq sequencing, a homozygous c. 978 C > A (p.Tyr326Ter) variant was detected in the sixth exon of the *SCNN1B* gene (NM_000336). After oral salt (6x1 g) and antipotassium (4x3 g) administration, the patient had normal electrolyte values and was discharged. One month after discharge, during a period of infection, the patient had to be hospitalized again due to the loss of oral intake and salt wasting crisis. At the last follow-up, the patient was seven months old, his weight was 7.3 kg (-1.3 SDS), height was 68 cm (-0.83 SDS) and blood pressure was 80/35 mmHg (50th percentile). His growth and development was

appropriate for the age with the current treatments (6x1 g oral salt, 4x3 g calcium polystyrene sulfonate and 4x2 mL NaHCO₃). Clinical follow-up continues.

Discussion

Systemic PHA type 1 is a rare life-threatening disease. Clinical manifestations are similar to other adrenal gland insufficiencies, such as congenital adrenal hyperplasia, hypoaldosteronism, and secondary PHA. The clinical presentation is characterized by insufficient weight gain, vomiting, and dehydration (4,6,7,8). Our patient had normal genitalia with hyponatremia and hyperkalemia. Hydrocortisone and fludrocortisone treatments were started until adrenal androgen results were obtained. Since adrenal hormone levels were normal in the follow-up, the patient was diagnosed with PHA1B. In the differential diagnosis of our patient, transient aldosterone resistance secondary to urinary tract infection was also considered (4), and this diagnosis was ruled out when urinalysis, urine culture and renal ultrasonography were normal. Elevated aldosterone level accompanying hyponatremia and hyperkalemia supported resistance to aldosterone in the kidney and directed the treatment of our patient.

To date, more than 40 variants have been reported in the genes encoding ENaC subunits (9), and these variants have most often been found in the gene encoding the alpha subunit. Eleven variants have been reported in the gene encoding the beta subunit (Table 1). Consequently, we first investigated the *SCNN1A* gene encoding the alpha subunit, but when no pathogenic variant was found, the *SCNN1B* gene was sequenced. In this patient, a novel c.978 C>A (p.Tyr326Ter) homozygous variant was detected, presumably leading to a premature stop codon in the *SCNN1B* gene. This variant has not been previously reported in the literature or in the GnomAD database including genome data from healthy individuals, and is anticipated to be a pathogenic change by Variant Taster, one of the *in silico* assessment tools used to predict pathogenicity of a variant. In addition, this change has been considered pathogenic according to the criteria of American College of Medical Genetics guidelines 2015 (PVS1, PM2, PP3).

The *SCNN1B* gene, consisting of 13 exons, encodes a transmembrane protein with two transmembrane segments with 640 amino acids (Figure 1) (7). The detected variant is located in the extracellular region of the protein, and, it is predicted to cause loss of function by creating an early stop codon, presumably resulting in nonsense mediated decay at the mRNA level.

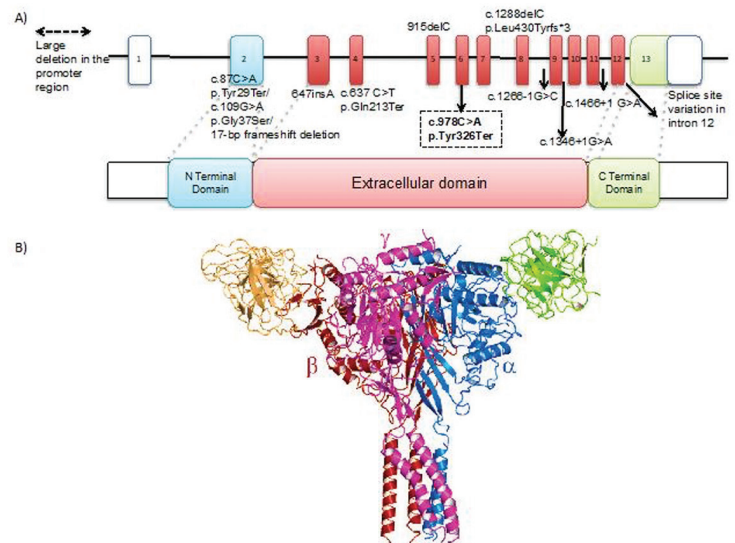


Figure 1. A) 3-D structure of the SCNN1B protein (PDB 6BQN) black arrow indicates the mutated position on the protein. B) Close up view of the tyrosine amino acid at the 326th position

To date, 11 variants with PHA due to *SCNN1B* variants have been reported (Table 1). These cases were diagnosed in infancy with classical findings. On follow-up, two cases died due to salt wasting crisis (6,8). In four cases, there were skin manifestations, such as dry skin, severe eczema, bullous dermatitis and hidradenitis suppurativa (7,10,11). Recurrent lung infections developed in four cases (7,11,12,13) and gastrostomy was required in four cases due to the salt wasting (8,10,11,13). Pulmonary hypertension developed in one case during follow-up (11). Apart from the case presented here, no other developed viral myocarditis and hypertension was encountered during attacks.

Both urgent and long-term treatments of PHA involve many challenges. Hyperkalemia can be life threatening due to the risk of cardiac arrhythmia. In the literature and similar to our case, there have been previous reports of peritoneal dialysis to correct hyperkalemia (7,14,15,16). Cases requiring gastrostomy due to difficulties in continuing oral treatment have also been reported (4,5,8,10,11,13,17). Patients with PHA are prone to pulmonary infections due to a decrease in sodium-dependent fluid absorption in the lungs. Rapid decompensation may occur during episodes of infection or when oral intake is impaired. After the electrolyte balance was achieved in the follow-up of our patient, salt wasting recurred due to intervening viral myocarditis and, during this period, treatments were given via nasogastric tube.

Conclusion

Systemic PHA is a challenging disease to manage, with severe salt wasting that starts in the neonatal period. In

Table 1. Clinical and laboratory features of this and other cases with SCNN1B mutation in the literature thoma

	Gender	Age of diagnosis	Na meq/L	K meq/L	Aldosteron ng/dL	Renin ng/mL/h	Genetic	Treatment	Current age	Additional findings	Clinical follow-up
Our case	M	1 month 25 days	123	7.1	640	16.3	c.978C > A (p.Tyr326Ter) (E6) Homozygous	NaCl, NaHCO ₃ , sodium polystyrene sulphate	7 months old	Myocarditis and hypertension	Once experienced salt wasting crisis during infection, now his development is appropriate for age
Chang et al (18)	-	19 days	133	8.2	*	-	c.109G > A (p.Gly37Ser) (E2) Homozygous	-	-	-	-
Kerem et al (21)	F	-	-	-	-	-	Two frame shift variations 647insA (E3)/915delC (E5) Compound heterozygous	-	18 years	High serum IgE concentration, normal spirometry and chest radiography	
Thomas et al (12)	-	4 days	127	10.2	1.281	235.5	Large homozygous deletion in the promoter region of of βENaC	NaCl, NaHCO ₃ , sodium polystyrene sulphate	7 years old	Recurrent lung infection	There is a decrease in the frequency of lung infections
Saxena et al (8)	M	7-8 days	< 120	8.5-10.5	> 1440	-	1669 + 1G > A splice site mutation in intron 12, Homozygous	NaCl, kayexalate	-	-	Recurrent salt- wasting crisis in newborn and infancy, gastrostomy was required, his growth and development was normal but he died at the age of 6.5 year after cardiac arrest
Edelheit et al (13) and Hanukoglu et al (20)	M	6 days	135	5.9	39.6-248.7	> 50	1669 + 1G > A splice site mutation in intron 12, Homozygous	NaCl, kayexalate	7 years old	Persistent clear nasal discharge, frequent lower respiratory infections and failure to thrive	Recurrent salt- wasting crisis, gastrostomy was performed at 14 months of age
Belot et al (10)	F	6 days	126	6.8	1.627	1335	c.637 C > T (p.Gln213Ter) (E4), Homozygous	-	3 years old	Bullous dermatitis	During follow-up, gastrostomy was opened, normal development at the age of 3 but still experiencing diarrhea and respiratory distress attacks
Dogan et al (19)	M	3 days	125	9	946	140	c.1266-1G > C splice site mutation in intron 8, Homozygous	NaCl, NaHCO ₃ , sodium polystyrene sulphate	3,5 years old	Vomiting, poor feeding	Short stature, decrease in dehydration attacks and in hospitalization with age

Nobel et al (11)	F	2-3 weeks	135	5,1	2.800	190	c.1288delC (p.Leu430 Tyrfs*3) (E9)/c.1466 + 1 G > A splice site mutation in intron 11 Compound heterozygous		32 years	Myalgia, hidradenitis suppurativa, pulmoner hypertension	Continuous hospitalization from 2 weeks to 2 years and NaCl, NaHCO ₃ and potassium chelation support with gastrostomy tube up to 3.5 years old, recurrent episodes of chronic bronchitis during childhood	
	Cayir et al (6)	M	9 days	106	11,8	317.5	98.2	c.87C > A (p.Tyr29Ter) (E2)/ c.1346 + 1G > A splice site mutation in intron 9 Compound heterozygous	NaCl, sodium polystyrene sulphate	-	-	During the follow up had seven salt wasting crisis and died in the last crisis at 6 months of age
		Gopal-Kothandapani et al (7)	F	1 day	128	7.8	64.7	-	c.1542 + 1G > A splice site mutation in intron 12	NaCl, NaHCO ₃ , sodium resonium	8 years old	Severe eczema
	Gopal-Kothandapani et al (7)		M	8 days	113	11	600	-	17-bp frameshift deletion in exon 2	NaCl, NaHCO ₃ , sodium resonium	14 years old	Dry skin

Plasma aldosterone concentration stated as 1 g/L (1-95) in the article.
Nomenclature of the variations are written as in the original publications.

this disease, life-threatening arrhythmias can be seen due to recurrent salt wasting and severe hyperkalemia. PHA1B can be confused with congenital adrenal hyperplasia. If a patient with hyperkalemia has hyponatremia, elevated urinary sodium excretion and low TTKG, mineralocorticoid resistance/deficiency should be considered. Treatment compliance is difficult due to the need for high dose oral salt and anti-potassium treatment. Long-term follow-up and treatment of these patients should careful, as the patients are frequently non-compliant with treatment and the frequency of rapid decompensation is high, especially during periods of infection.

Ethics

Informed Consent: Written informed consent was obtained from the parents.

Peer-review: Externally peer-reviewed.

Authorship Contributions

Surgical and Medical Practices: Gülin Karacan Küçükali, Semra Çetinkaya, Gaffari Tunç, M. Melek Oğuz, Nurullah Çelik, Kardelen Yağmur Akkaş, Saliha Şenel, Naz Güleray Lafcı, Şenay Savaş Erdeve, Concept: Gülin Karacan Küçükali, Semra Çetinkaya, M.Melek Oğuz, Saliha Şenel, Şenay Savaş Erdeve, Design: Gülin Karacan Küçükali, Naz Güleray Lafcı, Şenay Savaş Erdeve, Data Collection or Processing: Gülin Karacan Küçükali, Semra Çetinkaya, Gaffari Tunç, M. Melek Oğuz, Nurullah Çelik, Kardelen Yağmur Akkaş, Saliha Şenel, Naz Güleray Lafcı, Şenay Savaş Erdeve, Analysis or Interpretation: Gülin Karacan Küçükali, Semra Çetinkaya, M. Melek Oğuz, Saliha Şenel, Naz Güleray Lafcı, Şenay Savaş Erdeve, Literature Search: Gülin Karacan Küçükali, Şenay Savaş Erdeve, Naz Güleray Lafcı, Writing: Gülin Karacan Küçükali, Semra Çetinkaya, Şenay Savaş Erdeve, Naz Güleray Lafcı.

Financial Disclosure: The authors declared that this study received no financial support.

References

1. Rossier BC. The epithelial sodium channel (ENaC) and the control of blood pressure. *J Am Soc Nephrol* 1997;8:980-992. Epub 2013 Dec 12
2. Garty H, Palmer LG. Epithelial sodium channels: function, structure, and regulation. *Physiol Rev* 1997;77:359-396.
3. Canessa CM, Schild L, Buell G, Thorens B, Gautschi I, Horisberger JD, Rossier BC. Amiloride-sensitive epithelial Na⁺ channel is made of three homologous subunits. *Nature* 1994;367:463-467.
4. Amin N, Alvi NS, Barth JH, Field HP, Finlay E, Tyerman K, Frazer S, Savill G, Wright NP, Makaya T, Mushtaq T. Pseudohypoaldosteronism type 1: clinical features and management in infancy. *Endocrinol Diabetes Metab Case Rep* 2013;2013:130010. Epub 2013 Aug 30
5. Kala Ahluwalia, Dasouki M, Lennon A. Phenotypic variation of autosomal recessive pseudohypoaldosteronism type 1: a case in point. *Clin Case Rep* 2014;2:326-330. Epub 2014 Sep 15
6. Cayir A, Demirelli Y, Yıldız D, Kahveci H, Yaralı O, Kurnaz E, Vuralli D, Demirbilek H. Systemic pseudohypoaldosteronism type 1 due to 3 novel mutations in *SCNN1A* and *SCNN1B* genes. *Horm Res Paediatr* 2019;91:175-185. Epub 2019 Apr 24
7. Gopal-Kothandapani JS, Doshi AB, Smith K, Christian M, Mushtaq T, Banerjee I, Padidela R, Ramakrishnan R, Owen C, Cheetham T, Dimitri P. Phenotypic diversity and correlation with the genotypes of pseudohypoaldosteronism type 1. *J Pediatr Endocrinol Metab* 2019;32:959-967.
8. Saxena A, Hanukoglu I, Saxena D, Thompson RJ, Gardiner RM, Hanukoglu A. Novel mutations responsible for autosomal recessive multisystem pseudohypoaldosteronism and sequence variants in epithelial sodium channel α - β - γ - subunit genes. *J Clin Endocrinol Metab* 2002;87:3344-3350.
9. Nur N, Lang C, Hodax JK, Quintos JB. Systemic pseudohypoaldosteronism type I: A case report and review of the literature. *Case Rep Pediatr* 2017;2017:7939854. Epub 2017 Apr 18
10. Belot A, Ranchin B, Fichtner C, Pujo L, Rossier BC, Liutkus A, Morlat C, Nicolino M, Zennaro MC, Cochat P. Pseudohypoaldosteronisms, report on a 10- patient series. *Nephrol Dial Transplant* 2008;23:1636-1641.
11. Nobel YR, Lodish MB, Raygada M, Rivero JD, Faucz FR, Abraham SB, Lyssikatos C, Belyavskaya E, Stratakis CA, Zilbermint M. Pseudohypoaldosteronism type 1 due to novel variants of *SCNN1B* gene. *Endocrinol Diabetes Metab Case Rep* 2016;2016:150104. Epub 2016 Jan 7
12. Thomas CP, Zhou J, Liu KZ, Mick VE, MacLaughlin E, Knowles M. Systemic pseudohypoaldosteronism from deletion of the promoter region of the human β epithelial Na⁺ channel subunit. *Am J Respir Cell Mol Biol* 2002;27:314-319.
13. Edelheit O, Hanukoglu I, Gizewska M, Kandemir N, Tenenbaum-Rakover Y, Yurdakök M, Zajaczek S, Hanukoglu A. Novel mutations in epithelial sodium channel (ENaC) subunit genes and phenotypic expression of multisystem pseudohypoaldosteronism. *Clin Endocrinol (Oxf)* 2005;62:547-553.
14. Güran T, Degirmenci S, Bulut IK, Say A, Riepe FG, Güran Ö. Critical points in the management of pseudohypoaldosteronism type 1. *J Clin Res Pediatr Endocrinol* 2011;3:98-100. Epub 2011 Jun 8
15. Saravanapandian N, Paul S, Matthai J. Pseudohypoaldosteronism type 1: a rare cause of severe dyselectrolytemia and cardiovascular collapse in neonates. *J Clin Neonatol* 2012;1:224-226.
16. Sharma R, Pandey M, Kanwal SK, Zennaro MC. Pseudohypoaldosteronism type 1: management issues. *Indian Pediatr* 2013;50:331-333.
17. Önder A, Çetinkaya S, Kara C, Zenciroğlu A, Aycan Z. Multisystemic severe form pseudohypoaldosteronism: can gastrostomy be useful in management? *Turkish J Pediatr Dis* 2016;2:134-136.
18. Chang SS, Grunder S, Hanukoglu A, Rösler A, Mathew PM, Hanukoglu I, Schild L, Lu Y, Shirkets RA, Nelson-Williams C, Rossier BC, Lifton RP. Mutations in subunits of the epithelial sodium channel cause salt wasting with hyperkalemic acidosis, pseudohypoaldosteronism type 1. *Nat Genet* 1996;12:248-253.
19. Dogan CS, Durmaz, Parlak M, Akan M, Akcurin S, İffet B, Afig B. A novel splice site mutation of the beta subunit gene of epithelial sodium channel (ENaC) in one Turkish patient with systemic form of pseudohypoaldosteronism type 1. *J Pediatr Endocrinol Metab* 2012;25:1035-1039.
20. Hanukoglu A, Edelheit O, Shriki Y, Gizewska M, Dascal N, Hanukoglu I. Renin-aldosterone response, urinary Na/K ratio and growth in pseudohypoaldosteronism patients with mutations in epithelial sodium channel (ENaC) subunit genes. *J Steroid Biochem Mol Biol* 2008;111:268-274. Epub 2008 Jun 26
21. Kerem E, Biströtzer T, Hanukoglu A, Hofmann T, Zhou Z, Bennett W, MacLaughlin E, Barker P, Nash M, Quittell L, Boucher R, Knowles MR. Pulmonary epithelial sodium-channel dysfunction and excess airway liquid in pseudohypoaldosteronism. *N Engl J Med* 1999;341:156-162.