

## A CASE OF ANCA NEGATIVE WEGENER'S GRANULOMATOSIS (GRANULOMATOSIS WITH POLYANGIITIS) DIAGNOSED AS NEPHROTIC SYNDROME

NEFROTİK SENDROM TANISI ALAN ANCA NEGATİF WEGENER  
GRANÜLOMATOZU (POLİANJİTİS İLE SEYREDEN  
GRANÜLOMATOZİS) OLGUSU

**Saltuk Buğra KAYA<sup>1</sup>, Aşkı VURAL<sup>2</sup>, Süleyman Savaş HACİEVLYAGİL<sup>1</sup>,  
Zeynep Ayfer AYTEMUR<sup>1</sup>**

<sup>1</sup>İnönü Üniversitesi Tıp Fakültesi, Göğüs Hastalıkları Anabilim Dalı, Malatya, Türkiye

<sup>2</sup>İnönü Üniversitesi Tıp Fakültesi, İç Hastalıkları, Malatya, Türkiye

**Anahtar sözcükler:** Nefrotik Sendrom, kaviter lezyonlar, ANCA, Wegener granülomatozu, Polianjitis ile seyreden granülomatozis

**Keywords:** Nephrotic syndrome, cavitary lesions, ANCA, Wegener's granulomatosis, granulomatosis with polyangiitis

Geliş tarihi: 23 / 02 / 2017

Kabul tarihi: 08 / 08 / 2017

### ÖZ

Wegener granülomatozu (WG), üst ve alt solunum yolları, böbrekleri ve çeşitli organların granülomatöz vasküliti ile karakterize nadir bir hastalıktır. WG hastalığın ismi Polianjitis ile seyreden granülomatozis (GPA) olarak değiştirildi. Akciğer grafisindeki yaygın kaviter lezyonları, malignite ve tüberküloz ile radyolojik olarak ayırıcı tanıya girmesi nedeniyle hastaya bronkoskopi yapıldı. Her ne kadar c-ANCA pozitifliği sık görülse de bizim vakamız gibi immünsüpresif tedavi alan hastalarda negatif olabilir. WG (GPA) tanısı klinik semptomlar ve histopatolojik bulgular tanı önemli olsa da ANCA özgünlüğü hastalığının sonuçlarını tahmin yardımcı olur. Klinik, radyolojik bulguları ve tedavisi sonrası klinik ve radyolojik düzelme olan hasta WG (GPA) olarak kabul edilerek takip edildi.

### ABSTRACT

Wegener's granulomatosis (WG) is a rare disease of upper and lower respiratory tractuses, kidneys, and several organs characterized by granulomatous vasculitis. Name of WG disease was changed as Granulomatosis with Polyangiitis (GPA). Due to widespread cavitary lesions in chest x-ray bronchoscopy was performed to exclude tuberculosis and malignancies that were thought in the differential diagnosis. Although c-ANCA positivity is common, results may be negative in patients who get immunosuppressive treatment like this case. Clinical symptoms and histopathological findings are important for the diagnosis of WG (GPA) however ANCA specificity may help to predict the prognosis of the disease. This case was diagnosed as WG (GPA) after clinical and radiological findings and complete clinical and radiological regression after treatment.

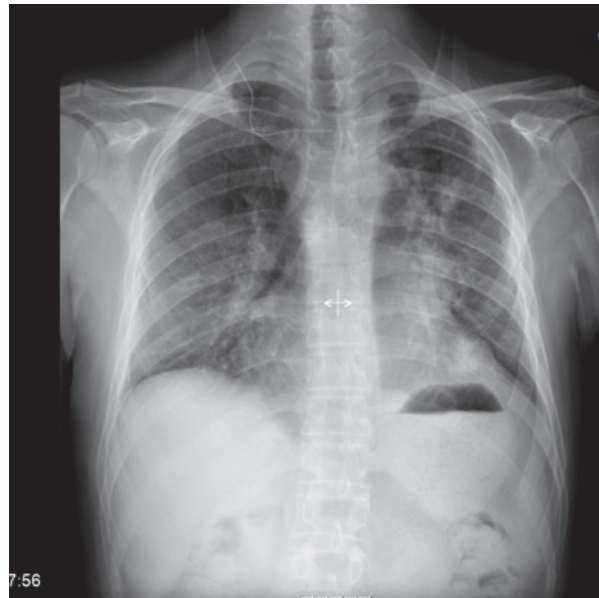
### INTRODUCTION

Wegener's granulomatosis (WG) is a rare disease with an annual incidence of 1/10 millions (1). It is a systemic disease characterized histopathologically by necrotizing granulomatosis which can affect upper airways, paranasal sinuses, lungs, kidneys as well as other organ systems (2). In 2011 name of WG disease was changed as "Granulomatosis with polyangiitis" and it was recommended to be abbreviated as "GPA" (3).

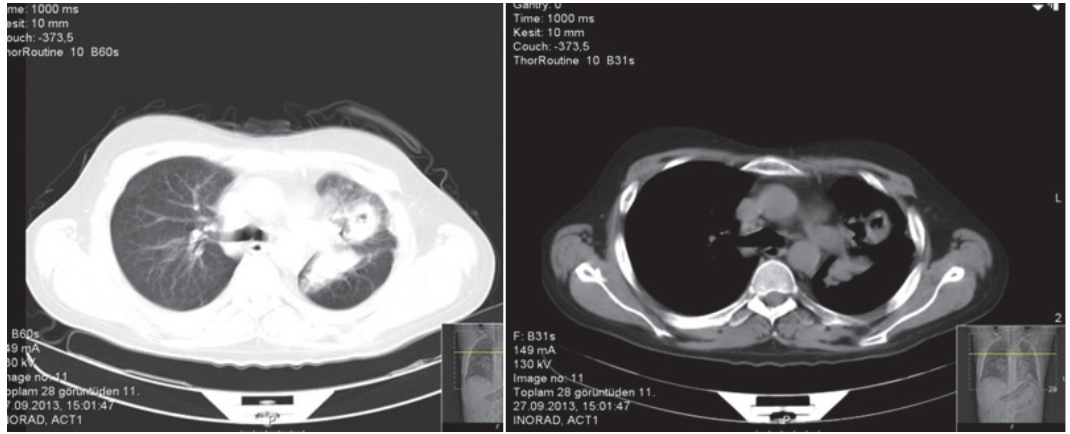
### CASE REPORT

A 33 years old male was admitted to hospital due to hemoptysis. His physical examination revealed moonface in inspection, and bilaterally decreased respiratory sounds without any additional sound in auscultation. Work-up after admission demonstrated leukocytosis and elevated CRP level. Amoxicillin-clavulanic acid 2 g/day was initiated. Chest X-ray and thoracic computed tomography showed multiple, bilateral, thick-walled cavitory lesions with irregular borders and ground glass appearance around these lesions (Figure 1, 2, 3). In the urinalysis of direct visual observation was cloudiness, three red blood cells per high power field (HPF) under a microscope. Six months previously, the patient undergone renal biopsy due to a diagnosis of nephrotic syndrome, and steroid and cyclosporin were initiated due to proteinuria of 5g/day. Renal biopsy could not be evaluated due to inadequate amount of tissue. With a presumptive diagnosis of connective tissue disorder, connective tissue markers were studied but all markers were negative. Due to widespread cavitory lesions in chest x-ray bronchoscopy was performed to exclude malignancies that were thought in the differential diagnosis. No endobronchial lesion was detected, bronchial lavage was obtained and transbronchial biopsy was performed.

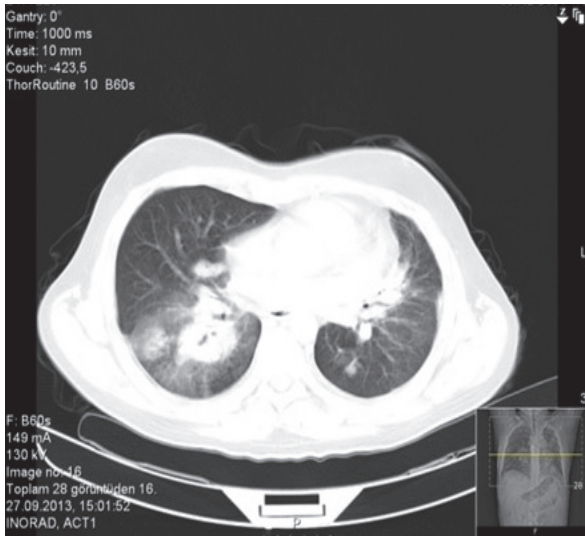
Neutrophilic infiltration at capillary walls was detected in biopsy, and his lavage cytology yielded benign signs. ARB and tuberculosis culture were negative. Preparates of renal biopsy which was performed in an outer center were reevaluated in our pathology department. The patient was consulted to Otorhinolaryngology department. No findings that favor vasculitis was detected in upper airway biopsy. Although a definite diagnosis could not be made because all biopsies were performed after immunosuppressive treatment for 6 months, vasculitis, particularly WG (GPA) was thought due to clinical and radiological findings, and a strong response to immunosuppressive treatment. Initial treatment was planned as 1 mg/kg/day prednisone and 2 mg/kg/day cyclophosphamide. Steroid treatment was tapered with 4 mg decreases at every second week and control visit at outpatient unit was recommended. Cavitory lesions significantly regressed in control chest X-ray and thoracic computed tomography after six months of treatment (Figure 4, 5).



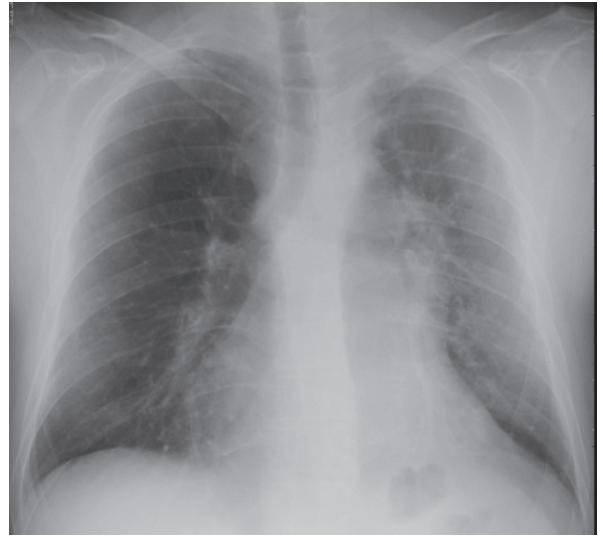
**Figure 1.** Chest X-ray at presentation.



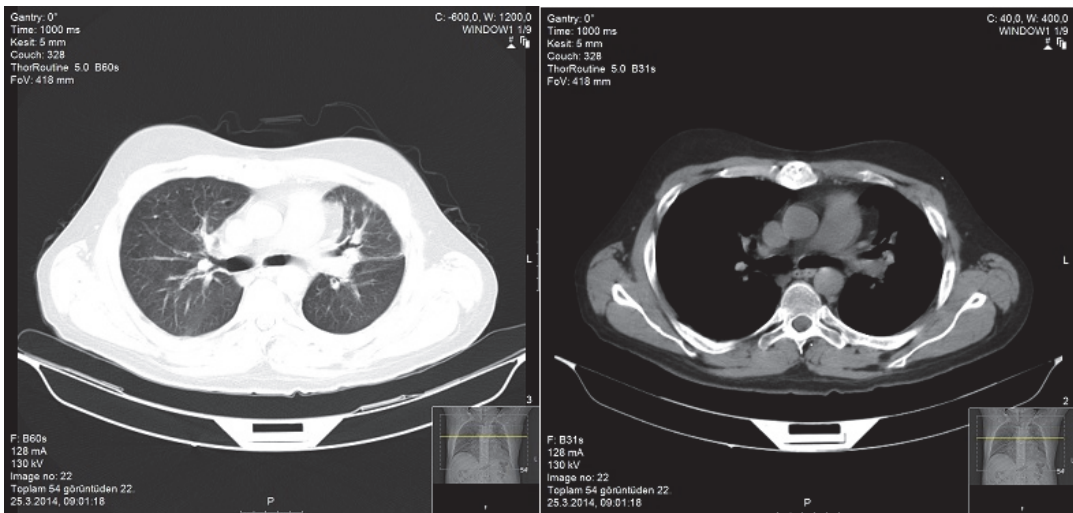
**Figure 2.** Cavitary lesion at left upper lobe.



**Figure 3.** Cavitary lesion at right lower lobe.



**Figure 4.** Control chest X-ray.



**Figure 5.** Control computed thoracic computed tomography.

### DISCUSSION

WG (GPA) is a systemic disease characterized histopathologically by necrotizing granulomatous vasculitis which can affect upper airways, paranasal sinuses, lungs, kidneys as well as other organ systems (2). WG without renal involvement is called as limited WG and WG with renal involvement is called as generalized WG. As our patient had renal involvement he was classified as generalized WG. Patients usually seek medical help due to constitutional symptoms. Hemoptysis may be seen in patients with lung involvement. The most common radiological picture is multinodular 1-10 cm lesions that may cavitate during the course (4). We detected bilateral, thick walled, multiple cavitory lesions with irregular borders and ground glass appearance around the lesions. In 1990, American College of Rheumatology defined criteria for WG. These were absence of nasal or oral inflammation, abnormal chest X-ray (nodule, inflammation or cavitory appearance), abnormal urinary sediment, hematuria, proteinuria, and demonstration of granulomatous inflammation at artery walls, or at perivascular or extravascular areas (4). Proteinuria, hematuria, and abnormal pulmonary radiological findings were present in our patient and we made diagnosis of WG according to these 2 criteria. European Medicines Agency (EMA) recommended that diagnosis of WG could be made in the presence of ANCA positivity in addition to fixed pulmonary infiltrates in chest X-ray; presence of nodules or cavity; observation of bronchial stenosis or bloody nasal discharge or nasal ulceration; chronic sinusitis, otitis media or mastoiditis; subglottic stenosis; destructive sinonasal diseases or glomerulonephritis: (++) hematuria, and (++) proteinuria or dysmorphic erythrocytes (5). Although serological negative c-ANCA can not exclude diagnosis of WG its positivity is the most important serological test for the diagnosis (sensitivity >75%, specificity 90-95%) (1). c- ANCA levels correlate with extent

and activity of disease and high ANCA titers were found to be associated with risk of exacerbation during remission period (6). In our case c-ANCA was negative and the patient was taking immunosuppressive treatment for a long time. c-ANCA titers was positive in 3 generalized WG cases and negative in one limited WG case among the 4 cases presented by Oymak et al and positive in 2 and negative in 1 cases among the 3 cases presented by Alatas et al (7,8).

Glomerulonephritis develops in 75% of WG (GPA) cases at the beginning or during the course of disease. Histologically, WG (GPA) most commonly cause focal necrotizing glomerulonephritis, less commonly cause progressive crescentic glomerulonephritis and it may rapidly progress to renal failure. Urine analysis shows hematuria, proteinuria, and erythrocyte casts (9). We also detected segmental sclerosing areas, and membrane thickening in renal biopsy and there were proteinuria and hematuria. Due to cavitation of the lesions tuberculosis and malignancy had to be excluded in differential diagnosis. Ertürk et al published a case of WG that mimic lung cancer and tuberculosis (10). We excluded tuberculosis and malignancy because ARB was negative in bronchial lavage, no growth was observed in tuberculosis culture, and evaluation of transbronchial biopsy for malignancy was negative. Treatment includes immunosuppressive drugs and in some cases plasmapheresis. A study by Fauci et al found that combination of 1 mg/kg/day prednisone and 2 mg/kg/day cyclophosphamide achieved remission in 90% patients (11). Although this treatment achieved high remission rate IV pulse cyclophosphamide and oral steroid treatment were used as an alternative due to high rate of side effects during follow up (9,12). Although some authors claim pulse cyclophosphamide treatment to be as effective as oral treatment, standard National Institute of Health protocol is still recommended due to high rate of recurrence (13).

Diagnosis of WG (GPA) patients is difficult because their symptoms are nonspecific and disease course is subacute or chronic. Diagnosis may delay in patients who present with nephrologic and urologic symptoms and take a diagnosis of nephrotic syndrome like in our case. Appearance of moonface was detected in this patient due to systemic corticosteroid side effect (iatrogenic Cushing's syndrome). c-ANCA may rarely be negative in

WG (GPA) which has a high morbidity and mortality. ANCA positivity is not included in American Rheumatology Association's criteria (14). We presented a case of WG (GPA) with negative c-ANCA who presented with hemoptysis, and diagnosed as nephrotic syndrome under the light of literature.

#### REFERENCES

1. Takwoingi YM, Dempster JH. Wegener's granulomatosis: an analysis of 33 patients seen over a 10-year period. *Clin Otolaryngol* 2003; 28(3): 187.
2. Schilder AM. Wegener's granulomatosis vasculitis and granuloma. *Autoimmun Rev* 2010; 9(7): 483-7.
3. Falk RJ, Gross WL, Guillevin L, et al. Granulomatosis with polyangiitis (Wegener's): An alternative name for Wegener's granulomatosis. *Arthritis Rheum* 2011; 63(4): 863-4
4. Leavitt RY, Fauci AS, Bloch DA, et al. The American College of Rheumatology 1990 criteria for the classification of Wegener's granulomatosis. *Arthritis Rheum* 1990; 33(8): 1101-7.
5. Falk RJ, King TE, Stone JH. Clinical manifestations and diagnosis of Wegener's granulomatosis and microscopic polyangiitis 2010 sept: 31.03.2011. [www.uptodate.com](http://www.uptodate.com)
6. Düzgün N. Wegener Granülomatozu. Ankara İç Hastalıkları Romatoloji kitabı. 348-52. [http://ichastaliklarimatoloji.medicine.ankara.edu.tr/?page\\_id=44](http://ichastaliklarimatoloji.medicine.ankara.edu.tr/?page_id=44).
7. Oymak FS, Doğukan A, Gülmez İ ve ark. Wegener Granülomatozisi: Dört Olgu Sunumu. *Solunum Hastalıkları* 2002; 13: 120-5.
8. Alataş F, Metintaş M, Özkan R, ve ark. Üç Olgu Nedeniyle Wegener Granülomatözü. *Tüberküloz ve Toraks Dergisi* 2003; 51(4): 440-5.
9. Hoffman GS, Kerr GS, Leavitt RY, et al. Wegener granulomatosis: An analysis of 158 patients. *Ann Intern Med* 1992; 116: 488-98.
10. Ertürk A, Ulukavak T, Demirağ F ve ark. Wegener granülomatozisi (akciğer tüberkülozu ve kanserini taklit eden bir olgu nedeniyle). *Tüberküloz ve Toraks* 1998;46(2):269-73
11. Fauci AS, Haynes BF, Katz P, Wolff SM. Wegener's granulomatosis: Prospective clinical and therapeutic experience with 85 patients for 21 years. *Ann Intern Med* 1983;98:76-85.
12. Hoffman GS, Leavitt RY, Fleisher TA, Minor JR, Fauci AS. Treatment of Wegener's granulomatosis with intermittent high-dose intravenous cyclophosphamide. *Am J Med* 1990;89:403-10
13. Guillevin L, Cordier JF, Lhote F, et al. A prospective, multicenter, randomized trial comparing steroids and pulse cyclophosphamide versus steroids and oral cyclophosphamide in the treatment of generalized Wegener's granulomatosis. *Arthritis Rheum* 1997;40:2187-98.
14. Lionaki S, Blyth ER, Hogan SL, et al. Classification of ANCA vasculitides: The role of anti-neutrophil cytoplasmic autoantibody specificity for MPO or PR3 in disease recognition and prognosis. *Arthritis Rheum* 2012 ; 64(10): 3452-3462

#### Yazışma Adresi:

Dr. Saltuk Buğra Kaya  
İnönü Üniversitesi Tıp Fakültesi, Göğüs Hastalıkları  
Anabilim Dalı, Malatya, Türkiye  
[saltukbugrakaya@gmail.com](mailto:saltukbugrakaya@gmail.com)