

## Nd :YAG CONTACT LASER ARTHROSCOPY Preliminary Report

O. SAHAP ATIK\*  
ERTUGRUL SENER\*  
SELÇUK BÖLÜKBASI\*  
ERDAL CILA\*

*SUMMARY: Arthroscopic surgery was performed using 15 to 40 watts Nd: YAG contact laser in 61 patients on 57 knee and 4 shoulder joints. Lateral retinacular release was done in 6 patients, partial synovectomy in 7, chondroplasty in 26, debridement in 24 patients and meniscectomy in 21 cases. Bleeding during these procedures and swelling after the intervention were minimal and the wound healing was normal with no serious complications. The recovery period was short and was followed by satisfactory restoration of function.*

*Key Words: Arthroscopic Laser Surgery.*

### INTRODUCTION

The word LASER is an acronym for light amplified by stimulated emission of radiation. The development of laser light is based on the principle that electrical energy introduced into the atoms or molecules of a crystal of gas causes the release of quanta of energy from the atoms or molecules within the substance (3). Because of recent break through in Neodymium YAG (Nd: YAG) contact fiber technology, Nd: YAG lasers have become quite useful in arthroscopy. These capture the laser energy at the tip of the fiber and are capable of producing extremely precise cutting, vaporizing, and coagulating in joint tissues with minimal thermal damage (3, 4).

The purpose of this clinical study was to evaluate the benefits of Nd: YAG contact laser on intra articular tissues.

### MATERIALS AND METHODS

61 patients were treated with arthroscopic surgery using Nd: YAG contact laser. The mean age was 38 years (18-66).

The pathology was in knees in 57 patients and in shoulders in 4 patients. In the knee joint; lateral retinacular release in 6 patients, partial synovectomy in 7 patients, chondroplasty in 26 patients, debridement in 24 patients and partial meniscectomy in 21 patients were performed. All patients complained of pain during the first interview and the range of motions of the involved joints were limited. Forty of the patients complaining of their knees had preoperative effusion. Only debridement and partial synovectomy were done in shoulder joints. During these procedures 15-40 watts laser energy was used. All the operations were performed under general, regional or local anesthesia.

Active motion exercises were started and full weight bearing was allowed on first postoperative day.

### RESULTS

No complications were encountered during the surgical procedures using laser. In the postoperative period, six patients complaining of their knees developed minimal effusion. There were no complications due to laser instruments and the wounds healed at normal periods.

Active joint exercises were started immediately after the operations and the knee patients were able to walk

---

\*From Gazi University, Medical Faculty, Department of Orthopaedic Surgery, Ankara, Turkiye.

Figure 1: Treatment of degenerated meniscus with arthroscopic laser surgery, FC: femoral condyle, M: meniscus, TP: tibial plateau, L: laser probe.

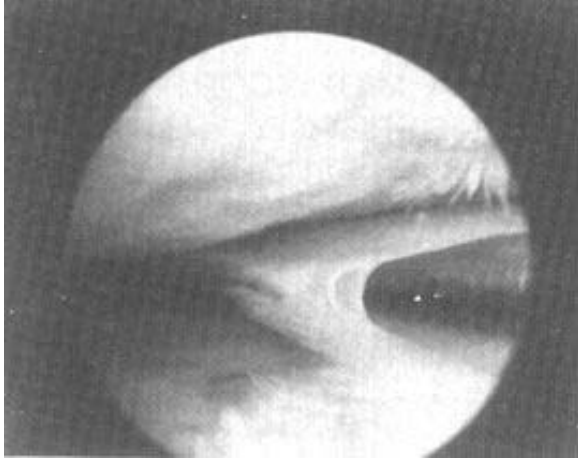
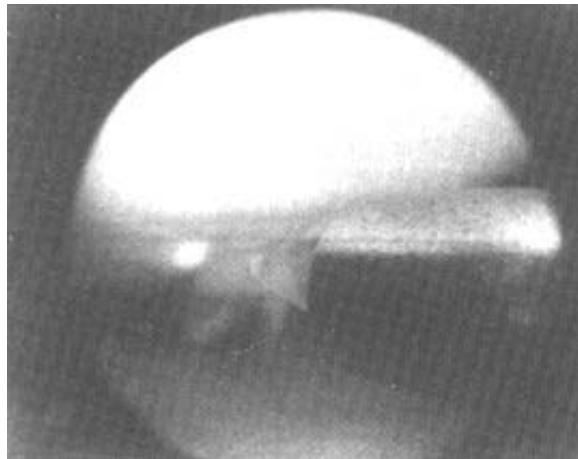


Figure 2: Debridement of femoral defect with arthroscopic laser surgery, FC: femoral condyle, TP: tibial plateau, L: laser probe.



with full weight bearing on the first postoperative day. The recovery and rehabilitation period was very short and return to work was rapid.

During the follow up evaluation, all patients were pain free and had normal range of motions (Figure1, Figure 2).

#### DISCUSSION

Arthroscopic surgery with laser has been developed to the point where it now provides surgical capabilities

beyond what has been available in either mechanical or electro surgical instruments. Lasers in arthroscopic surgery have many potential advantages over conventional surgical methods (1-5). These include minimal mechanical trauma to cartilage and other tissues greater accessibility to difficult areas of the joints, minimal bleeding, less risk of instrument breakage. The Nd: YAG laser effectively operates in a fluid medium allowing continuous irrigation of the joint with saline. The Nd: YAG contact laser is transmitted by fiberoptics allowing efficient maneuvering within the joint and be placed in direct contact with tissue, making it more effective in cutting as well as coagulating tissue (1-3).

In our series, there was no scuffing of the articular tissue, no joint trauma, and no significant bleeding. The results also confirm that the recovery time achieved using Nd: YAG contact laser was shorter than conventional methods resulting in a more rapid return to work for all patients.

In conclusion, lasers in arthroscopic surgery have the potential to become a useful tool for the precise arthroscopic removal of intraarticular tissue.

#### REFERENCES

1. Atik OS, Sener E, Bölükbaşı S and Cila E : Laser in arthroscopic surgery. *J Arthroplasty Arthroscopic Surg* 5:1-3, 1992.
2. Garcia PG : Arthroscopic laser surgery in treating the knee injuries of leading professional athletes. *Am J Arthroscopy* 9:15, 1991.
3. O'Brien SJ, Garrick JG, Jackson RW, Sherk HH, Smith CF and Wangness CT : Lasers in orthopedic surgery. *Contemporary Orthop* 1:61-91, 1991.
4. Sherk HH : Orthopedist using lasers in surgery. *Am J Arthroscopy* 9:7-8, 1991.
5. Trauner K, Nishioka N and Patel D : Pulsed Ho: YAG laser ablation of fibro cartilage and articular cartilage. *Am J Sports Med* 3:316-320, 1990.

Correspondence:

O. Sahap Atik  
Gazi Üniversitesi  
Tıp Fakültesi  
Ortopedik Cerrahi Bölümü  
Ankara, TÜRKİYE.