

Comparison of cannulated screw and kirschner wire in the chevron osteotomy of hallux valgus

Eyup SENOCAK¹, Nasuhi ALTAY², Mehmet DEMİR², Umit AYGUN³

¹ Department of Orthopaedics and Traumatology, Ataturk University, Erzurum

² Department of Orthopaedics and Traumatology, Erzurum City Hospital, Erzurum

³ Department of Orthopaedics and Traumatology, Ibrahim Cecen University, Ağrı

Correspondence

Eyüp ŞENOCAK

Atatürk Üniversitesi Ortopedi ve Travmatoloji Anabilim Dalı 25144 Erzurum, Türkiye.

e-mail: eyupsenocakmd@gmail.com

ABSTRACT

This study aimed to compare the outcomes of Chevron osteotomy for hallux valgus fixation using a cannulated screw versus a Kirschner wire.

This study included 20 feet of 23 patients with hallux valgus fixed with a cannulated screw (Group A) and 22 feet of 18 patients with hallux valgus fixed with a Kirschner wire (Group B) between 2015 and 2020. We excluded one patient who was infected and three patients who could not be contacted. We evaluated our patients retrospectively.

No significant difference was found between the postoperative early- and late-stage hallux valgus angles in both groups ($P > 0.05$). Likewise, no significant intergroup difference was not found between the postoperative early- and late-stage intermetatarsal angle values ($P > 0.05$). Patients in Group B were followed up for an average of 18.2 months, whereas patients in Group A were followed up for an average of 17.4 months. No significant difference was observed between the two implants in terms of the union time of the osteotomy line ($P > 0.05$). The time to union was significantly longer in the male patient group than in the female patient group, regardless of the type of implant used.

Key words: Kirschner Wire, Cannulated Screw, Hallux Valgus

INTRODUCTION

Hallux valgus (HV) is one of the common foot diseases characterized by lateral deviation of the big toe and medial deviation of the first metatarsal bone. HV not only affects the external appearance of the foot but also affects bodily functions and daily quality of life, such as foot pain and impaired gait pattern (1-4).

The incidence of this disease in the general population, regardless of sex and age, is 0.9% (5). Its incidence is 12%–33% higher in women than in men, which was mainly attributed to wearing tight or high-heeled shoes (6). However, the involvement of intrinsic and extrinsic factors in the pathogenesis of the disease has been reported, but the cause has not been fully elucidated. As a result of the compression of the skin and subcutaneous tissue with shoes, a protruded reactive bone tissue called bunion is formed at the metatarsal head. The presence of a bunion causes serious pain besides mechanical problems in the foot (5,6).

When evaluating HV, its three stages are determined using the angle of HV and the intermetatarsal

angle. Those with an HV angle of 15°–20°, 20°–40°, and >40° are considered to have mild, moderate, and advanced HV. Conservative methods such as night splints, interdigital supports, and foot exercises are first used in patients with mild HV (7). However, recent studies have shown that conservative treatment is not superior to no treatment in patients with moderate and severe HV (7). Surgery can be performed in patients with moderate and severe HV if clinical findings are evident.

The basic logic behind more than a hundred surgical techniques defined as surgical treatment is to reduce the increased HV angle and the intermetatarsal angle. Proximal, shaft, and distal metatarsal osteotomies have been defined. Shaft and distal osteotomies are generally preferred in moderate HV, whereas proximal osteotomies are more frequently preferred in advanced HV (8). Since these osteotomies require a rigid fixation after correction, the implants used are also important. In our study, we included patients with HV who underwent Chevron osteotomy to the distal metatarsal.

Distal Chevron osteotomy (DCO) was first described by Austin and Leventen; no bone fixation was performed with an implant as first described (8). Implants such as headless titanium cannulated screw, Kirschner wire, bioabsorbable screws, and Herbert screws are widely used in the fixation procedure performed in DCO.

In our study, we aimed to evaluate and compare the effectiveness of these implants in preserving osteotomy reduction, and preoperative and postoperative visual analogue scale (VAS) and American Orthopedic Foot and Ankle Society (AOFAS) scores, using a headless cannulated screw and a Kirschner wire in the fixation performed with DCO. We examined different fixation systems used for HV treatment with DCO. Similar results were achieved regardless of whether expensive, complex materials or cheap and simple materials were used for HV treatment.

MATERIALS AND METHODS

We retrospectively evaluated 24 feet of 20 patients diagnosed with HV, who underwent DCO fixation with two headless cannulated screws, and 21 feet of 18 patients who had DCO fixation with 2 Kirschner wires between 2015 and 2020 in our clinic. These patients had regular follow-ups and related records. Two patients with Kirschner wire fixation, who received antibiotherapy due to infection and whose follow-up was prolonged, and four patients who had fixation using cannulated screws without postoperative follow-up data were excluded from the study. Demographic information and radiological images of the patients were obtained from the hospital archives and PACS system with the approval of the hospital ethics committee. Patient data were reviewed retrospectively.

The patients were operated in the supine position under spinal anesthesia with a tourniquet. A medial incision extending proximally from the metatarsal head was made during the surgery. The capsule was split open, and the bunion was minimally excised. During this procedure, the dorsal and plantar medial cutaneous nerves were preserved. The metatarsophalangeal (MTF) joint was distracted, and an adductor tenotomy was performed through the joint lateral to the metatarsal head. The modified Chevron osteotomy was performed using a standard low-speed precision saw. Osteotomy was performed through a 60-degree angled V-shaped osteotomy incision whose concavity faced distally.

After osteotomy, the distal part was lateralized for 2–4 mm, and two pieces of 1.6-mm Kirschner wires in Group A and two pieces of 2.5-mm cannulated screws in Group B were inserted retrogradely from the metatarsal head for fixation. Kirschner wire and cannulated screw were embedded in the subchondral tissue. The capsule was sutured without significant plication not to increase the joint pressure. The surgery was completed by suturing the subcutaneous tissue.

An elastic bandage and a fingertip silicon pad were recommended to the patients in both groups during the postoperative period. Patients whose sutures were removed in the second week were allowed weightbearing on the feet as much as they could tolerate. Active MTF joint motion was started in all patients during the early postoperative period. At the end of the sixth week, the feet of all patients were allowed full weightbearing.

During the radiological evaluation of the patients, preoperative, early postoperative (sixth week after the surgery), and postoperative late period (sixth month postoperatively) AP and lateral standing-foot radiographs were used. The HV angle, the change in the intermetatarsal angle on the standing AP x-ray, and the reduction in the lateral x-ray were evaluated. Preoperative and postoperative radiographic images of a 33-year-old male patient with HV treated with cannulated screws are shown in [Figs 1 and 2](#), respectively. Measurements were made as described by the AOFAS (9). The effectiveness of the headless cannulated screw and Kirschner wire in preserving reduction was compared during the follow-up. The patients were divided into two groups: cannulated screw (Group A) and Kirschner wire (Group B) groups. Preoperative and postoperative radiographic images of a 22-year-old female patient with hallux valgus treated with Kirschner wires are shown in [Figs. 3 and 4](#), respectively.

During the clinical evaluation of the patients, preoperative and postoperative sixth-month VAS and AOFAS scores were retrospectively scanned and used from patient records. VAS is a self-assessment pain rating system scored between 0 and 10, with 0 expressing a completely painless condition and 10 being the most painful condition. The AOFAS foot function index scoring system evaluates pain, function, and alignment on a scale of 0–100 points, with 0 representing the worst condition. Pain is evaluated with 40 points, function with 45 points, and alignment with 15 points (10).

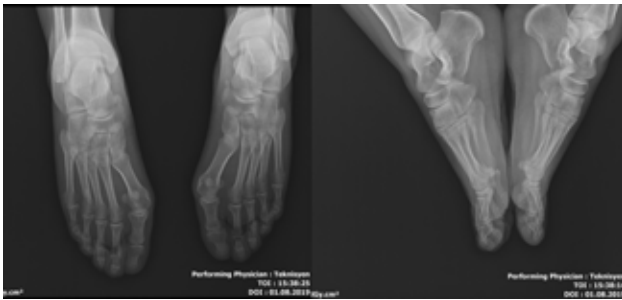

Figure 1 Preoperative radiographic images of a 33-year-old male patient with HV treated with cannulated screws.

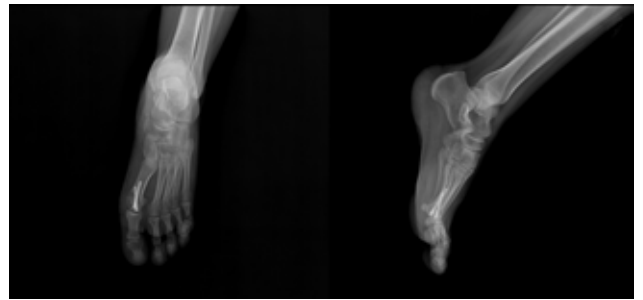


Figure 2 Postoperative radiographic images of a 33-year-old male patient with HV treated with cannulated screws.

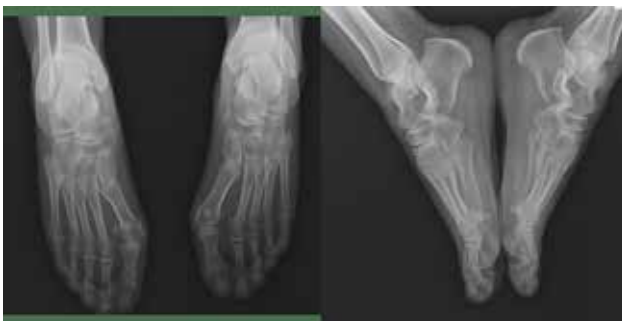

Figure 3 Preoperative radiographic images of a 22-year-old female patient with hallux valgus treated with Kirschner wires.

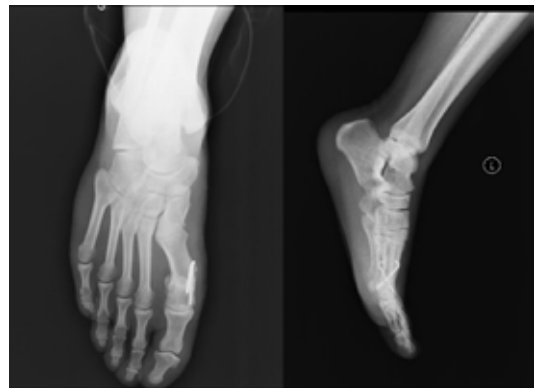

Figure 4 Postoperative radiographic images of a 22-year-old female patient with hallux valgus treated with Kirschner wires.

Statistical analysis

In descriptive statistics, numerical data were given as mean and standard deviation, and categorical data as numbers and percentages. We analyzed the distribution of numerical data using a histogram, assessed repeated numerical data with an independent-sample *t* test, and examined independent variables with a Student *t* test. Statistical significance was set at $P < 0.05$. SPSS 23.0 package program was used in the analysis.

RESULTS

In our study, 24 feet of 20 patients in Group A and 22 feet of 19 patients in Group B were evaluated. Thirteen (65%) female and 7 (35%) male patients in Group A and 10 (53%) female and 9 (47%) male patients in Group B were evaluated. The mean age was 41.9 (16–75) and 38.9 (19–66) years in Groups A and B, respectively.

In Group A, the preoperative HV and intermetatarsal angle values were significantly higher than the postoperative early and late period angle values ($P < 0.05$).

In Group B, the preoperative HV and intermetatarsal angle values were significantly higher than the postoperative early and late period angle values ($P < 0.05$).

No significant difference was observed between the postoperative early and late period HV angles in both groups ($P > 0.05$). Likewise, no significant intergroup difference was found between the postoperative early- and late-stage intermetatarsal angle values ($P > 0.05$).

Group B was followed up for an average of 18.2 months and Group A for an average of 17.4 months.

No significant difference was observed between the two implants in terms of the union time of the osteotomy line ($P > 0.05$). However, the time to union was significantly longer in the male patient group than in the female patient group, regardless of the type of implant used.

In Group A, the preoperative and postoperative sixth-month mean VAS scores were 7.2 and 2.9, respectively, with a significant improvement ($P = 0.031$). The preoperative and postoperative sixth-month mean AOFAS scores were 47.5 and 78, respectively, with a significant improvement ($P = 0.022$).

In Group B, the preoperative and postoperative sixth-month mean VAS scores were 7.6 and 6.7, respectively, without any significant improvement ($P > 0.05$). The preoperative and postoperative sixth-month mean AOFAS scores were 52.7 and 72.4, respectively, with a significant improvement ($P = 0.043$).

DISCUSSION

If HV becomes symptomatic enough to affect the quality of daily life and pain becomes prominent, it usually requires surgical correction. DCO is one of the most commonly used techniques for treating HV. This technique was first described in 1976 at the Mayo Clinic; better results were obtained by adding soft tissue procedures such as adductor tenotomy (11,12). In all cases reported in our study, we also used a combined soft tissue procedure by the transarticular release of the adductor hallucis tendon, transverse metatarsal ligament, and lateral joint capsule, besides DCO. However, we omitted medial plication to avoid increasing joint pressure.

Many authors achieved temporary fixation with threads passed through the channels opened in the bone after DCO and reported positive results by not using implants. However, the necessity of using an implant has become a general opinion after the increase in relevant studies performed and the potential risk of malunion (13,14). Although many implant types have been defined, we compared the results of fixation with two Kirschner wires and headless cannulated screws applied proximally from the metatarsal head.

Many authors suggested lateral translation involving 2–5 mm or one third of the metatarsal head in DCO. Others also reported that the translation of more than 5 mm increased the risk of avascular necrosis (15,16). We also used lateral translation for 2–4 mm in our cases and did not detect avascular necrosis in any of our cases.

The implant removal rates after HV surgery vary between 2.3% and 23.6%, and implant removal is not preferred unless necessary due to the surrounding fragile soft tissue cover (17). We also did not remove implants except for two patients with osteoporosis in the Kirschner wire group due to joint irritation.

Loss of reduction can be seen after fixation in DCO. Therefore, fixation with a rigid material is required. Screws, Kirschner wires, Steinmann pins, and staples have been used in fixation, and successful results have been reported in many series (18). In a study performed with cannulated screws, the mean preoperative HV angle and intermetatarsal angle values were found to be statistically significantly higher than the early and late postoperative mean values. However, no statistically significant difference was observed in the mean values of the same angles observed during the early and late postoperative periods (19).

Similarly, in our study, the preoperative HV and intermetatarsal angle values were found to be significantly higher than postoperative early and late angle values in the cannulated screw group ($P < 0.05$). However, no significant difference was observed between postoperative early- and late-stage HV and intermetatarsal angle values.

In a similar study in which HV fixation was performed using Kirschner wires, a significant difference was observed between preoperative and postoperative late-stage mean HV and intermetatarsal angle values (20). In our study, a significant difference was observed between the mean preoperative and postoperative early- and late-stage HV and intermetatarsal angles ($P < 0.05$), but the difference between the postoperative early- and late-stage angles was not significant.

In a similar study, the preoperative and postoperative AOFAS scores were found to be 50.7 and 86.8, respectively, in the Kirschner wire group (21). In the same study, the preoperative and postoperative AOFAS scores were evaluated as 52.4 and 87.7, respectively, in the cannulated screw group. Similarly, in our study, the preoperative and postoperative mean AOFAS scores were 52.7 and 72.4, respectively, in the Kirschner wire group. Also, the preoperative and postoperative sixth month mean AOFAS scores were 47.5 and 78, respectively, in the cannulated screw group, with a statistically significant difference in AOFAS values in the two patient groups.

In a similar study, the preoperative and postoperative mean VAS scores were 5.1 and 2, respectively, in the cannulated screw group, with a statistically significant intergroup difference (22). In our study,

the preoperative and postoperative sixth-month VAS scores were 7.2 and 2.9, respectively, with a statistically significant intergroup difference.

The limitations of our study were a relatively small number of patients and the need for a retrospective evaluation. Besides this limitation, our study was one of the few studies comparing the use of a cannulated screw and a Kirschner wire in DCO of HV.

Cannulated screw and Kirschner wire are stable and proper implants preferred in the fixation performed with DCO for treating HV. Although implant problems such as irritation seem to be highly prevalent in fixations made with a Kirschner wire, no significant difference was demonstrated between the two fixation methods.

Ethical approval

All procedures performed in studies involving human participants were in accordance with the ethical standards of the institutional and/or national research committee and with the 1964 Helsinki Declaration and its later amendments or comparable ethical standards.

Conflicts of Interest: None declared.

Funding: None declared.

REFERENCES

- Nix S, Smith M, Vicenzino B: Prevalence of hallux valgus in the general population: a systematic review and meta-analysis. *J Foot Ankle Res* 2010, 3:21.
- Cho NH, Kim S, Kwon DJ, Kim HA: The prevalence of hallux valgus and its association with foot pain and function in a rural Korean community. *J Bone Joint Surg Br* 2009, 91:494-498.
- Abhishek A, Roddy E, Zhang W, Doherty M: Are hallux valgus and big toe pain associated with impaired quality of life? A cross-sectional study. *Osteoarthritis Cartilage* 2010, 18:923-926.
- Menz HB, Roddy E, Thomas E, Croft PR: Impact of hallux valgus severity on general and foot-specific health-related quality of life. *Arthritis Care Res (Hoboken)* 2011, 63:396-404.
- V. Heizmann, F. Capanni, T. Engleder, and A. Appelt, "Development of an extra-osseous nitinol implant for the hallux valgus treatment: preliminary mechanical investigations, design and numerical simulation," *Biomedical Engineering/ Biomedizinische Technik*, vol. 57, pp. 918-921, 2012.
- M. E. Easley and H. J. Trnka, "Current concepts review: hallux valgus part 1: pathomechanics, clinical assessment, and nonoperative management," *Foot & Ankle International*, vol. 28, no. 5, pp. 654-659, 2007.
- Radovic PA, Shah E. Nonsurgical treatment for hallux abducto valgus with botulinum toxin A. *J Am Podiatr Med Assoc* 2008;98:61-5.
- D.W. Austin and E. O. Leventen, "A new osteotomy for Hallux Valgus: A horizontally directed 'V' displacement osteotomy of the metatarsal head for Hallux Valgus and primus varus," *Clinical Orthopaedics and Related Research*, vol. 157, pp. 25-30, 1981.
- M. J. Coughlin, C. L. Saltzman, and J. A. Nunley, "Angular measurements in the evaluation of hallux valgus deformities: A report of the ad hoc committee of the american orthopaedic foot & ankle society on angular measurements," *Foot & Ankle International*, vol. 23, no. 1, pp. 68-74, 2002.
- D. Gould et al. Visual Analogue Scale (VAS). *Journal of Clinical Nursing* 2001; 10:697-706
- Potenza V, Caterini R, Farsetti P, et al. Chevron osteotomy with lateral release and adductor tenotomy for hallux valgus. *Foot Ankle Int* 2009;30:512-516.
- Corless JR. A modification of the Mitchell procedure. *J Bone Joint Surg [Br]* 1976; 58 B:138.
- Crosby LA, Bozarth GR. Fixation comparison for chevron osteotomies. *Foot Ankle Int.* 1998 Jan;19(1):41-3. doi: 10.1177/107110079801900108. PMID: 9462912.
- Singh SK, Jayasekera N, Nazir S, Sharif K, Kashif F. Use of a simple suture to stabilize the chevron osteotomy: a prospective study. *J Foot Ankle Surg.* 2004; 43 (5):307- 311,.
- Kitaoka HB. Chevron osteotomy. In: Kitaoka HB, ed. *Master techniques in orthopaedic surgery: the foot and ankle*. Second ed. Philadelphia: Lippincott Williams and Wilkins, 2002:29-44.
- Meyerson MS. Hallux valgus. In: Meyerson MS, ed. *Foot and ankle disorders*. Philadelphia: WB Saunders, 2000:213-288.
- T. Jentzsch, N. Renner, R. Niehaus et al., "The influence of the number of screws and additional surgical procedures on outcome in hallux valgus treatment," *Journal of Orthopaedic Surgery and Research*, vol. 13, no. 1, 2018.
- Teli M, Grassi FA, Montoli C, et al. The Mitchell bunionectomy: a prospective study of 60 consecutive cases utilizing single K-wire fixation. *J Foot Ankle Surg* 2001; 40: 144-151.
- Peker G, Karaali E, Bilgili MG, Ercin E, Bayrak A, Avkan MC. Evaluation Of Rigid Internal Screws Used In Lindgren-Turan Operation. *Med J Bakirkoy.* 2014; 10(3): 111-115
- Winemaker MJ, Amendola A. Comparison of Bioabsorbable Pins and Kirschner Wires in the Fixation of Chevron Osteotomies for Hallux Valgus. *Foot & Ankle International.* 1996;17(10):623-628. doi:10.1177/107110079601701007
- Bilgin E, Keçeci T, Turgut A, Adiyek L, Kilinc BE. Comparison of Clinical and Radiological Results of Two Fixation Materials after Distal Chevron Osteotomy for Hallux Valgus? - Two Kirschner Wires versus Single Screw Fixation. *Acta Chir Orthop Traumatol Cech.* 2020;87(5):350-355. English. PMID: 33146604.
- Acar, Baver & Kose, Ozkan & Turan, Adil & Ünal, Melih & Kati, Yusuf & Guler, Ferhat. (2018). Comparison of Bioabsorbable Magnesium versus Titanium Screw Fixation for Modified Distal Chevron Osteotomy in Hallux Valgus. *BioMed Research International.* 2018. 1-9. 10.1155/2018/5242806.