

Bilateral Simultaneous Femoral Fragility Fractures after Long-term Alendronate Therapy

Yalçın TURHAN¹, Yavuz GEÇER¹, Zekeriya O. KARADUMAN¹, Cemal GÜLER¹, Mücahid O. YÜCEL¹

¹Department of Orthopaedics and Traumatology, School of Medicine, Düzce University, Düzce, Turkey.

ABSTRACT

Alendronate is the most popular bisphosphonate used to prevent osteoporotic fragility fractures in postmenopausal women. However, an increasing number of reports show a possible association between long-term treatment with bisphosphonates and the occurrence of characteristic femoral fragility fractures. This study reported a case of a bilateral femoral insufficiency fracture in a woman receiving long-term alendronate therapy. The woman suffered from bilateral femoral pain while having physical therapy in the hospital and sustained a right displaced and left nondisplaced femoral shaft fracture. The characteristics and natural course of this bilateral fracture was analyzed and the importance of being aware of the possible correlation between long-term alendronate therapy and insufficiency femoral fractures was emphasized.

Key words: Alendronate; femur fracture; osteoporosis

INTRODUCTION

Osteoporosis is a major public health problem with a significant economic burden on the society (1–4). The main clinical manifestations of osteoporosis are low-energy fractures of the proximal femur, vertebrae, and distal radius. Nearly two million osteoporotic fractures occur annually in the United States at an estimated cost of more than \$17 billion (5,6). Subtrochanteric and diaphyseal areas are considered to be the strongest parts of femur subjected to the highest stresses of the body (7). The strongest bone of the body, femur diaphysis, is an unusual site for fracture due to minor trauma, and raises significant suspicion regarding the pathogenesis of the fracture. In recent years, some cases of subtrochanteric and diaphyseal fractures due to minor trauma have been reported in association with long-term alendronate therapy (8–10). This pattern of fracture is defined as alendronate-induced atypical fracture. This study presents a case of bilateral femoral insufficiency fracture in a woman receiving long-term alendronate therapy.

CASE REPORT

While being treated in the Physical Therapy and Rehabilitation clinic for low back pain (lumbar degenerative disease and sciatica), a 65-year-old female fell in the hallway and suffered from right femoral midshaft pain and deformity. Radiography revealed a one-third distal femoral shaft fracture (Figure 1). Skeletal traction was applied from tuberositas tibia, and the patient was taken to the Orthopedics and Traumatology service for surgery. The patient's history showed that she had been using alendronate sodium for 5 years and she had pain for 3 months in both femurs. Radiographs taken a day before the fracture (Figure 2) revealed a nondisplaced bilateral femoral shaft fracture that was misdiagnosed by the physician. The patient was operated in the lateral decubitus position under a nonradiolucent operating table. Closed

Correspondence:

Yalçın Turhan

Department of Orthopaedics and Traumatology, School of Medicine, Düzce University, Düzce, Turkey.

e-mail: yturhan_2000@yahoo.com

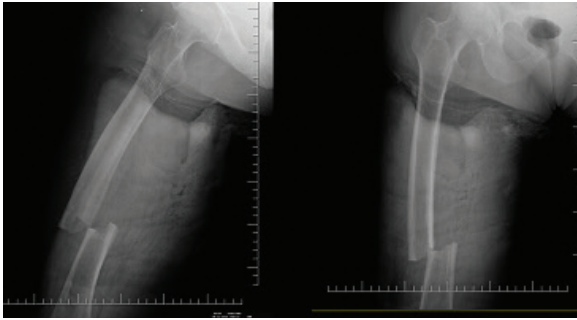


FIGURE 1: Right femur displaced fracture.

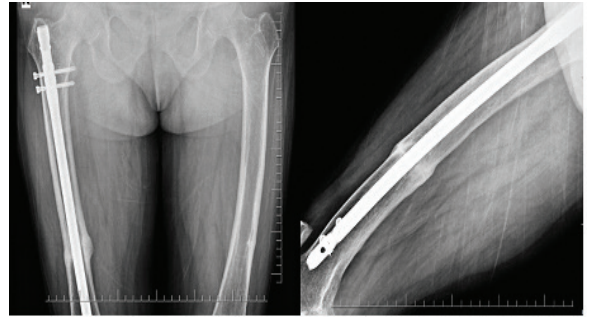


FIGURE 4: Radiographs of the right side at the 10th month post-operatively.

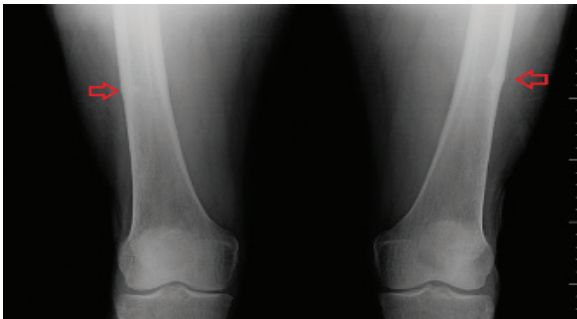


FIGURE 2: Bilateral nondisplaced femoral insufficiency fracture. Radiographs were taken 1 day before the right-sided displaced fracture.

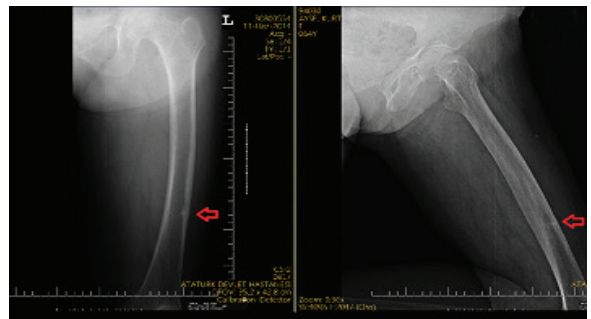


FIGURE 5: Radiographies taken at the 10th month of left femoral insufficiency fracture. (red arrows: callus formation).

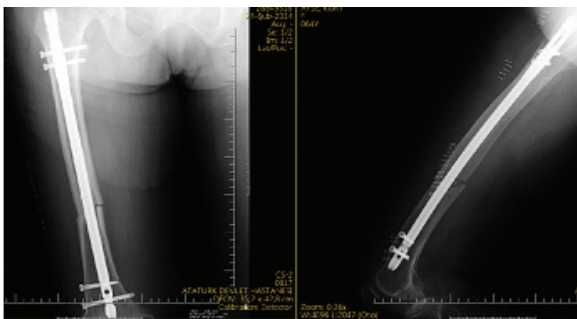


FIGURE 3: Early postoperative radiographs of the right side.

reduction of the right femur was performed, and it was internally fixed with trochanteric entry intramedullary nail (Tasarım Med, Medical Device Company A.S., Turkey) (Figure 3). The option of prophylactic nailing of the nondisplaced fracture of the left femur was offered, but the patient refused. Postoperative alendronate therapy was stopped, and strontium ranelate treatment was started because of the osteoporosis that was detected during the patient's bone mineral density (BMD) examination. Because of the left femoral insufficiency fracture, which the patient refused

to get operated, no weight-bearing exercises were allowed for 6 weeks. After 6 weeks, the patient was started on weight-bearing exercises with two crutches. So, both operated and nonoperated femoral fractures healed well. At the postoperative 10th month, both femurs totally healed (Figures 4 and 5). The outcomes of the fractures were radiographically and functionally perfect. The patient had no problem in both lower extremities.

DISCUSSION

The diagnosis of alendronate-induced atypical or insufficiency fracture is concluded by a high index of clinical suspicion and confirmed by the typical radiological finding. The clinical presentation includes long-term bisphosphonate (alendronate) therapy (usually more than 5 to 7 years) and spontaneous fracture or fracture after minor trauma that may be followed by prodromal pain for few weeks in a relatively young postmenopausal woman. Sometimes the fracture occurs on both sides at the same time or in a short span of time. A lot of fragility fractures associated

TABLE 1: Summary of the published data in the literature reporting the association between long-term bisphosphonate therapy and femoral fragility fractures.

Study	Odvin et al (9)	Schneider et al (13)	Goh et al (14)	Cheung et al (17)	Kwek et al (15)	Nevasar et al (16)	Wernecke et al (18)
Study design	Retrospective case series	Case report	Retrospective case series	Case report	Retrospective case series	Retrospective case series	Case report
Number of fractures	9	1	9	1	17	19	2
Type of fracture	Sacrum, ribs, ischium, pubis, femoral shaft	Femoral shaft	Subtrochanteric	Femoral shaft	Subtrochanteric	Subtrochanteric and femoral shaft	Subtrochanteric
Type of bisphosphonate	Alendronate	Alendronate	Alendronate	Alendronate	Alendronate	Alendronate	Zoledronic acid and pamidronate
Treatment duration (mean)	5.4 years	6.7 years	4.2 years	10 years	4.8 years	6.9 years	9 years
Other manifestations	N/A	Prodromal pain Cortical thickening on the contralateral side	Prodromal pain Cortical thickening on the contralateral side	Previous contralateral fracture	Prodromal pain Cortical thickening on the contralateral side	N/A	Prodromal pain Cortical thickening on the contralateral side
Fracture	Delayed union	Delayed union	N/A	Normal union	N/A	N/A	Delayed union

N/A: Not available.

with bisphosphonate treatment have been reported (Table 1) (9,13-18). The typical radiographic image can be in the form of a transverse or short oblique fracture in the subtrochanteric or diaphyseal area of the femur, medial spiking of distal fragment, lateral cortical thickening, and identical bilateral involvement (15-16). Pathogenesis is explained by the strong antiosteoclastic activity of alendronate, which produces a severely suppressed bone turnover (SSBT) status but does not inhibit mineralization, which in turn produces a hypermineralized brittle bone (9-11). Microcracks, which result from stress and strain on bone due to daily activities, develop relatively more in a hypermineralized bone, and due to SSBT, these microcracks do not heal. So, they accumulate and ultimately produce a stress zone (7). When this stress zone becomes weak enough to bear the body weight, the bone fractures spontaneously or with minor trauma. Alendronate, which is available since 1995, has a better patient compliance compared with other bisphosphonates available on the market

owing to its weekly doses and better gastrointestinal tolerability. It is reasonable to assume that a huge number of people have been taking this drug for decades, but the reported incidence of this clinical condition is less in comparison to the assumed consumption (8). The reason behind this may be the unawareness of some of the medical practitioners about this new clinical entity because of which many cases could not be diagnosed. The incidences of this fracture do not outweigh the benefits of bisphosphonates in reducing osteoporosis-induced fracture. Therefore, it is not justifiable to stop prescribing bisphosphonate for the treatment of osteoporosis. Even radiographic surveillance of all the patients who have been using bisphosphonates for a long time is not economically feasible.

As in the present case, some patients may refuse to get operated for the nondisplaced insufficiency fractures prophylactically. In this scenario, bisphosphonate treatment should be stopped, if needed other osteoporosis drugs (such as strontium ranelate)

should be started, and the patient should be advised to not bear weight on the affected side for at least 6 weeks. After 6 weeks, the patient's thigh pain on the nondisplaced side resolved and during the clinical follow-ups, no problems were reported by the patient.

CONCLUSION

Despite the great success achieved by using biphosphonates (mainly alendronate) in osteoporotic patients during the last two decades, a group of patients may develop femoral fragility fractures secondary to SSBT caused by prolonged usage. The number of these cases are still relatively small but will probably increase in the future owing to the large number of patients treated with these drugs. It is therefore important to reserve continuation of biphosphonate therapy for more than 5 years for selected cases. Furthermore, clinicians should be aware of the association between long-term biphosphonate therapy and femoral fragility fractures. In patients with early changes, such as prodromal hip/thigh pain and lateral cortical thickness, stopping biphosphonate therapy and prophylactic nailing should be considered. It may be better to stop these medications after the patient achieves normal BMD.

Conflict of interest statement: The authors declared no conflicts of interest with respect to the authorship and/or publication of this article.

REFERENCES

- Lewinnek GE, Kelsey J, White AA, Kreiger NJ. The significance and a comparative analysis of the epidemiology of hip fractures. *Clin Orthop*. 1980; 152:35–43.
- Sernbo I, Johnell O. Consequences of a hip fracture: A prospective study over 1 year. *Osteoporos Int* 1993; 3(3):148–153.
- Johnell O, Kanis J. Epidemiology of osteoporotic fractures. *Osteoporos Int* 2005;16(2):3–7.
- Carlos F, Clark P, Maciel H, Tamayo JA. Direct costs of osteoporosis and hip fracture: An analysis for the Mexican Social Insurance Health Care System. *Salud Publica Mex*. 2009; 51(1):108–113.
- Johnell O, Kanis JA. An estimate of the worldwide prevalence and disability associated with osteoporotic fractures. *Osteoporos Int* 2006; 17(12):1726–1733.
- Burge R, Dawson-Hughes B, Solomon DH, Wong JB, King A, Tosteson A. Incidence and economic burden of osteoporosis-related fractures in the United States, 2005–2025. *J Bone Miner Res* 2007;22(3):465–475.
- Sims SH. Subtrochanteric femur fractures. *Orthop Clin North Am* 2002; 33(1): 113–126.
- Shane E, Burr D, Ebeling PR, Abrahamsen B, Adler RA, Brown TD et al. Atypical Subtrochanteric and diaphyseal femoral fractures: Report of a task force of the American Society for Bone and Mineral Research. *Journal of Bone and Mineral Research* 2010; 25(11): 2267–2294.
- Odvina CV, Zerwek JE, Rao DS, Maalouf N, Gothschalk FA, Pak CYC. Severely suppressed bone turnover: a potential complication of alendronate therapy. *J Clin Endocrinol Metab* 2005; 90(3): 1294–301.
- Bovin G, Meunier PJ. Effects of bisphosphonates on matrix mineralization. *J Musculoskeletal Neuronal Interact*. 2002; 2(6): 538–43.
- Curry JD. Effects of differences in mineralization on the mechanical properties of bone. *Philos Trans R Soc Lond B Biol Sci* 1984; 304(1121): 509–518.
- Stephan JJ, Burr DB, Pavo I, Sipos A, Micoloska D, Li J et al. Low bone mineral density is associated with bone microdamage accumulation in postmenopausal women with osteoporosis. *Bone* 2007; 41(3): 378–385.
- Schneider JP. Should bisphosphonates be continued indefinitely? An unusual fracture in a healthy woman on longterm alendronate. *Geriatrics* 2006; 61(1):31–33.
- Goh SK, Yang KY, Koh JSB, Wong MK, Chua SY, Chua DTC et al. Subtrochanteric insufficiency fractures in patients on alendronate therapy: A caution. *J Bone Joint Surg Br* 2007; 89(3):349–353.
- Kwek EB, Goh SK, Koh JSB, Png MA, Howe TS. An emerging pattern of subtrochanteric stress fractures: A long-term complication of alendronate therapy? *Injury* 2008; 39(2):224–231.
- Neviaser AS, Lane JM, Lenart BA, Edobor-Osula F, Lorch DG. Low-energy femoral shaft fractures associated with alendronate use. *J Orthop Trauma* 2008; 22(5):346–350.
- Cheung RK, Leung KK, Lee KC, Chow TC. Sequential non-traumatic femoral shaft fractures in a patient on long-term alendronate. *Hong Kong Med J* 2007; 13(6):485–489.
- Wernecke G, Namduri S, Dicarolo EF, Schneider R, Lane J. Case report of spontaneous, nonspinal fractures in a multiple myeloma patient on long-term pamidronate and zoledronic acid. *HSS J* 2008; 4(2):123–127.