

BIOCHEMICAL STUDY ON THE EFFICACY OF MALAYSIAN HONEY ON INFLICTED WOUNDS: AN ANIMAL MODEL

A. M. ALJADY*

M. Y. KAMARUDDIN*

A. M. JAMAL**

M. Y. MOHD. YASSIM***

SUMMARY: The efficacy of Malaysian honey on the healing of wounds in Sprague-Dawley rats was investigated on the basis of biophysical and biochemical changes. Equidimensional full-thickness excision wounds were created on the back of each animal and treated either by topical application or by a combination of topical and oral administration of honey. Control animals received only saline. Development of wound healing was evaluated by measuring the rates of wound contraction and epithelialization. Quantitative assays were performed to determine the amounts of uronic acid, hexosamine, DNA, and collagen content of the granulating tissues. The serum albumin level was also measured. The results obtained showed that honey accelerates wound healing by influencing cell division and proliferation, collagen synthesis and maturation, wound contraction and epithelialization. All the parameters measured showed remarkable consistency with the wound healing property of honey. Honey also improved the nutritional state of the animal when given orally.

Key words: Honey, wound healing.

INTRODUCTION

The complex cascade of cellular and biochemical events that occurs after injury determines the successful outcome of wound repair. The process is comprised of three phases namely inflammation, proliferation and maturation. Fibroblasts are the primary synthetic element in the repair process and are responsible for production of large quantities of collagen. They are also responsible for the production of other matrix constituents including hyaluronic acid, fibronectin and glycosaminoglycan (1).

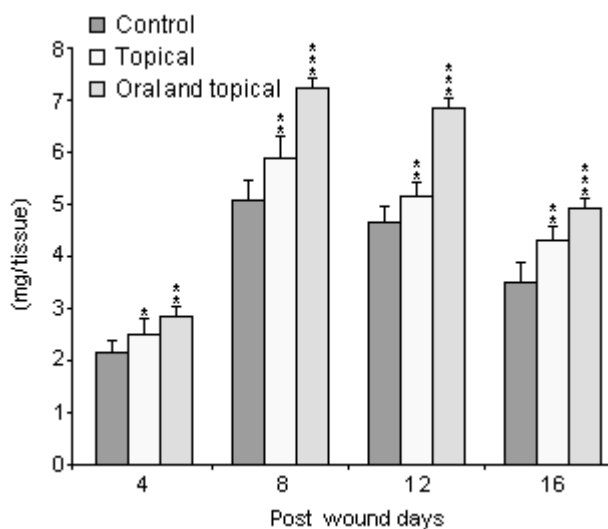
Despite recent advances in antimicrobial chemotherapy and wound management, several types of wounds and ulcers still prove recalcitrant to treatment. Thus, wound healing continues to be one of the major public health problems in the world and wound management still remains a matter of research. In recent years, considerable interest in the use of alternative therapies and natural remedy is attracting the attention of many researchers. Naturally occurring substances such as honey and *aloe vera* have been found useful in wound dressing; however, honey is one of the oldest and the most enduring-material to be used in the wound management (2). In the modern medicine, many practitioners have noticed the effectiveness of honey in

*From Department of Biochemistry,

**From Department of Orthopedic Surgery,

***From Department of Medical Microbiology, Faculty of Medicine, University Malaya, Malaysia.

Figure 1: DNA content (mg/g wet weight) of the granulation tissue taken from honey treated and untreated rats (mean±SD); n=6. Statistically significant data are given as * p<0.05, ** p<0.01, and *** p<0.001.



the healing of various types of wounds, burns and ulcers (3,4). Much of the effectiveness of honey in many of its medicinal uses is attributed to its antibacterial activity. Honey has been shown to be effective against bacterial strains including those that have become resistant to synthetic antibiotics (5).

Scientists in various parts of the world have found that various types of honey differ substantially in their activity, depending on the nectar source (6). Since the source of plant nectar as well as climate affect the composition and hence properties of honey, the present study was designed to investigate the wound healing property of a chosen Malaysian honey. In order to obtain biochemical and biophysical parameters, animals were used in this controlled study.

MATERIALS AND METHODS

Honey samples

A local unpasteurised monofloral *Apis mellifera* honey was used. Its floral source is (Gelam) (*Melaleuca* spp) trees. It was sterilized by gamma-irradiation (25 kGy) and kept at laboratory temperature (20°C), away from direct light before use.

Animals

Male Sprague-Dawley rats weighing between 220 and 280 g were used in this study. These animals have been used extensively for wound healing studies (7). Each animal was individually caged under standard 12/12 light/dark cycle, and fed a complete pelleted laboratory chow and had access to tap water *ad libitum*.

Wounding procedure

The animals were anaesthetized with intraperitoneal injection of Sagatal (Pentobarbitone sodium 60 mg/ml) at 0.44 ml per kg body weight. A surgical wound in the form of a skin excision was made by cutting a 4 cm² (2 cm x 2 cm) piece of skin from the dorsal area just behind the shoulders with clean conditions. All wounds were of full-thickness extending down to the subcutaneous tissue.

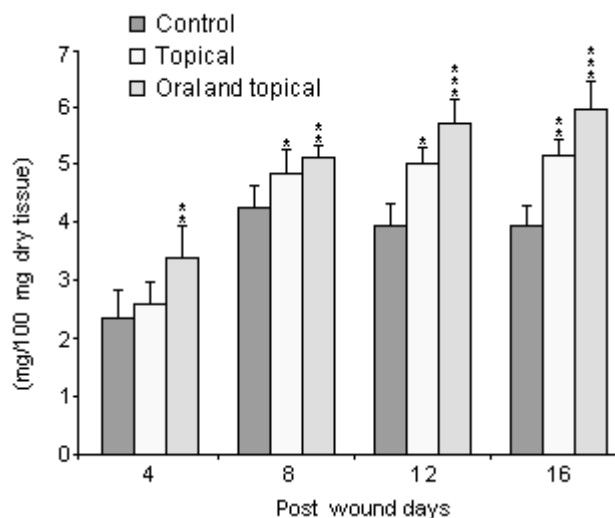
Grouping and mode of treatment

After wound creation, the animals were divided into three groups with 24 rats per group. Group A was treated with topical saline (control), whilst groups B and C were treated topically with honey and a combination of topical and oral dose of honey, respectively. Treatment started 24 hours after wound creation. Wounds were air exposed and treated once a day.

Sampling

For each group six animals were sacrificed at the 4th, 8th, 12th and 16th days after wound creation. Blood samples were collected from each animal and the serum instantly separated. The entire granulating tissues were carefully removed from each animal and stored along with the serum samples at -70°C until analysis. All the samples were properly labeled before storage and the measurements were done at random depending on numbers and not on treatment group, to overcome experimental bias.

Figure 2: Collagen content (mg hydroxy proline/100 mg dry tissue x 7.46) of the granulation tissue taken from honey treated and untreated rats (mean±SD); n=6. Statistically significant data are given as * p<0.05, ** p<0.01, and *** p<0.001.



Biochemical analysis

The granulation tissue was removed, (great care was taken to include only granulating tissue in the assay), weighed, and then analyzed for the following: Uronic acid was estimated by carbazole method (8). DNA was first extracted in trichloroacetic acid (TCA) and estimated by the diphenylamine method (9). Collagen was extracted according to the method described by Smith, *et al.* (10) and determined by the method of Woessner (11). Hexosamines were extracted and hydrolyzed according to the method described by Spiro (12) and determined according to Davidson (13). Serum albumin was measured using Sigma diagnostic kit (Cat. no. 631).

Assessment of wound healing

Measurements of the healed wound area, as well as that unhealed was carried out by tracing the wound areas onto a transparent, flexible, plastic grid. Areas were measured by square counting procedure (14). The number of squares (0.01 cm²) that appear completely (N_c) and partially (N_p) inside the tracing were counted and area was determined using the following formula: $A_{c+p} = (N_c + 0.4 \times N_p) \times 0.01$. Wound contraction and epithelialization were calculated as described by Kaufman *et al.* (15).

Statistical analysis

Data significance was determined by employing the unpaired student's t-test, using the SPSS statistical software. A value of p<0.05 was taken as statistically significant.

RESULTS

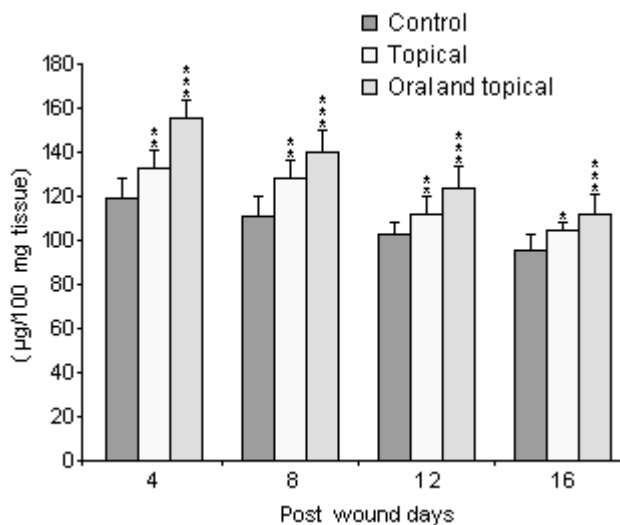
DNA content

Effects of honey treatment on DNA content of the granulation tissue are shown in Figure 1. On day 4, there was a significant increase (p<0.05) in DNA content of the topical treated group. However, this difference turned to high significant (p<0.01) on days 8, 12 and 16 as compared to the control group. The combined treated animals showed a highly significant (p<0.01) difference on post wound day 4 and very high significantly (p<0.001) difference on days 8, 12 and 16 as compared to the control group. In all of the groups the highest level of DNA was reached at day 8 and among the treated groups the combined treatment showed the highest levels followed by the topical one.

Collagen content

The effect of honey on collagen content of the granulation tissue is shown in Figure 2. Topical application and the combination of topical and oral administration of honey increased collagen content significantly in comparison to the control group. On day 4, there was no significant (p>0.05) difference between the topical treated (group B) and the control groups (group A). However, the differences were significant (p<0.05) on days 8 and 12 and highly significant (p<0.01) on day 16. On the other hand, the group that received combined treatment (group

Figure 3: Uronic acid content ($\mu\text{g}/100 \text{ mg tissue}$) of the granulation tissue taken from honey treated and untreated rats (mean \pm SD); n=6. Statistically significant data are given as * $p<0.05$, ** $p<0.01$, and *** $p<0.001$.



C) showed high significant difference ($p<0.01$) on days 4, 8 and very high significant difference ($p<0.001$) on days 12 and 16 as compared to the control group.

Uronic acid content

The uronic acid content of the granulation tissue of all the groups is represented in Figure 3. Topically treated group had a significantly higher ($p<0.01$) amount of uronic acid at days 4, 8, 12 and ($p<0.05$) at day 16 as

compared to the control. It was also shown that the combined honey treatment creates a very high significant ($p<0.001$) increase in uronic acid content as compared to the control. In all the groups the highest levels were recorded on day 4, subsequently followed with gradual declinations. The pattern was similar and did not differ significantly from each group. However both of the honey treated groups still had significantly higher levels than the control in all the treatment period.

Figure 4: Hexosamine content ($\text{mg}/100 \text{ mg dry tissue}$) of the granulation tissue taken from honey treated and untreated rats (mean \pm SD); n=6. Statistically significant data are given as * $p<0.05$, ** $p<0.01$, and *** $p<0.001$.

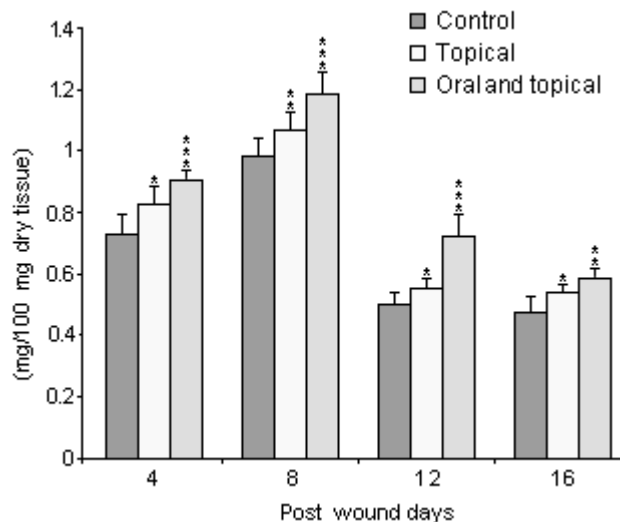
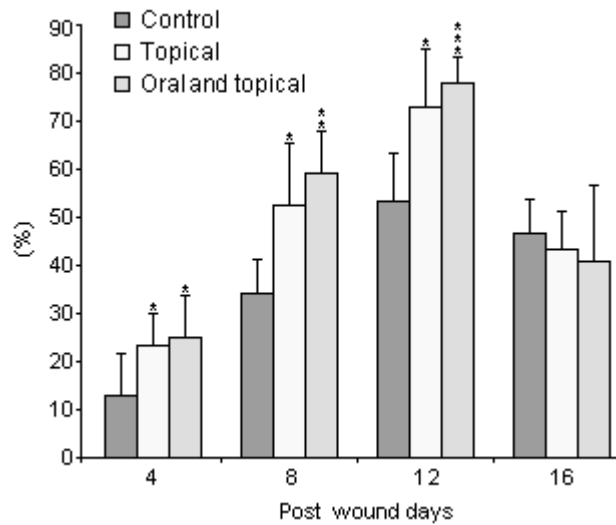


Figure 5: Rate of wound contraction (%) in honey treated rats on different post wound days (mean±SD); n=6. Statistically significant data are given as * p<0.05, ** p<0.01, and *** p<0.001.



Hexosamine content

Figure 4 shows the hexosamine content of the granulation tissue. The topically treated group demonstrated significantly higher amount of hexosamine ($p<0.05$) on days 4, 12 and 16. However, the difference was highly significant ($p<0.01$) on day 8 post wound. Animals that received combined treatment demonstrated significantly greater level of hexosamine ($p<0.001$) on days 4, 8, 12 and ($p<0.01$) on day 16 as compared to the control. The hexosamine levels increased steadily to maximum values on day 8 and then decreased afterward for all groups.

Rate of wound contraction

The mean percent of the contraction rate of topically treated animals was significantly higher ($p<0.05$) than the control on all of the post wound days, except on day 16 where it became slightly lower than the control (Figure 5). On the other hand, the combined treated group showed significantly higher rates on 4, 8 and 12 post wound days ($p<0.05$, 0.01 and 0.001 respectively), whereas on the post wound day 16 the contraction rate was non significantly lower ($p>0.05$) than the control. All the groups showed highest mean rates of contraction on post wound day 12.

Rate of epithelialization

An accurate measurement of epithelialization was not possible before day 12. Figure 6 represents the mean percent of the epithelialization rate for the different

groups. The topically treated group showed a highly significant ($p<0.01$) higher rate of epithelialization than that of the control. Moreover, the combined treated group also showed a highly significant rate more than the control ($p<0.001$, 0.01 on days 12 and 16 respectively).

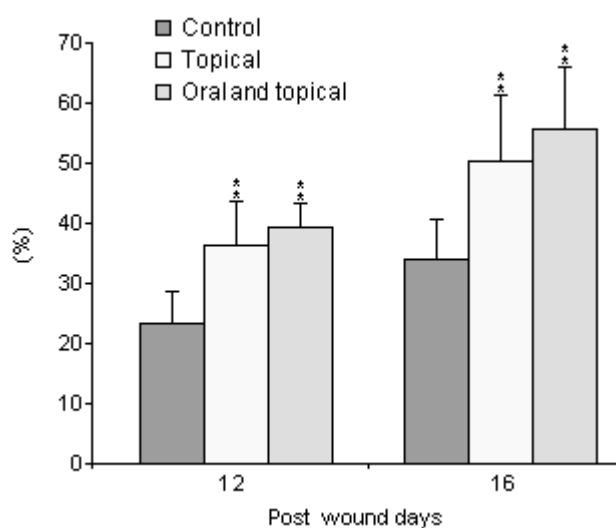
Albumin levels

Serum albumin levels in different groups are represented in Figure 7. There was no significant difference observed between the different groups on day 4. However, both of the treated groups showed a significantly ($p<0.05$) higher levels than the control on day 8. After day 8 albumin level of the combined treated animals started to show a gradual increase so that the difference was highly significant ($p<0.01$, 0.001 on days 12 and 16 respectively) when compared to the control. On the other hand, the topically treated animals showed slight decrease of their levels toward day 12, after which their levels started to increase again. By comparison to the control, there was no significant difference ($p>0.05$) observed in the topically treated group, whereas the difference turned significantly higher ($p<0.05$) only on day 16.

DISCUSSION

A number of quantitative methods for measuring the repair of a surgical excision can be found in the literature, but nearly all these methods rely on parameters of dermal healing e.g. gain in tensile strength, hydroxypro-

Figure 6: Rate of wound epithelialization (%) in honey treated and untreated rats on different post wound days. (mean±SD); n=6. Statistically significant data are given as * p<0.05, ** p<0.01, and *** p<0.001.



line content to reflect collagen synthesis, DNA content to reflect fibroblasia and others. Granulating tissue consists of a combination of cellular elements, including fibroblasts and inflammatory cells, along with new capillaries embedded in a loose extra cellular matrix of collagen, fibronectin and hyaluronic acid. In the present study wound healing was evaluated by quantitative measurement of collagen, DNA, hexosamine and uronic acid content of the granulation tissues, in addition to the measurements of wound contraction and epithelialization. The nutritional state of the animals was also examined by measurement of serum albumin.

The efficiency of the topical application of honey on wounds or burns has been reported by many researchers (3,4,17). However some of them showed that systemic administration of honey (16,17) especially the intraperitoneal way (17) yielded better results than the topical treatment. Intraperitoneal treatment with honey may not be convenient for the daily treatment of patients. Moreover, the effectiveness of the oral or intraperitoneal treatment against the infected wounds is still a matter of debate. Accordingly it was decided to investigate the influence of a combination of oral and topical treatment on wound healing using Malaysian honey, which has not been assessed before.

A number of pilot trials were carried out, we found that

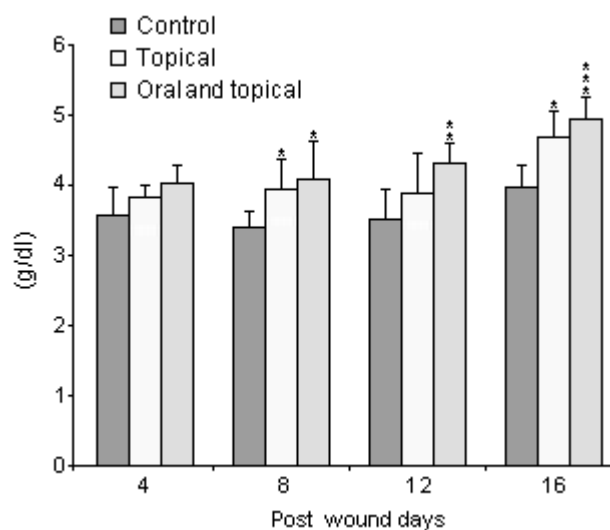
the best results could be obtained by giving 1.5-2.0 ml orally plus 0.1-0.15 ml/cm² topically or by topical application of 0.2-0.25 ml/cm². Higher doses had caused an overgrowth and dehydration of the granulation tissue whereas lower doses resulted in less or no response.

Honey treatment significantly increased cells proliferation in the newly formed granulation tissues as reflected by DNA levels, which is in agreement with the results obtained by Suguna, *et al.* (17). DNA level which reflect fibroblasia showed maximum levels on the 8th day post wound. An early and rapid fibroblastic and angioblastic activities were observed in honey-applied wounds (18). Honey has been shown to stimulate fibroblasia in time and dose dependent manner (19). Honey contains sugars, amino acids, minerals and vitamins, which were shown to enhance cell proliferation and hydroxyproline synthesis in the newly formed granulation tissues (20). It also contains hydrogen peroxide, low levels of which was found to stimulate fibroblast proliferation (21) and angiogenesis (22).

As reflected by hydroxyproline level, collagen content of the granulation tissue increased significantly in honey treated animals as compared to the controls. Since fibroblasts are responsible for the synthesis of collagen in the newly formed granulation tissue, one would expect that any increase in fibroblasts proliferation would more or less results in an increase in collagen deposition. On the other hand, honey contains high level of glycine, methionine, arginine, and proline which play definite roles in collagen formation and deposition (18).

Glycosaminoglycans are made up of repeating disaccharides containing uronic acid and hexosamine. They are the first components of the extra cellular matrix to be synthesized during wound healing and form the template for collagen and elastin deposition. The higher levels of uronic acid and hexosamine in honey treated animals reflect an enhanced synthesis of glycosaminoglycans. The highest level of uronic acid was observed on day 4, which is in agreement with an earlier observation (23). The highest level of hexosamine was observed on day 8, which is later than the observations of Sugana *et al.* (17) and Chithra, *et al.* (23) who found a highest rise in hexosamine in as early as the 4th day. Since fibroblasts are responsible for the synthesis of glycosaminoglycans, we believe that their synthesis does not occur until fibroblasia is established, whereas previous findings might be due to the entry of serum glycoprotein to the wounded area (24).

Figure 7: Serum albumin level (g/dl) of honey treated and untreated rats (mean \pm SD); n=6. Statistically significant data are given as *p<0.05, ** p<0.01, and *** p<0.001.



Contraction was the predominant process of the present wound model. The rate of contraction was greatest in the combinely treated animals followed by the topically treated group as compared with the control. All the groups showed maximum rates of contraction at the period between 8 and 12 post wound days. Wound contraction occurs as a result of an interaction between fibroblast locomotion and collagen reorganization; honey seems to enhance this process by stimulating fibroblasia and collagen deposition and by providing the energy needed for this contractile activity. Similarly, the rate of epithelialization was higher in the combinely treated group followed by the topical group when compared to the control, which is in agreement with the results obtained by Gupta, *et al.* (18). During this study we observed that the scab formed by the honey treated animals was thinner and not dry as that of the control group. This observation could be attributed to the moist environment created by honey, due to its viscosity, and it promotes rapid epithelialization (3).

Many surgeons believe that nutritional state is the most important systemic factor affecting wound healing (24). Honey treatment, especially the combined form, significantly improved the nutritional state of the treated animals as reflected by enhancement of serum albumin level. In addition to sugars, which are important source of energy, honey contains amino acids, a number of vitamin B's and C, and minerals such as iron, copper and

zinc (25). These elements are cofactors for some of the enzymes involved in tissue repair such as proline hydroxylase, DNA-polymerase and lysyl oxidase (26). These nutritional elements present in honey seems to be absorbed more readily through the intestine than through the cells of wounds, and this explains the superiority of combined treatment over the topical treatment alone.

CONCLUSION

The present study illustrates the wound healing property of Malaysian 'Gelang' honey. Honey is shown to stimulate fibroblast function, enhance synthesis of glycosaminoglycans and deposition of collagen. It also increases the rate of wound contraction and epithelialization and improves the nutritional state of the animal under study when given orally. In addition, this study also clearly demonstrates that the combined honey treatment (topical and oral) offers a distinct advantage to wound healing, and as such, may be a useful adjuvant in wound management.

ACKNOWLEDGMENT

We are grateful to the University Malaya for the research grant (F0051/2000B) and Malaysian R and D under IRPA grant: 06-02-03-0762. We would like to thank Mdm. Lim Saw Kim, Mr. N. Rasanayagam and En. Rosni Sarjan for their technical assistance.

REFERENCES

1. Kurkinen M, Vahert A, Roberts P, Stenmam S : *Sequential appearance of fibronectin and collagen in experimental granulation tissue. Lab Invest, 43:47-51, 1980.*
2. Thomas S : *Polysaccharide pastes, Granules and Beads. In: wound management and dressings. First Ed, The Pharmaceutical Press, London, p 62, 1990.*
3. Subrahmanyam M : *A prospective randomized clinical and histological study of superficial burn wound healing with honey and silver sulfadiazine. Burns, 24:157-161, 1998.*
4. Vardi A, Barzila Z, Linder N, et al : *Local application of honey on the treatment of neonatal postoperative wound infection. Acta Paediatr, 87:429-432, 1998.*
5. Molan P, Brett M : *Honey has potential as a dressing for wounds infected with MRSA. The second Australian wound management association conference. Brisbane, Australia, 1998.*
6. Molan PC : *The antibacterial activity of honey. 2. Variations in the potency of the antibacterial activity. Bee World, 73:59-76, 1992.*
7. Nolan J, Jenkins RA, Kurihara K, et al : *The acute effects of cigarette smoke exposure on experimental skin flaps. Plastic and Reconstructive Surgery, 75:544-551, 1985.*
8. Bitter T, Muir HM : *A modified uronic acid carbazole reaction. Anal Biochem, 4:330-334, 1962.*
9. Burton K : *A study of the conditions and mechanism of the diphenylamine reaction for the colorimetric estimation of deoxyribonucleic acid. Biochem J, 62:315-323, 1956.*
10. Smith RL, Gilkerson E, Kohatsu N, et al : *Quantitative microanalysis of synovial fluid and articular cartilage glycosaminoglycans. Anal Biochem, 103:191-200, 1980.*
11. Woessner JR : *The determination of hydroxy proline in tissue and protein samples containing small proportions of this amino acid. Arch Biochem Biophys, 93:440-447, 1961.*
12. Spiro RG: *Study of the carbohydrates of glycoproteins. Methods Enzymology, 8:3-43, 1972.*
13. Davidson EA : *In methods in enzymology, VIII, Academic Press, New York, pp 52-60, 1966.*
14. Schubert V : *Measuring the area of chronic ulcers for consistent documentation in clinical practice. Wounds, 9:153-159, 1997.*
15. Kaufman T, Levin M, Hurwitz DJ : *The effect of topical hyperalimentation on wound healing rate and granulation tissue formation of experimental deep second degree burns in guinea pigs. Burns, 10:252-256, 1984.*
16. El-Banby M, Kandil A, Abou-Sehly G, et al : *Healing effect of floral honey and honey from sugar-fed bees on surgical wounds (animal model). Fourth international conference on apiculture in tropical climates. Cairo, Egypt, 1989.*
17. Suguna I, Chandrakasan G, Ramamoorthy U, Joseph KT : *Influence of honey on biochemical and biophysical parameters of wounds in rats. J Clin Biochem Nutr, 14:91-99, 1993.*
18. Gupta SK, Singh H, Varshiney AC, Prakash P : *Therapeutic efficacy of honey in infected wounds in buffaloes. Ind J Anim Sci, 62:521-523, 1992.*
19. Aljadi AM, Kamaruddin MY : 2001 (unpublished observations).
20. Niinikoski J, Kivisaari J, Viljanto J : *Local hyperalimentation of experimental granulation tissue. Acta Chir Scand, 143:201, 1977.*
21. Schmidt RJ, Chung LY, Andrews AM, Turner TD : *Hydrogen peroxide is a murine (L 929) fibroblast cell proliferation at micro- and nanomolar concentrations. In: Second European conference in advances in wound management. Proc Int Conf Center Harrogate, 1992.*
22. Tur E, Bolton L, Constantine BE : *Topical hydrogen peroxide treatment of ischemic ulcers in the guinea-pig: Blood recruitment in multiple skin sites. J Am Acad Derm, 33:217-221, 1995.*
23. Chithra P, Sajithlal GB, Chandrakasan G : *Influence of aloe vera on the glycosaminoglycans in the matrix of healing dermal wound rats. J Ethnopharmac, 59:179-186, 1998.*
24. Irvin TT : *The healing wound In: wound healing principles and practice. First Ed, Chapman and Hall, London, pp 2-15, 1981.*
25. White JW : *Composition of honey. In: Honey: A comprehensive survey. William Heinemann in cooperation with IBRA: London, UK, pp 157-206, 1975.*
26. Mazzotta, Mary Y : *Nutrition and wound healing. J Amr Pediatric Med Assoc, 84:456-462, 1994.*

Correspondence:

M. Y. Kamaruddin

Department of Biochemistry,

Faculty of Medicine,

University of Malaya,

50603 Kuala Lumpur,

MALAYSIA.

e-mails: kamarudd@ummc.edu.my

kamaruddin77@um.edu.my