

# Utility of Cross Suture Technique for Stabilize the Intraocular Lens Against Vitreous Pressure During Penetrating Re-Keratoplasty: Case Report

 **Hacı Uğur Çelik**

Dunya Eye Hospitals Group, İstanbul, Türkiye

## Abstract

We reported a simple, effective, and exceptional blocking technique to prevent possible complications during penetrating re-keratoplasty. A 54-year-old female patient was admitted to the clinic with the complaint of opening corneal surgical wound. After careful corneal dissection from the graft host wound dehiscence, the intraocular lens implantation was tried. However, the vitreous pressure blocked the intraocular lens placement. We decided to do cross sutures to prevent both vitreous pressure and intraocular lens stabilization to finish the corneal transplantation. After the transplantation, the sutures were removed easily and the surgery completed successfully.

Keywords: Cornea transplantation; penetrating keratoplasty; vitreous pressure.

**G**lobe rupture is one of the most important surgical emergencies in ophthalmology practice. The thinnest or weakest point of the cornea tends to be ruptured in traumas. Corneal surgeries increase the risk of globe rupture. Keratoplasty surgeries' post-operative period has the highest risk on this surgery spectrum. The graft host junction is the main weakest part of the keratoplasty patients because of the factors such as inappropriate wound apposition, prolonged steroid usage, and suture complications<sup>[1-3]</sup>.

Ocular complications related to wound dehiscence are highly correlated with the time of the patient hospitalization. Cataract formation, expulsive hemorrhage, endophthalmitis, vitreous incarceration, and retinal detachment are the main complications in this type of globe rupture<sup>[4,5]</sup>.

We reported a simple, effective, and exceptional blocking

technique, during intraocular lens placement of an open sky procedure, to prevent possible complication after a non-traumatic keratoplasty wound dehiscence following heavy coughing attack.

## Surgical Technique

A 57-year-old female patient, whose corneal sutures were removed 1 month ago after a successful 1-year-old corneal transplantation, applied to hospital with the wound dehiscence after a heavy coughing attack (Fig. 1). The corneal scar dehiscence and the cataract formation were examined during the first examination. The patient was pre-medicated and prepared surgery for the re-keratoplasty, cataract removal, and IOL implantation with her own graft (triple procedure). Hypotensive general anesthesia was planned and applied.

**Correspondence (İletişim):** Hacı Uğur Çelik, M.D. Dünya Göz Hastaneler Grubu, İstanbul, Türkiye

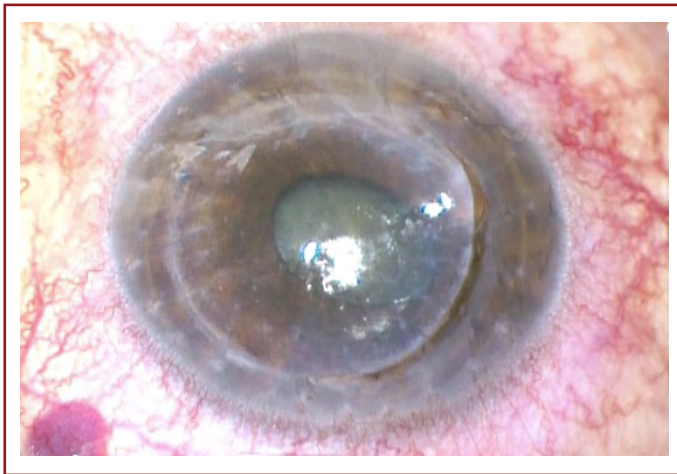**Phone (Telefon):** +90 535 965 17 40 **E-mail (E-posta):** h.ugurcelik@gmail.com

**Submitted Date (Başvuru Tarihi):** 19.05.2020 **Accepted Date (Kabul Tarihi):** 14.08.2020

Copyright 2022 Haydarpaşa Numune Medical Journal

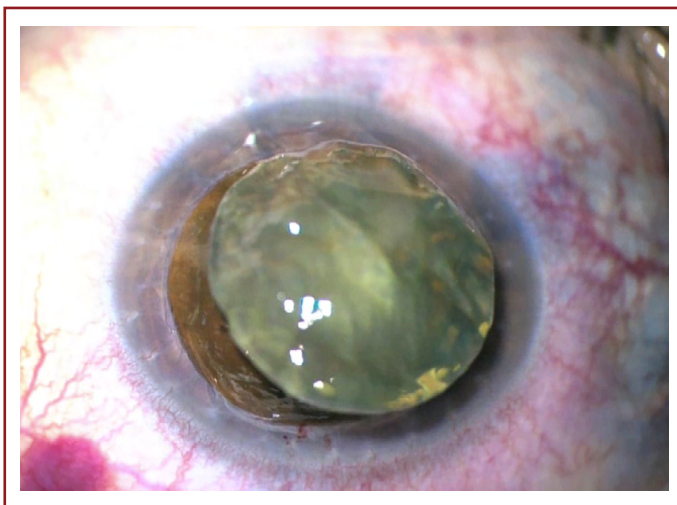
**OPEN ACCESS** This is an open access article under the CC BY-NC license (<http://creativecommons.org/licenses/by-nc/4.0/>).



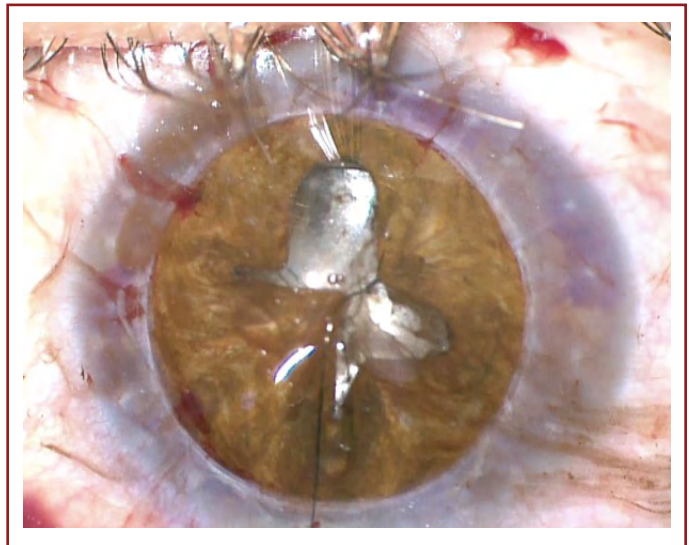


**Figure 1.** Pre-operative appearance.

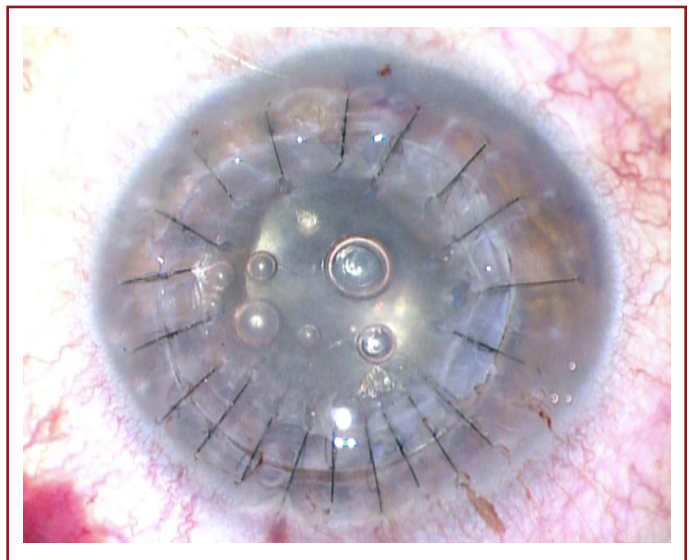
The patient's own graft was carefully dissected and the lens were removed with "open-sky" surgery technique. High vitreous pressure was observed during the capsulorhexis; however, we did not change our plan for IOL implantation (Fig. 2). After cortex removal, three pieces IOL was tried to implant; however, the vitreous was started to make pressure to the anterior structures. After some attempts, we decided to make a pupil closure through two cross sutures. We considered to protect and preserve the iris sphincter function, and decided to points between mid-peripheral irises for sutures. We enabled sutures easily removable for the end of the surgery (Fig. 3). With the help of cross sutures, we could finish the procedure. At the end of the surgery, we carefully cut the sutures and make the anterior chamber formation perfectly (Fig. 4). The post-operative 1 month uncorrected visual acuity was 0.3 on Snellen chart, cornea was clear and intraocular lens were observed in sulcus position (Fig. 5).



**Figure 2.** Capsular tear and spontaneous lens extraction.



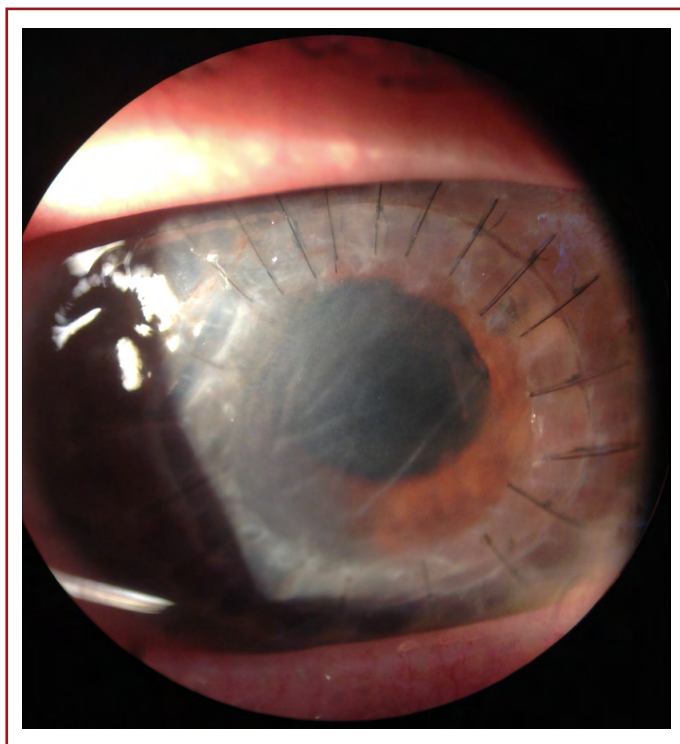
**Figure 3.** Cross sutures over pupil area.



**Figure 4.** Post-operative appearance.

## DISCUSSION

Wound dehiscence after keratoplasty is always a considerable complication of the surgery. It could be seen couple of months to years after the surgery. The causes of the dehiscence may be in variety of traumas like fist punch, finger strike, fall, blunt trauma, sport injury, car accident, and struck by a door<sup>[6]</sup>. There was a heavy cough attack history on our case. We thought that increased Valsalva maneuver pressure was the cause of this dehiscence. Fiorentzis et al.<sup>[7]</sup> reported a dehiscence of a continuous positive airway pressure mask during sleep after penetrating keratoplasty; however, they found the cause as the direct mechanical problem of the mask design. Our case is also can be cate-



**Figure 5.** Post-operative 1<sup>st</sup> month appearance.

gorized as one of the unusual cause of corneal wound dehiscence after keratoplasty.

The penetrating keratoplasty with triple procedure (extra capsular lens extraction, intraocular lens implantation, and keratoplasty at the same session) has advantages and disadvantages according to sequential procedure (phacoemulsification after keratoplasty). Despite the endothelial cell preservation and the short patient hospitalization are the advantages in triple procedure, more precise intraocular lens power estimation is better in sequential procedure<sup>[8]</sup>. In our case, there were some emergency statements for triple procedure, first, it was a globe rupture and needed to be repaired as soon as possible, second, it was a previously transplanted corneal keratoplasty patient and the graft was looking alive so we wanted to use it again, third, the cataract formation developed after the trauma was needed to be removed. We planned the surgery for both giving a chance to the graft with minimum trauma and get the possible visual acuity rehabilitation by the help of lens removal. Technically, we did both auto and re-keratoplasty with triple procedure together in this patient.

Continuous curvilinear capsulorhexis could be considered as the most difficult step in triple procedure. Capsular tear is the main complication in this step. The possible increased intraocular pressure causes this complication. The tight blepharostat, narrow interpalpebral distance, and in-

creased choroidal pressure with high blood pressure may cause this complication<sup>[9]</sup>. In our case, after capsular tear and spontaneous lens extraction, we directly loose the blepharostat first; however, the intraocular pressure did not show any change, we checked the blood pressure and ordered mannitol to decrease vascular pressure as much as possible. However, despite to all attempts, the vitreous pressure did not decrease and the intraocular lens did not stay on the position that wanted to be placed.

Barrier sutures are using on the selected cases in retina surgeries to create a barrier between anterior and posterior chamber in silicon filled aphakic cases. The mechanism of the barrier is only depends on through enhancing the high silicone oil-aqueous humor interface tension. This surface tension allows the silicone oil to stay in a single spheroidal shape<sup>[10,11]</sup>. This is a physical principle based effect of the sutures. In our cases, we used direct physical effect of the sutures with iris tissue to resist the effect of vitreous pressure during the corneal suturing. It provided us both enough time to complete the surgery and protect the endothelium of the graft cornea.

Our technique addresses the potential benefit of a simple, effective, and exceptional barrier suture during a triple procedure. Our case is also the only reported successful auto-re-keratoplasty case in the literature with spontaneous corneal dehiscence nature related with increased Valsalva maneuver pressure.

**Informed Consent:** Approval was obtained from the patients.

**Peer-review:** Externally peer-reviewed.

**Conflict of Interest:** None declared.

**Financial Disclosure:** The authors declared that this study received no financial support.

## References

1. Pettinelli DJ, Starr CE, Stark WJ. Late traumatic corneal wound dehiscence after penetrating keratoplasty. *Arch Ophthalmol* 2005;123:853–6. [\[CrossRef\]](#)
2. Oshry T, Lifhitz T. Traumatic wound dehiscence after corneal graft. *Ophthalmic Surg Lasers* 2001;32:470–3. [\[CrossRef\]](#)
3. Jafarinasab MR, Feizi S, Esfandiari H, Kheiri B, Feizi M. Traumatic wound dehiscence following corneal transplantation. *J Ophthalmic Vis Res* 2012;7:214–8.
4. Tseng SH, Lin SC, Chen FK. Traumatic wound dehiscence after penetrating keratoplasty: Clinical features and outcome in 21 cases. *Cornea* 1999;18:553–8. [\[CrossRef\]](#)
5. Viestenz A, Schrader W, Küchle M, Walter S, Behrens-Baumann W. Management of a ruptured globe. *Ophthalmologe [Article in German]* 2008;105:1163–75. [\[CrossRef\]](#)
6. Goweida MB, Helaly HA, Ghaith AA. Traumatic wound dehiscence.

- cence after keratoplasty: Characteristics, risk factors, and visual outcome. *J Ophthalmol* 2015;2015:631409. [\[CrossRef\]](#)
7. Fiorentzis M, Seitz B, Viestenz A. Traumatic keratoplasty rupture resulting from continuous positive airway pressure mask. *Cornea* 2015;34:717–9. [\[CrossRef\]](#)
  8. Inoue Y. Corneal triple procedure. *Semin Ophthalmol* 2001;16:113–8. [\[CrossRef\]](#)
  9. Oie Y, Nishida K. Triple procedure: Cataract extraction, intraocular lens implantation, and corneal graft. *Curr Opin Ophthalmol* 2017;28:63–6. [\[CrossRef\]](#)
  10. Gentile RC, Elliott D. Silicone oil retention sutures in aphakic eyes with iris loss. *Arch Ophthalmol* 2010;128:1596–9. [\[CrossRef\]](#)
  11. de Juan E Jr, McCuen B, Tiedeman J. Intraocular tamponade and surface tension. *Surv Ophthalmol* 1985;30:47–51. [\[CrossRef\]](#)