

CASE REPORT

Case Report: Ischemic Stroke As a Result of Aortic Dissection

Burcu Bayramoğlu, İsmail Tayfur, Ferah Kader, Dijan Tav, Gültekin Akyol

Department of Emergency Medicine, University of Health Sciences Türkiye, Sancaktepe Sehit Prof. Dr. İlhan Varank Training and Research Hospital, İstanbul, Türkiye

Abstract

Stroke is one of the leading causes of mortality and morbidity. Aortic dissection is a highly mortal medical condition without treatment as well. Aortic dissection can present with different clinical signs and symptoms, one of which is stroke. Treatments of ischemic stroke and aortic dissection are different from each other. Because of that, early diagnosis and treatment of ischemic stroke due to aortic dissection is important. In this case, we aimed to explain a young male patient with a large ischemic stroke as a result of painless dissection and thrombus of the carotid arteries and painless dissection of the ascending and descending aorta, arcus aorta, and iliac artery.

Keywords: Aortic dissection; carotid thrombosis; computed tomography angiography; ischemic stroke.

Acute aortic dissection is a life-threatening condition that requires urgent evaluation and treatment. Its incidence varies from 2.9-4.7 cases per 100,000 people annually^[1,2]. According to one of the latest studies, 17.6% of acute aortic dissection patients died before hospital arrival^[3]. Aortic dissection is painless in approximately 5-10% of patients^[4]. Most of those are with neurologic complications.

Case Report

A 47-year-old male with no known chronic disease was admitted to the emergency department (ED) suffering from loss of consciousness. The patient had a sudden-onset right-sided weakness. Since then, he was unresponsive.

On his physical examination, the Glasgow Coma Scale score was 3. His right eye deviated to the left side. His blood pressure (BP) was 125/58 mmHg and his heart rate

was 74 bpm. Peripheral oxygen saturation was 88%, and he had gasping respiration. A computed tomography (CT) scan of the brain and thorax was arranged. There was no intracranial bleeding. After that, diffusion magnetic resonance imaging (MRI) was performed, which disclosed acute cerebral infarction in the left cerebral hemisphere (Fig. 1).

Cranial and cervical computed tomography angiography (CTA) was performed, and we planned to refer the patient to a thrombectomy unit. We noticed that he had aortic dissection in the arcus aorta and right common carotid artery (CCA) and blockage of the left CCA and brachiocephalic trunk with thrombus. Then, thorax and abdominal CTA were performed and showed dissection starting from the aortic root to the iliac arteries, including the right iliac artery. There was no need for thrombectomy due to revascularization of the left CCA (Figs. 2, 3).

Correspondence: İsmail Tayfur, M.D. Department of Emergency Medicine, University of Health Sciences Türkiye, Sancaktepe Sehit Prof. Dr. İlhan Varank Training and Research Hospital, İstanbul, Türkiye

Phone: +90 532 711 87 56 **E-mail:** ismailtayfur@yahoo.com

Submitted Date: 09.12.2021 **Revised Date:** 18.04.2023 **Accepted Date:** 25.04.2023

Haydarpaşa Numune Medical Journal

OPEN ACCESS This is an open access article under the CC BY-NC license (<http://creativecommons.org/licenses/by-nc/4.0/>).



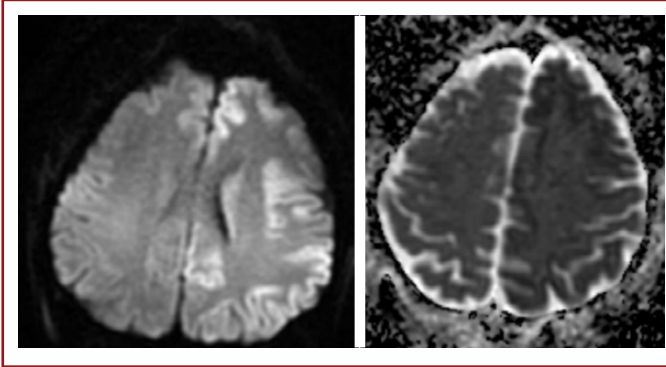


Figure 1. Acute cerebral infarction in the left cerebral hemisphere.

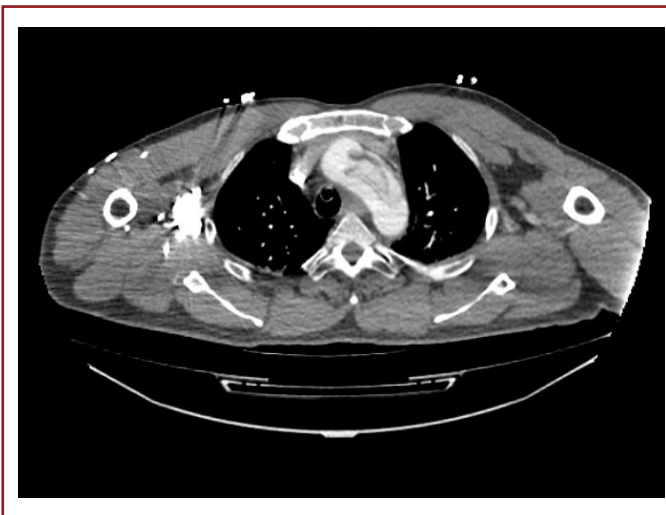

Figure 2. Dissection in arcus aorta.

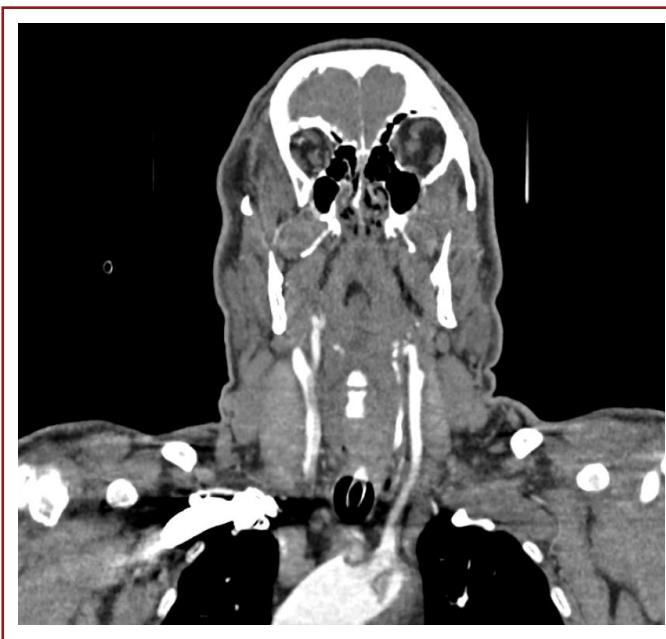

Figure 3. Dissection in the right common carotid artery (CCA) and blockage of the left CCA and brachiocephalic trunk with thrombus.

Because of the severe cerebral infarction and poor general condition, the cardiovascular surgeon recommended hospitalization in an intensive care unit (ICU) until his condition stabilized. He was treated conservatively in the ICU and died 2 days after the onset of illness.

Discussion

Characteristically, acute aortic dissection usually presents with sudden onset severe pain in the chest, abdomen, or back. However, as seen in our patient, aortic dissection can be painless in patients with neurological presentation^[5].

Nienaber et al.^[6] found that neurological symptoms in aortic dissection were more often in women than men. In another study, patients with painless dissection were older and the dissection was often in the ascending aorta. Diabetes, aortic aneurysm, and history of cardiac surgery were more common in this patient group^[7]. In our case, the patient was young and male. He had no known disease. The aortic dissection was in the ascending aorta, arcus aorta, descending aorta, carotid artery, and iliac artery.

Diagnosis of aortic dissection with complicated stroke is challenging. CT is the first step in the evaluation of stroke. For patients admitted to the hospital and candidates for endovascular treatment, CTA must be performed as it can be useful to evaluate the vertebral artery and extracranial artery. Ohara et al.^[8] mentioned five findings and diagnostic tests in stroke patients with aortic dissection in their study: elevated D-dimer value, abnormal carotid ultrasound, left hemiparesis as a neurological symptom, mediastinal widening on chest radiography, and systolic BP differential between the arms. Tokudo et al.^[9] reported intimal flaps with an unthrombosed false lumen, intimal flaps with a thrombosed false lumen, and various occlusion patterns in carotid ultrasonography in their study.

The main treatments for stroke are the administration of intravenous tissue plasminogen activators and thrombectomy^[10]. Ischemic stroke, a complication of aortic dissection, can be mortal due to delay in diagnosis. The mortality may be due to the administration of tPA therapy, which is contraindicated in aortic dissection, or the delay in surgery^[8]. The occlusion of the aortic arches or cervicocerebral arteries may occur depending on the development or extension of dissection and can be temporary. Because of that, neurological symptoms may disappear or vary^[11]. In our case, there was dissection in the right CCA and thrombus in the left CCA. The blockage of the left CCA recanalized without intervention. Because of that, thrombectomy wasn't appropriate for the case. tPA was not given to our patient because of the large ischemic

stroke and extensive aortic dissection.

Compared with the literature, our patient is different in these aspects: he was male, younger, had a painless dissection, and the dissection was in all aortic branches, carotid artery, and iliac artery.

Stroke and aortic dissection may present with similar clinical symptoms. It is important to distinguish these two diseases from each other. Both can be mortal, especially aortic dissection. Early diagnosis can be life-saving as well as preventing the patient's condition from worsening with the possible application of tPA. Early surgical treatment can save the patient's life. Carotid ultrasonography may be helpful for the diagnosis in the ED. Absent diffusion restriction in diffusion MRI and pulse and blood pressure differential between extremities may be a warning for both type A and B aortic dissections.

Informed Consent: Written informed consent was obtained from the patient for the publication of the case report and the accompanying images.

Peer-review: Externally peer-reviewed.

Conflict of Interest: None declared.

Authorship Contributions: Concept: İ.T.; Design: İ.T., B.B.; Supervision: İ.T.; Fundings: None; Materials: F.K., B.B.; Data Collection or Processing: İ.T., B.B., F.K., D.T., G.A.; Analysis or Interpretation: İ.T., B.B., F.K.; Literature Search: B.B., F.K., D.T., G.A.; Writing: İ.T., B.B., F.K., D.T., G.A.; Critical Review: İ.T.

Use of AI for Writing Assistance: Not declared.

Financial Disclosure: The authors declared that this study received no financial support.

References

1. Pacini D, Di Marco L, Fortuna D, Belotti LM, Gabbieri D, Zussa C, et al. Acute aortic dissection: epidemiology and outcomes. *Int J Cardiol* 2013;167:2806–12. [\[CrossRef\]](#)
2. Mészáros I, Mórocz J, Szlávi J, Schmidt J, Tornóci L, Nagy L, et al. Epidemiology and clinicopathology of aortic dissection. *Chest* 2000;117:1271–8. [\[CrossRef\]](#)
3. Melvinsdottir IH, Lund SH, Agnarsson BA, Sigvaldason K, Gudbjartsson T, Geirsson A. The incidence and mortality of acute thoracic aortic dissection: Results from a whole nation study. *Eur J Cardiothorac Surg* 2016;50:1111–7. [\[CrossRef\]](#)
4. Yanamadala A, Kumar S, Lichtenberg R. It is a medical emergency! Act fast: A case report of painless aortic dissection. *Eur Heart J Case Rep* 2019;3:ytz072. [\[CrossRef\]](#)
5. Gaul C, Dietrich W, Friedrich I, Sirch J, Erbguth FJ. Neurological symptoms in type A aortic dissections. *Stroke* 2007;38:292–7.
6. Nienaber CA, Fattori R, Mehta RH, Richartz BM, Evangelista A, Petzsch M, et al. Gender-related differences in acute aortic dissection. *Circulation* 2004;109:3014–21. [\[CrossRef\]](#)
7. Park SW, Hutchison S, Mehta RH, Isselbacher EM, Cooper JV, Fang J, et al. Association of painless acute aortic dissection with increased mortality. *Mayo Clin Proc* 2004;79:1252–7. [\[CrossRef\]](#)
8. Ohara T, Koga M, Tokuda N, Tanaka E, Yokoyama H, Minatoya K, et al. Rapid identification of type a aortic dissection as a cause of acute ischemic stroke. *J Stroke Cerebrovasc Dis* 2016;25:1901–6. [\[CrossRef\]](#)
9. Tokuda N, Koga M, Ohara T, Minatoya K, Tahara Y, Higashi M, et al. Urgent detection of acute type a aortic dissection in hyperacute ischemic stroke or transient ischemic attack. *J Stroke Cerebrovasc Dis* 2018;27:2112–7. [\[CrossRef\]](#)
10. Tekyol D, Altundağ İ, Efe Y, Kılıç M, Öncü T, Pul MF, et al. Investigation of an alternative education module in raising middle school student's awareness of acute stroke. *Clin Neurol Neurosurg* 2023;225:107565. [\[CrossRef\]](#)
11. Gaul C, Dietrich W, Erbguth FJ. Neurological symptoms in aortic dissection: A challenge for neurologists. *Cerebrovasc Dis* 2008;26:1–8. [\[CrossRef\]](#)